

Sporotrichosis: A Case Report and Literature Review

Motswaledi. H^{1*}, Nkosi. L¹, Moloabi. C¹, Ngobeni. K¹, Nemetavhanani. D² and Maloba. B²

¹Department of Dermatology, University of Limpopo (Medunsa Campus), South Africa

²Department of Microbiological Pathology, National Health Laboratory Services (NHLS)(Medunsa Campus), South Africa

Abstract

Background: Sporotrichosis is an acute or chronic cutaneous or systemic fungal infection caused by *sporothrix schenckii*. This is a dimorphic fungus which occurs in both temperate and tropical areas. It occurs sporadically in many countries but has been particularly common in the mining areas of South Africa. We report a case of fixed cutaneous form of sporotrichosis with no identifiable source of infection.

Methods: Several biopsy specimen were stained with hematoxylin and eosin, as well as PAS and PAS-D. Some specimen were cultured on Sabouraud's dextrose with chloramphenicol agar plate using aseptic technique as per standard operating procedure for processing mycology specimen at our institution. A lactophenol cotton blue preparation from the cultured material was also performed.

Results: Histopathology showed hyperkeratosis with crusting and a granulomatous inflammation with microabscesses containing budding yeasts and a rarely seen asteroid body (representing the Splendore-Hoeppli phenomenon). Growth on agar plates occurred after 7 days and showed a cream-white mould which later changed to brown-black colour. A lactophenol cotton blue preparation showed hyphae and conidia.

Conclusion: We report a case of fixed cutaneous sporotrichosis in a diabetic patient with no obvious source of infection identified. The rarely seen asteroid body was seen on histopathology and the fungus was successfully cultured.

Case Report

A 33 years old African male from urban Gauteng Province of South Africa presented with an asymptomatic growth at the back for 3 years. It started as a small papule which grew slowly. He was diagnosed type II diabetes mellitus a year ago and he is on metformin 500mg twice daily and glibenclamide 5mg orally daily. His father also has diabetes mellitus. He is employed as a security guard and has no history of working in mines nor in farms. There is no history of trauma prior to onset of this lesion.

On clinical examination he was found to be obese, weighing 103kg. All systems were normal, and he had no lymphadenopathy. He had a 5x4cm well circumscribed, dome shaped lesion at the back with a verrucous and crusted surface (Figure 1).

His chest x-ray was normal. A full blood count, urea and electrolytes as well as liver function tests were normal. Random serum glucose was 21.4mmol/L. He declined HIV testing.

An incisional biopsy from the lesion showed hyperkeratosis with crusting, and acanthosis. The dermis showed a mixed inflammatory infiltrate with granulomas and microabscesses. PAS stain revealed short non-branching fungal hyphae, budding yeasts as well as an asteroid body located in a microabscess (Figure 2).

Biopsy material cultured on Sabouraud dextrose agar with chloramphenicol incubated at 30°C showed growth after 7 days. Culture showed a cream-white mould which later changed to brown-black colour with a wrinkled surface (Figure 3). A lactophenol cotton blue preparation from the mould showed thin hyphae with conidia found singly and in clusters. There were also conidiophores arising at right angles to the hyphae, with groups of conidia that formed rosettes (Figure 4). Yeast form was isolated from biopsy material cultured on brain heart infusion agar and Sabouraud dextrose agar with chloramphenicol incubated at 37°C. A wet preparation of the colony showed yeast bodies of various sizes and shapes (Figure 5). Conversion of the mould to yeast phase was demonstrated by sub-culturing the mould onto brain heart infusion agar at 37°C.

Our final diagnosis was fixed cutaneous sporotrichosis. The patient was treated with itraconazole 200mg orally, twice daily, and was referred to Physicians for further management of diabetes mellitus.

Discussion

Sporotrichosis is a rare, acute or chronic fungal infection caused by the dimorphic fungus *sporothrix schenckii* [1]. This fungus grows in decaying vegetable matter like timber in mines, thorns, rose shrubs, soil, tree barks, and animal droppings [2]. It occurs sporadically in many countries but has been particularly common in mining areas of South Africa [1]. Infection usually results from percutaneous inoculation of infected wood splinters or thorns [3]. It usually occurs in people occasionally exposed to the organism like mine workers, farm workers, gardeners and florists [1].

Sporothrix infection may manifest in 4 ways: lymphocutaneous, fixed cutaneous, disseminated cutaneous and extracutaneous forms [4].

The extracutaneous sporotrichosis results from hematogenous spread from primary inoculation site or from inhalation of conidia, especially in immunocompromised hosts. It affects bones, joints, lungs and meninges [4].

***Corresponding author:** Motswaledi. H, P.O Box 1911, Medunsa, 0204, South Africa, Tel: +27 12 521 4001/+27 82 464 4703; Fax: + 27 12 521 3266; E-mail: motswaledi1@webmail.co.za

Received October 21, 2011; **Accepted** November 18, 2011; **Published** November 25, 2011

Citation: Motswaledi H, Nkosi L, Moloabi C, Ngobeni K, Nemetavhanani D, et al. (2011) Sporotrichosis: A Case Report and Literature Review. J Clin Exp Dermatol Res 2:132. doi:10.4172/2155-9554.1000132

Copyright: © 2011 Motswaledi H, et al. This is an open-access article distributed under the terms of the Creative Commons Attribution License, which permits unrestricted use, distribution, and reproduction in any medium, provided the original author and source are credited.

The disseminated cutaneous form is rare occurring in less than 2% of cases. It results from hematogenous dissemination from a primary site or from multiple inoculation sites [4].

The fixed cutaneous type is also less common and is characterized by localized lesions with no lymphatic involvement. Common sites are face, neck, trunk and legs [5]. Lesions may be a papule, nodule, plaque or tumour. Our patient presented with a tumour.

The lymphocutaneous type is the most classic form occurring in nearly 70% of cases of cutaneous sporotrichosis [6]. It starts as a small tender nodule at the inoculation site, that eventually ulcerates. Later nodulo-ulcerative lesions appear along the lymphatic channels forming the sporotrichoid pattern of spread [6]. Lymphadenitis and lymphadenopathy are characteristic.

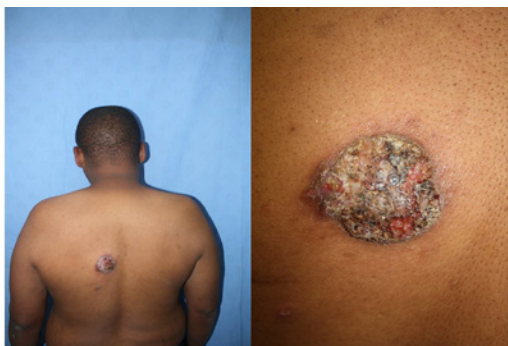

Figure 1: Dome shaped lesion with a verrucous, crusted surface.

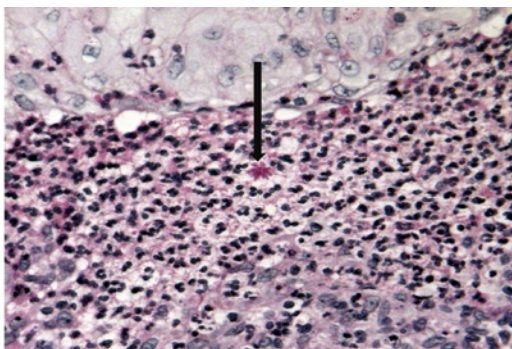


Figure 2: An asteroid body within a microabscess(original magnification X400).

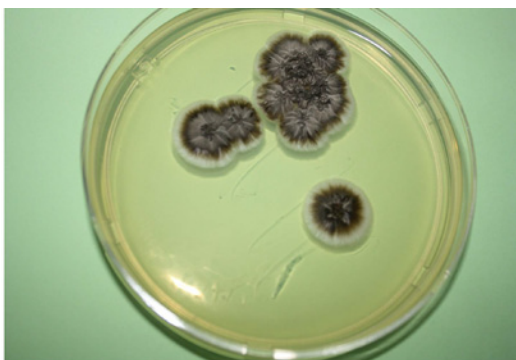

Figure 3: Mould with a dark-brown to black colour with a wrinkled surface.

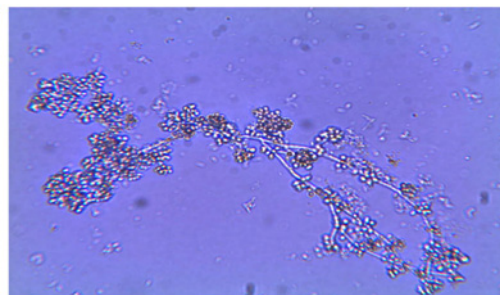


Figure 4: A lactophenol cotton blue preparation showing hyphae with conidia and conidiophores (original magnification X40).

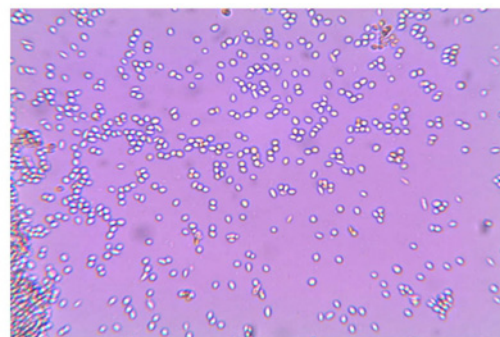


Figure 5: A wet preparation showing yeast bodies (original magnification X40).

Sporotrichosis occurs commonly in adults but rare childhood cases have been reported. A case of neonatal sporotrichosis where the source of infection remains unknown was reported recently [7].

Some unusual presentations of sporotrichosis have been reported. Ramli et al reported a case of sporotrichosis which presented like a soft tissue tumour [8]. Mahajan et al reported a case of sporotrichosis over a pre-existing facial nodulo-ulcerative basal cell carcinoma [9].

Due to the diverse nature of the clinical presentation of sporotrichosis, clinical diagnosis may be a challenge, however, the lymphocutaneous type with its classic sporotrichoid spread should be diagnosed readily.

Histopathology may show a pseudoepitheliomatous hyperplasia, with a granulomatous inflammation in the dermis with microabscesses. If spores are present, they appear as round to oval bodies 4 to 6µm, that stain with PAS-stain more strongly at the periphery than in the centre [10]. Single or occasionally multiple buds are seen. Sometimes “cigar-shaped” elongated yeasts are seen [11].

In exceptional cases “asteroid bodies” can be seen, representing the Splendore-Hoeppli phenomenon (antigen-antibody complexes and cell detritus of inflammatory cells) [12]. We need to emphasize that asteroid bodies are not pathognomonic of sporotrichosis as they may be seen in a number of other infectious processes, as well as in sarcoidosis.

Sporothrix schenckii is a dimorphic fungus which grows well on Sabouraud dextrose agar with antibiotics. The mould form is isolated at 25°C - 30°C over a few days or weeks. Colonies are finely wrinkled with a white-creamy colour at first but later become brown, dark

grey or nearly black [12,13]. A lactophenol cotton blue preparation shows thin hyaline hyphae with oval, pyriform conidia around the tips of conidiophores, forming rosettes and giving rise to a “palm tree appearance” [14]. The conidiophores typically arise at right angles from the sides of hyphae. The yeast form is produced by culturing the mould form onto enrichment agars such as brain heart infusion agar incubated at 37°C.

Treatment of sporotrichosis was recently reviewed by an expert panel from the Infectious Diseases Society of America.

For fixed cutaneous and lymphocutaneous sporotrichosis, itraconazole 200mg daily for 3-6 months is recommended [15-17]. Patients who do not respond should be given a higher dose of 200mg twice daily. Terbinafine administered at a daily dose of 250mg to 500mg is also effective for cutaneous sporotrichosis [16,18]. Potassium iodide is also widely used for treatment of cutaneous sporotrichosis especially in developing countries [19].

For osteo-articular sporotrichosis, itraconazole 200mg orally twice daily for at least 12 months is recommended [16].

In severe pulmonary sporotrichosis amphotericin B given as a lipid formulation at 3-5mg/kg daily is recommended [16].

For patients with meningeal sporotrichosis amphotericin B 5mg/kg daily for 4 to 6 weeks is recommended. After the patient responds to initial treatment with amphotericin B, itraconazole can be given as step-down therapy for at least 12 months [16]. Amphotericin B is also a treatment of choice for patients with disseminated systemic sporotrichosis [16].

In pregnant women imidazoles should be avoided, so treatment of choice for sporotrichosis in pregnant women is amphotericin B. Local hyperthermia can also be used for mild localized sporotrichosis in pregnant women [16].

For children with disseminated sporotrichosis amphotericin B 0.7mg/kg should be the initial therapy, followed by itraconazole 6-10mg/kg to a maximum of 400mg orally daily as step-down therapy [16].

Spontaneous resolution of localized cutaneous sporotrichosis without lymphatic involvement has been reported in few cases [20,21].

Acknowledgements

The authors thank Professor EJ Raubenheimer for performing the histopathological examination in this case.

References

1. Hay RJ and Moore M (1998) Mycology. In: Champion RH, Burton JL, Burns DA and Breathnach SM, eds, Rook/Wilkinson/Ebling Textbook of Dermatology, (6th edn), Blackwell Science, London: 1277-1376.
2. Zhang YQ, Xu XG, Zhang M, Jiang P, Zhou XY, et al. (2011) Sporotrichosis: Clinical and Histopathological Manifestations. Am J Dermatopathol 33: 296-302.
3. Weedon D. Mycoses and algal infections. In: *Weedon's skin pathology*. 3rd edn, 2010, Churchill Livingstone, China: 582-606.
4. Yang DJ, Krishnan RS, Guillen DR, Schmiede LM 3rd, Leis PF, et al. (2006) Disseminated sporotrichosis mimicking sarcoidosis. Int J Dermatol 45: 450-453.
5. Morris-Jones R (2002) Sporotrichosis. Clin Exp Dermatol 27: 427-431.
6. Sharma NL, Mahajan VK, Verma N, Thakur S (2003) Cutaneous sporotrichosis: an unusual clinico-pathologic and therapeutic presentation. Mycoses 46: 515-518.

7. Tlougan BE, Podjasek JO, Patel SP, Nguyen XH, Hansen RC (2009) Neonatal sporotrichosis. Paediatr Dermatol 26: 563-565.
8. Ramli R, Abd Rashid AH, Phang KS, Khaithir TM (2009) Sporotrichosis atypical presentation as a soft tissue tumour. Malaysian J Pathol 31(2): 143-145.
9. Mahajan VK, Sharma NL, Shanker V, Gupta P, Mardi K (2010) Cutaneous sporotrichosis: Unusual clinical presentations. Ind J Dermatol Venereol Leprol 76: 276-279.
10. Longley BJ. Fungal Diseases. In: Elder D, Elenitsas R, Jaworsky C and Johnson Jr B, eds, *Lever's Histopathology of the skin*, 8th edn, 1997. Lippincott-Raven, New York: 517-551.
11. Bonifaz A, Peniche A, Mercadillo P, Saúl A (2001) Successful Treatment of AIDS-Related Disseminated cutaneous sporotrichosis with Itraconazole. AIDS PATIENT CARE AND STD's; 15: 603-606.
12. Bonifaz A, Vázquez-González D, Perusquia-Ortiz AM (2010) Subcutaneous mycoses: chromoblastomycosis, sporotrichosis and mycetoma. J Dtsch Dermatol Ges 8: 619-628.
13. Kwon-Chung KJ, Bennett JE (1992) Sporotrichosis. In: Medical Mycology: Lea & Febiger; London : 707-729.
14. Yegneswaran PP, Sripathi H, Bairy I, Lonikar V, Rao R (2009) Zoonotic sporotrichosis of lymphocutaneous type in a man acquired from a domesticated feline source: report of a first case in Southern Karnataka, India. Int J Dermatol 4: 1198-1200.
15. Fujii H, Tanioka M, Yonezawa M, Arakawa A, Matsumura Y, et al. (2007) A case of a typical sporotrichosis with multifocal cutaneous ulcers. Clin Exp Dermatol 33: 135-138.
16. Kauffman CA, Bustamante B, Chapman SW, Pappas PG (2007) Clinical Practice Guidelines for the management of sporotrichosis: 2007 update by the Infectious Diseases Society of America. Clin Infect Dis 45: 1255-1265.
17. de Lima Barros MB, Schubach AO, de Vasconcellos Carvalhaes de Oliveira R, Martins EB, Teixeira JL, et al. (2011) Treatment of cutaneous sporotrichosis with itraconazole - study of 645 patients. Clin Infect Dis; 52: 200-206.
18. Francesconi G, Francesconi do Valle AC, Passos SL, de Lima Barros MB, de Almeida Paes R, et al. (2011) Comparative study of 250mg/day Terbinafine and 100mg/day Itraconazole for the Treatment of Cutaneous Sporotrichosis. Mycopathologia 171: 349-354.
19. Xue S, Gu R, Wu T, Zhang M, Wang X, et al. (2009) Oral potassium iodide for the treatment of sporotrichosis. Cochrane Database Syst Rev 4: 1-4.
20. Almeida HL Jr, Lettnin CB, Barbosa JL, Dias MC (2009) Spontaneous Resolution of Zoonotic Sporotrichosis during Pregnancy. Rev Inst Med trop S. Paulo 51: 237-238.
21. Bargman H (1983) Sporotrichosis of the skin with spontaneous cure - report of a second case. J Am Acad Dermatol 8: 261-262.