

## Skin Effects of Dioxins

Qiang Ju<sup>1\*</sup> and Christos Zouboulis<sup>2</sup>

<sup>1</sup>Department of Dermatology, Renji Hospital, Shanghai Jiaotong University, Shanghai, PR China

<sup>2</sup>Departments of Dermatology, Venereology, Allergy and Immunology, Dessau Medical Center, Dessau, Germany

### Abstract

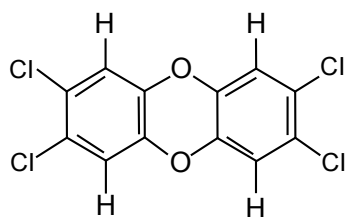
Dioxins is a compound family among persistent organic pollutants toxics produced by industrial wastes. 2,3,7,8-Tetrachlorodibenzo-p-dioxin (TCDD) is a typical representative of dioxins, which not only exhibits systemic carcinogenicity, teratogenicity, immunotoxicity, hepatotoxicity, endocrine disruption and waste syndrome to humans, but also has effects on physiology and pathology of human skin. In general, chloracne is the most sensitive and specific marker for a possible dioxin intoxication. Clinically chloracne is an acneiform dermatosis, characterized by an eruption of multiple comedone-like cysts involving the face and as well as other areas. Atrophy or absence of sebaceous glands and infundibular dilatation or cystic formation of hair follicles could be detected histopathologically. In addition, erythema, oedema, decreased sebum secretion with skin xerosis, pigmentation, porphyriopathy, hirsutism, skin thickening, palmoplantar hyperhidrosis and palmoplantar hyperkeratosis of sweat gland origin have also been reported after TCDD intoxication. TCDD exhibits various effects on cellular differentiation, inducing melanogenesis and complicated actions on skin inflammation and immunity. The aryl hydrocarbon receptor signaling pathway and epidermal stem cells may be involved in TCDD activity. No effective treatment of TCDD exists.

**Keywords:** 2,3,7,8- Tetrachlorodibenzo-p-dioxin; Dioxins; Skin; Aryl hydrocarbon receptor; Chloracne; Persistent organic pollutants

### Introduction

Persistent toxic substances include the Stockholm persistent organic pollutants (POPs), such as dichlorodiphenyltrichloroethane, polychlorinated biphenyls, dioxin/furan and organometallic compounds, such as organomercury, organotin, and organolead, which all share the same characteristics of being persistent, toxic, bioaccumulative, and able to travel long distances through different media. Dioxins are representative toxic agents among various POPs [1].

Dioxins are not a single substance but a large family of halogenated aromatic hydrocarbons, which consist of tricyclic aromatic compounds. Hydrogen atoms can be substituted by up to eight chlorines, thus leading to the development of about 75 isomers. 2,3,7,8- Tetrachlorodibenzo-p-dioxin (TCDD) with four chlorine atoms in lateral positions is the most biologically active isomer and is also the most toxic substance known as a representative of dioxins [2] (Figure 1). Dioxins are derived as the unexpected by-products of many industrial processes and can accumulate in soil, sediments and also food chains with long half-life of several years, which has potentially major effects on human health, such as carcinogenicity, teratogenicity, immunotoxicity, hepatotoxicity, endocrine disruption and waste syndrome [2,3]. The skin is the largest organ in the human body and one of its main functions is to protect



2,3,7,8-TCDD

**Figure 1:** Chemical structure of 2,3,7,8-tetrachlorodibenzo-p-dioxin (TCDD).

the body from noxious substances. Environmental pollutants, such as TCDD, have profound effects on normal skin physiology and pathology, and are related to various skin diseases [4]. In this review, we will focus on the effect of TCDD on human skin.

### TCDD Induced Skin Lesions

Normally chloracne with acneiform skin lesions is the first manifestation after systemic intoxication with TCDD [5]. Chloracne was firstly described by von Bettman in 1897 and the term was proposed by Herxheimer in 1899 [6]. Most cases of chloracne have resulted from occupational and non-occupational exposures. Non-occupational chloracne mainly result from contaminated industrial wastes such as the Seveso accident in Italy [7], and TCDD intoxication of Viktor Andriyovych Yushchenko, a former president of Ukraine [8]. Clinically chloracne is characterized by non-inflammatory lesions, such as pseudo-comedones, nodules and comedone-like cysts. Disseminated lesions mostly involve face, chest and back but can also appear on the neck, trunk, extremities, genitals, axillary and other skin areas with a higher serum concentration of TCDD [5]. The histopathology of chloracne is characterized mainly by hyperplasia of epidermis, diminish and absence of sebaceous glands. Although the skin lesions are historically summarized under the term “chloracne”, they rather represent a functional hamartomatous adaptive process to this poison exposure [9]. Therefore Saurat and Sorg [10] proposed to name TCDD-induced skin lesions “metabolizing acquired dioxin-induced skin hamartomas”. The pathogenesis of chloracne is still unclear: It may be

**\*Corresponding author:** Qiang Ju, Department of Dermatology, Renji Hospital, Shanghai Jiaotong University, 1630 Dongfang Road, Shanghai, 200127, PR China, Tel: 86-21-63846590 EXT: 776261; E-mail: [qiangju401@sina.com](mailto:qiangju401@sina.com)

**Received** July 20, 2013; **Accepted** August 29, 2013; **Published** September 5, 2013

**Citation:** Ju Q, Zouboulis C (2013) Effects of 2,3,7,8- Tetrachlorodibenzo-p-dioxin on the Skin. Biosafety 2:113. doi:10.4172/2167-0331.1000113

**Copyright:** © 2013 Ju Q, et al. This is an open-access article distributed under the terms of the Creative Commons Attribution License, which permits unrestricted use, distribution, and reproduction in any medium, provided the original author and source are credited.

related to the imbalance of epidermal progenitor cells, since chloracne appears to be resistant to all tested forms of treatment. The only way to control chloracne is to prevent exposure to chloracnogens [5,11].

In addition to the classical lesions mentioned above, exposure to TCDD can lead to acute facial erythema, occasionally associated with oedema in the beginning of TCDD intoxication, decreased sebum secretion and skin xerosis, pigmentation, porphyrinopathy, hirsutism, skin thickening, palmoplantar hyperhidrosis and palmoplantar hyperkeratosis of sweat gland origin [12-14], which indicates that several skin tissues and cells are involved. Since chloracne is not only a skin disease but a systemic intoxication, sometimes accompanied by systemic symptoms, such as fatigue, anorexia, neuropathy, impotence, liver dysfunction, hyperlipemia, anaemia, arthritis, thyromegaly and ophthalmitis [1].

### Effects of TCDD on Keratinocytes

Hyperplasia of epidermal cells is always observed in chloracne and TCDD intoxication. Topical application of TCDD in adult hairless mice resulted in hyperkeratinization and induction of dermal cysts, whereas inter-follicular epidermis was not affected [15]. Exposure of murine fetuses in utero to TCDD led to an accelerated terminal differentiation of fetal skin [16]. A survey of 23 cell lines displayed no changes in morphology, viability or growth patterns following treatment with TCDD [17]. Furthermore, TCDD caused acceleration of differentiation of a spontaneously immortalized human keratinocyte cell line in a three-dimensional skin equivalent model as determined by morphological characterization and by immune histochemistry with several differentiation-specific proteins. Neither an influence on proliferation nor an induction of apoptosis was observed [18]. However, TCDD was found to impair differentiation of normal human epidermal keratinocytes in a skin equivalent model [19]. A recent in vitro study using normal human epidermal keratinocytes showed a TCDD-mediated acceleration of differentiation and enhanced expression of several pro-differentiation genes, including filaggrin and small proline rich protein 2 [20]. These results indicated that the epidermal permeability barrier is also affected. Another study found increased ceramides, decreased expression of the glucose transporter SLC2A1 and most of the glycolytic transcripts, followed by decreases in glycolytic intermediates, which means that TCDD-mediated ROS production is a critical step in the mechanism of this chemical to accelerate keratinocyte differentiation [21]. In primary cultured keratinocytes, TCDD inhibited culture-induced senescence: The inhibition of senescence by TCDD could be an important mechanism by which it may exert its tumor promoting effects in the skin [22].

### Effects of TCDD on Sebaceous Gland Cells and Sweet Gland Cells

Clarifying the effects of dioxins on sebaceous glands are especially important, since the differentiation of sebocytes is severely affected following dioxin exposure in vivo and markedly reduced sebum levels with skin xerosis is an important clinical feature of TCDD intoxication. TCDD exhibits an inhibitory effect on lipid metabolism in laboratory rodents and humans and induces clinically a wasting syndrome [23]. The use of animal models such as that of the rabbit ear [24], meibomian glands of primates [25], and hairless mice has shown that miniaturization of sebaceous glands is noted following TCDD exposure [17]. The 5-year follow up of Victor Yushchenko, who had been exposed to TCDD, has shown a complete and sustained involution of sebaceous glands in skin lesions [9]. In cultured SZ95 sebocytes

and in human skin maintained ex vivo TCDD was found to decrease lipogenesis and affect differentiation of human sebaceous gland cells by switching the sebaceous into a keratinocyte-like differentiation [26]. In addition, eccrine gland is also involved after exposure to TCDD. In a patient with chloracne, acral granuloma annulare-like lesions and squamous syringometaplasia of the eccrine glands was observed in the immediate vicinity of affected skin [14].

### Effects of TCDD on Melanocytes

Although hyperpigmentation is noted in chloracne and TCDD intoxication, there is still no knowledge on the pathway of TCDD induction of melanogenesis and hyperpigmentation. A study showed that exposure of normal human melanocytes to TCDD results in activation of the aryl hydrocarbon receptor (AhR) signaling pathway and an AhR-dependent activation of tyrosinase activity, the key enzyme of melanogenesis. In accordance with the upregulation of tyrosinase activity, total melanin content was also elevated in TCDD-exposed melanocytes, a proof of TCDD-modulated melanogenesis by controlling the expression of melanogenic genes [27].

### Effect of TCDD on Skin Immunity and Inflammation

An earlier study showed that long-term exposure to TCDD is associated with depressed cell-mediated immunity [28]. This finding obtained after longer exposure to TCDD could lead to non-inflammatory acne-like lesions, but could not explain erythema and edema induced in acute intoxication. In TCDD-treated mice, a significant decrease in tensile strength and increased population of macrophages within the wounded tissue were observed during wound healing, which indicates a pro-inflammatory TCDD effect on the wounded tissue and disruption of normal healing [29]. Been activated by TCDD, AhR induces a long-lasting effect on the human adaptive immune system and specifically polarizes CD4+ T cells to produce IL-22 but no other T cell cytokines, since it is ineffective on T regulatory cells [30]. A recent study showed that TCDD exposure exacerbates atopic dermatitis-associated inflammation with no increase of IgE antibody production [31].

### Molecular Mechanisms of TCDD on the Skin

The exact molecular mechanism of TCDD on human skin is still unclear. In order to explain the pathogenesis of chloracne, Panteleyev and Bickers [5] hypothesized that chloracnogene-induced transformation of the pilosebaceous unit is driven by activation and accelerated exit of cells from the stem cell compartment coupled with a shift from a pilosebaceous differentiation pattern to an epidermal one. This may result in imbalance in early multipotent cells commitment and their preferential differentiation along an epidermal lineage with consequent diminution of sebaceous gland and lower hair follicle portion along with prominent epidermal/infundibular hyperplasia and hyperkeratinization.

Most of the effects of TCDD in humans and animals were mediated by the AhR signaling pathway, after binding and activation to AhR. AhR is a member of the basic-helix-loop-helix period-ARNT-single-minded family of dimeric transcription factors [32]. It is expressed and activated in human keratinocytes and skin fibroblasts as well as in human sebaceous glands and human immortalized SZ95 sebocytes [4,26,33]. AhR is involved in normal skin formation during fetal development as well as in pathological states, such as epidermal wound healing and skin carcinogenesis [34], and may be essential in stem/progenitor cell homeostasis [35]. TCDD-induced acceleration of keratinocyte differentiation [20], abnormal sebaceous gland

differentiation [26], and melanogenesis [27] are mediated by AhR. Downstream molecular targets of AhR are versatile, including influence of classical xenobiotic metabolizing enzymes (such as CYP1A1), interleukin-1 $\beta$ , tumor growth factors, c-Myc, epidermal growth factor receptors, and B lymphocyte maturation protein 1 (Blimp1). TCDD/AhR/ARNT/Blimp1 and CYP1A1/c-Myc pathways may very likely be the effective signaling pathways for TCDD on skin physiology and skin diseases [36].

## Perspective

Present studies have shown that persistent toxic substances, such as dioxins, have profound effects on human skin physiology and pathology, which can become a major health issue under the rapid development of modern industry. The interaction of TCDD and skin is extremely complicated. Many skin tissues and cells are affected by TCDD, which induces the appearance of various skin lesions. The AhR signal pathway in the skin may be the link between TCDD and skin manifestations. A better understanding of AhR function in the skin will provide new knowledge and understanding to the skin biology and pathology in the future.

## References

- Wong MH, Armour MA, Naidu R, Man M (2012) Persistent toxic substances: sources, fates and effects. *Rev Environ Health* 27: 207-213.
- Pelclová D, Urban P, Preiss J, Lukás E, Fenclová Z, et al. (2006) Adverse health effects in humans exposed to 2,3,7,8-tetrachlorodibenzo-p-dioxin (TCDD). *Rev Environ Health* 21: 119-138.
- English JS, Dawe RS, Ferguson J (2003) Environmental effects and skin disease. *Br Med Bull* 68: 29-142.
- Bock K W, Köhle C (2009) The mammalian aryl hydrocarbon (Ah) receptor: from mediator of dioxin toxicity toward physiological functions in skin and liver. *Biol Chem* 390: 1225-1235.
- Panteleyev AA, Bickers DR (2006) Dioxin-induced chloracne--reconstructing the cellular and molecular mechanisms of a classic environmental disease. *Exp Dermatol* 15: 705-730.
- Herxheimer K (1899) Über chloracne. *Münch Med Wochenschr* 46: 278.
- Pesatori AC, Consonni D, Bachetti S, Zocchetti C, Bonzini M, et al. (2003) Short- and long-term morbidity and mortality in the population exposed to dioxin after the "Seveso accident". *Ind Health* 41: 127-138.
- Sorg O, Zennegg M, Schmid P, Fedosyuk R, Valikhnovskiy R, et al. (2009) 2,3,7,8-tetrachlorodibenzo-p-dioxin (TCDD) poisoning in Victor Yushchenko: identification and measurement of TCDD metabolites. *Lancet* 374: 1179-1185.
- Saurat JH, Kaya G, Saxer-Sekulic N, Pardo B, Becker M, et al. (2012) The cutaneous lesions of dioxin exposure: lessons from the poisoning of Victor Yushchenko. *Toxicol Sci* 125: 310-317.
- Saurat JH, Sorg O (2010) Chloracne, a misnomer and its implications. *Dermatology* 221: 23-26.
- Ju Q, Zouboulis CC, Xia L (2009) Environmental pollution and acne: Chloracne. *Dermatoendocrinol* 1: 125-128.
- Zugerman C (1990) Chloracne. Clinical manifestations and etiology. *Dermatol Clin* 8: 209-213.
- Jensen NE (1970) Chloracne: three cases. *Proc R Soc Med* 65: 687-688.
- Geusau A, Jurecka W, Nahavandi H, Schmidt JB, Stingl G, et al. (2000) Punctate keratoderma-like lesions on the palms and soles in a patient with chloracne: a new clinical manifestation of dioxin intoxication? *Br J Dermatol* 143: 1067-1071.
- Panteleyev AA, Thiel R, Wanner R, Zhang J, Roumak VS, et al. (1997) 2,3,7,8-Tetrachlorodibenzo-p-dioxin (TCDD) affects keratin 1 and keratin 17 gene expression and differentially induces keratinization in hairless mouse skin. *J Invest Dermatol* 108: 330-335.
- Loertscher JA, Lin TM, Peterson RE, Allen-Hoffmann BL (2002) In utero exposure to 2,3,7,8-tetrachlorodibenzo-p-dioxin causes accelerated terminal differentiation in fetal mouse skin. *Toxicol Sci* 68: 465-472.
- Knutson JC, Poland A (1980) 2,3,7,8-Tetrachlorodibenzo-p-dioxin: Failure to demonstrate toxicity in twenty-three cultured cell types. *Toxicol Appl Pharmacol* 54: 377-383.
- Loertscher JA, Sadek CS, Allen-Hoffmann BL (2001) Treatment of normal human keratinocytes with 2,3,7,8-tetrachlorodibenzo-p-dioxin causes a reduction in cell number, but no increase in apoptosis. *Toxicol Appl Pharmacol* 175: 114-120.
- Geusau A, Khorchide M, Mildner M, Pammer J, Eckhart L, et al. (2005) 2,3,7,8-Tetrachlorodibenzo-p-Dioxin Impairs Differentiation of normal human epidermal keratinocytes in a skin equivalent model. *J Invest Dermatol* 124: 275-277.
- Sutter CH, Bodreddigari S, Campion C, Wible RS, Sutter TR (2011) 2,3,7,8-Tetrachlorodibenzo-p-dioxin increases the expression of genes in the human epidermal differentiation complex and accelerates epidermal barrier formation. *Toxicol Sci* 124: 128-137.
- Kennedy LH, Sutter CH, Leon Carrion S, Tran QT, Bodreddigari S, et al. (2013) 2,3,7,8-Tetrachlorodibenzo-p-dioxin-mediated production of reactive oxygen species is an essential step in the mechanism of action to accelerate human keratinocyte differentiation. *Toxicol Sci* 132: 235-249.
- Ray S, Swanson HI (2009) Activation of the aryl hydrocarbon receptor by TCDD inhibits senescence: a tumor promoting event? *Biochem Pharmacol* 77: 681-688.
- Schiller CM, Adcock CM, Moore RA, Walden R (1985) Effect of 2,3,7,8-tetrachlorodibenzo-p-dioxin (TCDD) and fasting on body weight and lipid parameters in rats. *Toxicol Appl Pharmacol* 81: 356-361.
- Hambrick GW, Blank H (1956) A microanatomical study of the response of the pilosebaceous apparatus of the rabbit's ear canal. *J Invest Dermatol* 26: 185-200.
- Brewster DW, Elwell MR, Birnbaum LS (1988) Toxicity and disposition of 2,3,4,7,8-pentachlorodibenzofuran (4PeCDF) in the rhesus monkey (*Macaca mulatta*). *Toxicol Appl Pharmacol* 93: 231-246.
- Ju Q, Fimmel S, Hinz N, Stahlmann R, Xia L, et al. (2011) 2,3,7,8-Tetrachlorodibenzo-p-dioxin alters sebaceous gland differentiation characteristics in vitro. *Exp Dermatol* 20: 320-325.
- Luecke S, Backlund M, Jux B, Esser C, Krutmann J, et al. (2010) The arylhydrocarbonreceptor (AHR), a novel regulator of human melanogenesis. *Pigment Cell Melanoma Res* 23: 828-833.
- Shireman RB, Wei CI (1986) Uptake of 2,3,7,8-tetrachlorodibenzo-p-dioxin from plasma lipoproteins by cultured human fibroblasts. *Chem Biol Interact* 58: 1-12.
- Bremilla NC, Ramirez JM, Chicheportiche R, Sorg O, Saurat JH, et al. (2011) In vivo dioxin favors interleukin-22 production by human CD4+ T cells in an aryl hydrocarbon receptor (AhR)-dependent manner. *PLoS One* 6: e18741.
- Akintobi AM, Villano CM, White LA (2007) 2,3,7,8-Tetrachlorodibenzo-p-dioxin (TCDD) exposure of normal human dermal fibroblasts results in AhR-dependent and -independent changes in gene expression. *Toxicol Appl Pharmacol* 220: 9-17.
- Ito T, Inouye K, Nohara K, Tohyama C, Fujimaki H (2008) TCDD exposure exacerbates atopic dermatitis-related inflammation in NC/Nga mice. *Toxicol Lett* 177: 31-37.
- Schmidt JV, Bradfield CA (1996) Ah receptor signaling pathways. *Annu Rev Cell Dev Biol* 12: 55-89.
- Ikuta T, Ohba M, Zouboulis CC, Fujii-Kuriyama Y, Kawajiri K (2010) B lymphocyte-induced maturation protein 1 is a novel target gene of aryl hydrocarbon receptor. *J Dermatol Sci* 58: 211-216.
- Ikuta T, Namiki T, Fujii-Kuriyama Y, Kawajiri K (2009) AhR protein trafficking and function in the skin. *Biochem Pharmacol* 77: 588-596.
- Bock KW (2013) The human Ah receptor: hints from dioxin toxicities to deregulated target genes and physiological functions. *Biol Chem* 394: 729-739.
- Ju Q, Yang K, Zouboulis CC, Ring J, Chen W (2012) Chloracne: from clinic to research. *Dermatol Sinica* 30: 2-6.