

Seasonal Flu as a Triggering Factor for Acquired Thrombotic Thrombocytopenic Purpura

Adrien Joseph, Pascal Fangio, Christophe Barbier, Jan Hayon, Yann Loubières, Claire Pichereau, Hervé Outin and Mikael Alves*

Service of Medico-Surgical Intensive Care, Inter Communal Poissy Hospital, Poissy, France

*Corresponding author: Mikael Alves, Service of Medico-Surgical Intensive Care, Inter Communal Poissy Hospital, Saint-Germain-en-Laye, 10 rue du Champ Gaillard, 78300 Poissy, France, Tel: 33139275203; Fax: 33139274440; E-mail: mikaelalves@gmail.com

Rec date: March 31, 2016; Acc date: May 11, 2016; Pub date: May 18, 2016

Copyright: © 2016 Joseph A, et al. This is an open-access article distributed under the terms of the Creative Commons Attribution License, which permits unrestricted use, distribution, and reproduction in any medium, provided the original author and source are credited.

Abstract

A 47 years old woman was admitted to our intensive care unit for acute asthma. An infection by influenza virus A was diagnosed and the patient presented during her hospitalization signs of thrombotic microangiopathy. Biologic analysis showed low A Desintegrin and Metalloproteinase with Thrombospondin 1 - motifs - member 13 (ADAMTS13) activity and positive anti-A Desintegrin And Metalloproteinase with Thrombospondin 1 - motifs - member 13 antibodies. Diagnosis of Acquired Thrombotic Thrombocytopenic Purpura was considered and a specific treatment was started with plasma exchange and intravenous administration of rituximab for relapse. Acquired Thrombotic Thrombocytopenic Purpura is considered an auto-immune disease. As such, it can be triggered by bacterial or viral infection. Many triggering factors have been described. Testing for influenza virus should be considered in epidemic situations when a Thrombotic Thrombocytopenic Purpura is diagnosed.

Keywords: TTP; TMA; ADAMTS13; Influenza

Abbreviations

ATTP: Acquired Thrombotic Thrombocytopenic Purpura; **TMA:** Thrombotic MicroAngiopathies; **ADAMTS13:** A Desintegrin and Metalloproteinase with Thrombospondin 1 - motifs - member 13; **TTP:** Thrombotic Thrombocytopenic Purpura; **LDH:** Lactic Dehydrogenase; **HIV:** Human Immunodeficiency Virus; **DNA:** Deoxyribonucleic Acid

Introduction

Acquired Thrombotic Thrombocytopenic Purpura (aTTP) belongs to thrombotic microangiopathies (TMA). It is caused by antibodies aimed at A Desintegrin and Metalloproteinase with Thrombospondin 1 - motifs - member 13 (ADAMTS13), a metalloprotease designed to shorten von Willebrand factor multimers, which accumulation leads to enhanced platelets aggregability. Clinical symptoms of Thrombotic Thrombocytopenic Purpura (TTP) consists of a pentad: mechanical hemolytic anemia, thrombopenia, neurologic impairment, renal failure and fever.

Case presentation

A 47 year's old Turkish patient was referred to the emergency department for bronchospastic respiratory failure. She was only treated with salbutamol for asthma since childhood and was not vaccinated against influenza virus. She was admitted to intensive care unit and an infection by influenza virus was rapidly diagnosed using immunochromatography on rhino pharyngeal secretions.

On admission, her blood pressure was normal, she presented a tachycardia (110 beats/min) and tachypnea (40 breaths/min). Examination revealed bilateral diffuse wheezing and clinical signs of respiratory distress.

Initial laboratory test results were: hemoglobin level, 15 g/dL; platelet count, $57 \times 10^3/\text{mm}^3$; blood urea nitrogen and serum creatinine level, 15.6 mmol/L and 65 $\mu\text{mol/L}$, total protein, 5.7 g/dL; albumin, 3.7 g/dL; LDH, 200 UI/L, $\text{PaO}_2 = 52$ mmHg, $\text{PaCO}_2 = 28$ mm Hg; pH = 7.43, bicarbonates = 22 mmol/L. Chest radiography was normal. Treatment was initiated with high-flow oxygen, aerosols of β_2 -agonist, systemic corticosteroids (prednisone 1 mg/kg/day) and oseltamivir (150 mg/kg/day for 5 days). She did not require mechanical ventilation.

On the 6th day, a post-influenza bacterial pneumonia was diagnosed and intravenous antibiotherapy with cefotaxime and linezolid was started. Moderate ultrasensible troponin elevation (199 ng/mL, cut-off value 50 ng/ml) was noted, without electrocardiographic modification. Echocardiography revealed global hypokinetic left ventricle with ejection fraction measured at 40%.

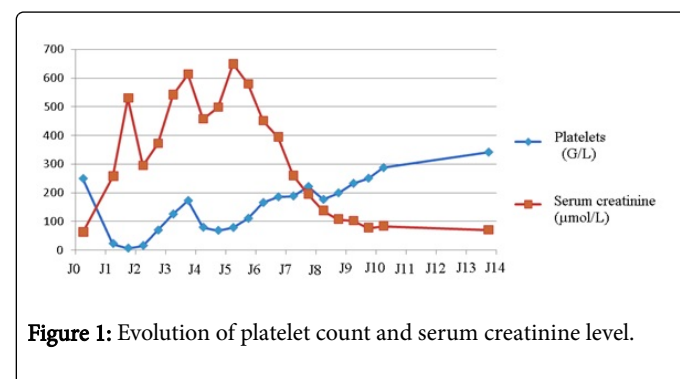


Figure 1: Evolution of platelet count and serum creatinine level.

A diagnosis of TMA was promptly made based on the occurrence of acute renal failure and deep thrombopenia on the next day (Figure 1). Her ADAMTS13 activity was depressed (<5%) with positive anti-ADAMTS13 dosage (70 UI/L). Alternative complement pathway was normal. Antinuclear and antiphospholipid antibodies were absent, and HIV status was negative.

The patient required twelve plasma exchanges, progressively spaced after normalization of platelet counts (>150 G/L) for two successive days. Furthermore, she received intermittent renal replacement therapy with hemodialysis for 6 days and four red cells units were transfused. Despite thrombocytopenia as low as 6 G/L, she was not supplied with platelet units and did not suffer from hemorrhagic complication. Early relapse after withdrawal of corticosteroid therapy administered for asthma (diminution of platelet count and rise of LDH) required administration of rituximab and reintroduction of corticosteroids. Sixteen days after her admission, renal function fully recovered and TMA's signs totally disappeared, enabling her transfer out of the intensive care unit.

Discussion

Acquired TTP is considered an autoimmune disease [1] and can be triggered by bacterial [2] or viral [3] infections, stress, pancreatitis [4] or an immune stimulation such as vaccination [5].

To our knowledge, only 2 cases of aTTP triggered by influenza infection were reported. The first case was described by Wasserstein in 1981. Diagnosis was made retrospectively based on chronic glomerulonephritis, sudden onset aphasia and hemolytic anemia following infection by the influenza virus [6]. The second reported case was a 67 years old Japanese patient presenting both intravascular disseminated coagulation and fatal TMA with ADAMTS13 deficiency, following recent seasonal flu diagnosis [7].

Correlation between infection and acquired TTP and the pathophysiology of anti-ADAMTS13 antibodies production is not completely understood. Given the diversity of triggering factors, molecular mimicry is unlikely to play a role. The hypothesis can be made that DNA-histone complexes and myeloperoxidase produced by polynuclear neutrophils lead to endothelial activation which exposes ADAMTS13 antigen and enhances autoantibody production in predisposed patients. This was shown in a study by Fuchs [8], in which the rise in DNA-histone complexes and myeloperoxidase correlated with disease activity in TTP patients.

Plasmapheresis was used in this case to remove anti-ADAMTS13 antibodies and provide fresh ADAMTS13 proteins. Introduction of rituximab is based on recent studies demonstrating its efficacy in cases of relapse [9].

This case shows the importance of viral triggering factors. Testing for influenza virus should be considered in epidemic situations when aTTP is diagnosed.

References

1. George JN, Nester CM (2014) Syndromes of thrombotic microangiopathy. *N Engl J Med* 371: 1847-1848.
2. Douglas KW, Pollock KG, Young D, Catlow J, Green R (2010) Infection frequently triggers thrombotic microangiopathy in patients with preexisting risk factors: a single-institution experience. *J Clin Apher* 25: 47-53.
3. Lopes da Silva R (2011) Viral-associated thrombotic microangiopathies. *Hematol Oncol Stem Cell Ther* 4: 51-59.
4. McDonald V, Laffan M, Benjamin S, Bevan D, Machin S, et al. (2009) Thrombotic thrombocytopenic purpura precipitated by acute pancreatitis: a report of seven cases from a regional UK TTP registry. *Br J Haematol* 144: 430-433.
5. Brown RC, Blecher TE, French EA, Toghiani PJ (1973) Thrombotic thrombocytopenic purpura after influenza vaccination. *Br Med J* 2: 303.
6. Wasserstein A, Hill G, Goldfarb S, Goldberg M (1981) Recurrent thrombotic thrombocytopenic purpura after viral infection. Clinical and histologic simulation of chronic glomerulonephritis. *Arch Intern Med* 141: 685-687.
7. Kosugi N, Tsurutani Y, Isonishi A, Hori Y, Matsumoto M, et al. (2010) Influenza A infection triggers thrombotic thrombocytopenic purpura by producing the anti-ADAMTS13 IgG inhibitor. *Internal medicine* 49: 689-693.
8. Fuchs TA, Kremer HJA, Schatzberg D, Wagner DD, Lammle B (2012) Circulating DNA and myeloperoxidase indicate disease activity in patients with thrombotic microangiopathies. *Blood* 120: 1157-1164.
9. Scully M, McDonald V, Cavenagh J, Hunt BJ, Longair I, et al. (2011) A phase 2 study of the safety and efficacy of rituximab with plasma exchange in acute acquired thrombotic thrombocytopenic purpura. *Blood* 118: 1746-1753.