

# Schlemm's Canal in OCT Images in Glaucoma Patients and Healthy Subjects

Viera Forgáčová<sup>1</sup>, Jan Lešták<sup>1,2,3\*</sup>, Šárka Pitrová<sup>1</sup> and Pavel Rozsival<sup>3</sup>

<sup>1</sup>JL Clinic, V Hůrkách 1296/10, Prague, Czech Republic

<sup>2</sup>Czech Technical University in Prague (Faculty of Biomedical Engineering), Czech Republic

<sup>3</sup>Charles University (Faculty of Medicine in Hradec Králové), Czech Republic

## Abstract

**Objective:** To determine by means of optical coherence tomography (OCT) whether there are changes in Schlemm's canal (SC) in primary open-angle glaucoma (POAG) compared to healthy controls and whether the SC dimension varies during the treatment facilitating the outflow of intraocular humor through the uveoscleral pathway.

**Patients and methods of examination:** 62 eyes of 31 POAG patients (22 women aged 27-83 and 9 men aged 26-80) were included in our set. The patients did not suffer from any other disease of the anterior segment of the eye. Intraocular pressure (IOP) was compensated by drug treatment and its values were in the range of 10-20 mmHg. The group was compared with 92 eyes of 46 healthy subjects (33 women aged 19-71 and 13 men aged 39-79). The SC of all of them was examined by anterior segment OCT-system with a Visante OCT Carl Zeiss Meditec Inc. in horizontal meridian No. 3 and 9.

**Results:** The comparisons show that the values of right and left eyes of controls ( $p=0.474$ ) and patients ( $p=0.143$ ) did not differ. The re-external ( $p=0.00029$ ), le-external ( $p=0.0031$ ), re-internal ( $p=0.0015$ ), le-internal ( $p=0.0002$ ) SC dimensions between the control and patient groups differed significantly with the controls always having values significantly higher than the glaucoma patients. Treatment by prostaglandins and beta-blockers did not affect the size of the SC ( $p=0.23$  to  $0.95$ ).

**Conclusion:** In POAG eyes, SC size is smaller than in the eyes of the control group. Eyes on prostaglandin treatment had the same size than those on beta blockers.

**Keywords:** Schlemm's canal; POAG; OCT

## Introduction

The major drainage structures of aqueous humor are the conventional or trabecular out flow pathways, which are comprised of the trabecular mesh work, the juxtacanalicular connective tissue, the endothelial lining of Schlemm's canal, the collecting channels and the aqueous veins [1].

In this study, we tried to find, by means of optical coherence tomography (OCT), whether there were changes in Schlemm's canal (SC) in primary open-angle glaucoma (POAG) compared to healthy controls and whether the dimensions of the SC varies during the treatment facilitating the outflow of intraocular humor through the uveoscleral pathway.

## Patients and Methods

62 eyes of 31 POAG patients (22 women aged 27-83 and 9 men aged 26-80. Mean age - 58) were included in our set. The patients did not suffer from any other disease of the anterior segment of the eye. Intraocular pressure (IOP) was compensated by drug treatment, and its values were in the range of 10-20 mmHg. The group was compared with 92 eyes of 46 healthy subjects (33 women aged 19-71 and 13 men aged 39-79. Mean age -53). The SC of all the eyes were examined using the anterior segment OCT-system with a Visante OCT Carl Zeiss Meditec Inc. (Time-domain AS OCT) in the horizontal meridian at No. 3 and 9.

Consequently, SC size is marked on the right eye as re-internal or re-external and similarly, the left eye as le-external or le-internal (Tables 1 and 2). To avoid data distortion, all the tests and measurements were performed by only one physician. SC was measured in its longer dimension (Figure 1). For evaluation of the right and left eyes of the controls, and following that of the patients, the paired t-test was always

used. For comparison of the parameters of the SC size between controls and patients in the study group, the two-sample t-test was used. To assess the prostaglandins and beta-blockers influence on SC size, the non-parametric two-option Mann-Whitney's test was used.

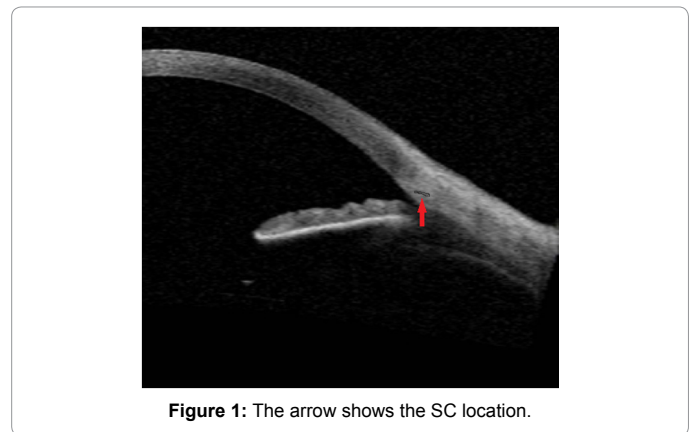


Figure 1: The arrow shows the SC location.

**\*Corresponding author:** Jan Lestak, JL Clinic, V Hůrkách 1296/10, Prague, Czech Republic, E-mail: [lestak@seznam.cz](mailto:lestak@seznam.cz)

Received July 01, 2013; Accepted August 28, 2013; Published August 31, 2013

**Citation:** Forgáčová V, Lešták J, Pitrová J, Rozsival P (2013) Schlemm's Canal in OCT Images in Glaucoma Patients and Healthy Subjects. J Clin Exp Ophthalmol 4: 292. doi:10.4172/2155-9570.1000292

**Copyright:** © 2013 Forgáčová V, et al. This is an open-access article distributed under the terms of the Creative Commons Attribution License, which permits unrestricted use, distribution, and reproduction in any medium, provided the original author and source are credited.

## Results

Measured values of SC size of the right and left eyes, namely at points of intersection of horizontal meridian at No. 3 and 9, are shown in Tables 1 and 2. Statistical values are then introduced in Figures 2-5.

For comparison of the right and left eyes both in controls and patients with glaucoma, the paired t-test was used. When comparing the SC between the right and left eye, always on the same side, we did not find a statistically significant difference in control eyes (re-external and le-external,  $p=0.383$ , re-internal and le-internal,  $p=0.474$ ).

We arrived at a similar conclusion even in glaucoma eyes (re-external and le-external,  $p=0.143$ , re-internal and le-internal,  $p=0.104$ ).

We also compared SC size on the same eye in the control eyes (re-external and re-internal,  $p=0.912$ , le-external and le-internal,  $p=0.533$ ). We did not find statistically significant difference in SC size in the same eye.

We have arrived at a similar conclusion even in glaucoma left eyes (le-external and le-internal,  $p=0.45$ ). Paradoxically, we have found a statistically significant difference in the right eye re-external and re-internal,  $p=0.00009$ .

Gender/ Year of birth	re-external diameter	re-internal diameter	le-external diameter	le-internal diameter	re-IOP	le-IOP
F/1959	0.35	NM	0.4	0.39	14	14
F/1969	0.39	0.41	NM	0.43	18	15
F/1986	0.38	0.4	NM	0.39	11	12
F/1989	0.39	0.39	0.38	0.39	10	10
F/1942	0.35	0.33	0.35	0.28	16	16
F/1940	0.39	0.33	0.39	0.41	15	15
F/1975	0.3	0.29	0.32	0.34	13	15
F/1965	NM	0.4	0.38	0.4	15	16
F/1951	0.39	NM	0.41	0.41	14	14
F/1985	0.39	0.38	NM	0.41	14	15
F/1961	0.39	0.39	0.42	0.39	12	12
F/1994	0.4	0.41	0.41	0.42	14	15
F/1948	0.41	0.4	0.39	0.38	17	17
F/1943	0.4	0.41	0.4	0.38	12	13
F/1964	0.38	0.28	0.23	0.27	18	18
F/1959	0.38	NM	0.37	NM	10	11
F/1959	0.38	0.39	0.4	0.41	14	14
F/1954	0.4	0.38	NM	0.4	14	14
F/1984	0.4	0.4	NM	NM	17	17
F/1975	0.41	0.38	NM	NM	18	18
F/1952	0.39	NM	0.39	0.38	14	19
F/1953	0.42	0.39	0.42	0.39	20	20
F/1950	0.42	NM	0.39	0.39	16	17
F/1953	0.42	NM	0.42	0.42	15	16
F/1943	NM	0.41	NM	0.41	17	15
F/1945	0.42	0.41	0.4	0.37	18	17
F/1983	NM	NM	0.4	0.37	17	18
F/1943	0.32	0.25	0.28	0.27	18	18
F/1958	0.41	0.39	0.39	NM	16	15
F/1956	NM	NM	0.4	0.39	10	11
F/1945	0.38	NM	0.4	0.39	13	12
F/1989	0.41	0.41	0.4	0.42	10	11
F/1982	0.39	NM	0.41	0.39	14	15
M/1954	0.37	0.38	0.38	0.41	15	14
M/1964	0.39	0.44	0.39	0.44	12	15
M/1972	0.3	0.32	0.25	0.3	12	11
M/1943	0.4	0.4	NM	NM	15	14
M/1935	0.4	0.34	0.4	0.33	12	13
M/1974	0.39	0.41	NM	0.41	19	19
M/1957	NM	NM	0.39	0.39	19	18
M/1934	0.42	0.43	0.39	NM	18	17
M/1950	0.42	0.42	NM	0.42	14	13
M/1952	0.43	NM	0.41	0.4	14	14
M/1965	0.39	0.41	0.41	NM	18	17
M/1957	NM	NM	0.38	0.39	20	20
M/1955	0.39	NM	0.41	0.39	13	15

Table 1: SC values in the control group.

Gender/ Year of birth	re-external diameter	re-internal diameter	le-external diameter	le-internal diameter	re-IOP	le-IOP	Therapy
F/1970	0.36	0.37	0.38	0.37	19	19	latanoprost
F/1975	0.3	NM	0.35	0.32	16	15	timolol
F/1932	0.3	NM	0.32	0.33	11	12	latanoprost
F/1962	0.29	0.33	0.28	0.3	14	14	latanoprost
F/1944	0.37	NM	0.35	0.35	19	20	latanoprost
F/1935	0.37	0.39	0.38	NM	14	10	timolol
F/1942	0.33	0.35	NM	NM	20	20	latanoprost
F/1959	NM	NM	0.36	0.38	18	18	latanoprost
F/1946	0.33	0.35	NM	NM	18	18	latanoprost
F/1948	NM	0.33	NM	0.32	12	12	timolol
F/1930	0.37	0.37	NM	NM	13	15	timolol
F/1950	NM	0.34	NM	0.33	13	13	timolol
F/1937	0.34	NM	0.32	NM	13	13	latanoprost
F/1964	0.27	0.3	0.3	0.27	17	16	latanoprost
F/1986	0.2	0.25	NM	NM	16	16	timolol
F/1930	0.33	0.36	0.34	0.37	14	14	latanoprost
F/1930	0.37	0.37	0.38	NM	20	20	latanoprost
F/1951	0.39	NM	0.36	NM	18	18	latanoprost
F/1933	NM	0.37	0.37	0.38	11	12	timolol
F/1946	NM	0.36	0.38	0.32	15	16	latanoprost
F/1965	NM	0.37	0.35	0.37	17	16	latanoprost
F/1984	0.33	0.36	NM	0.27	12	15	latanoprost
M/1933	0.29	0.31	0.28	0.32	18	16	latanoprost
M/1959	0.29	0.31	0.3	NM	14	14	latanoprost
M/1987	NM	0.35	NM	0.35	20	20	latanoprost
M/1978	0.34	0.39	0.36	0.38	20	20	latanoprost
M/1963	0.35	NM	0.37	0.38	14	15	latanoprost
M/1953	NM	NM	0.34	0.36	17	17	latanoprost
M/1974	0.36	NM	0.38	0.39	18	17	timolol
M/1982	NM	0.3	NM	0.31	17	18	latanoprost
M/1960	0.37	0.37	NM	NM	17	17	latanoprost

Table 2: SC values in glaucoma eyes.

A more important finding was the comparison of glaucoma eyes with those of the control group. In all eyes, there was a statistically significant difference with the control group having SC of greater dimension. The summary data are shown in Table 3. Here the values of SC in both measured areas in both the control and glaucoma groups are given. Importantly, we found no statistically significant difference in IOP between control and glaucoma eyes. This means that in our sample, the IOP does not affect SC size.

## Discussion

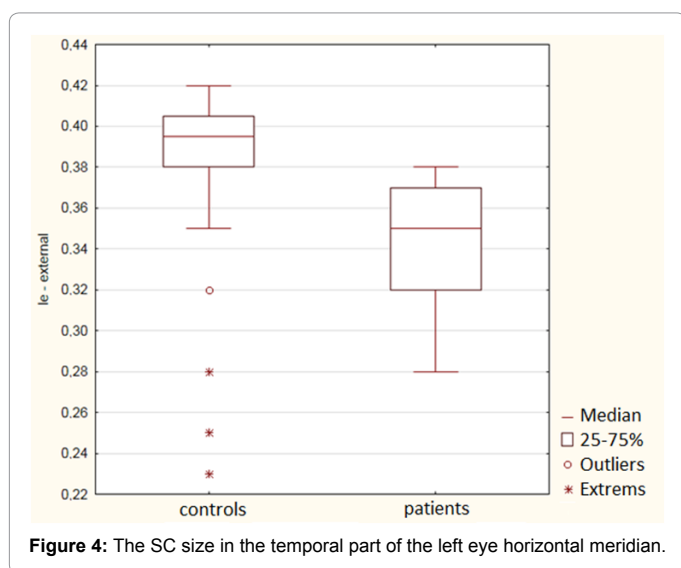
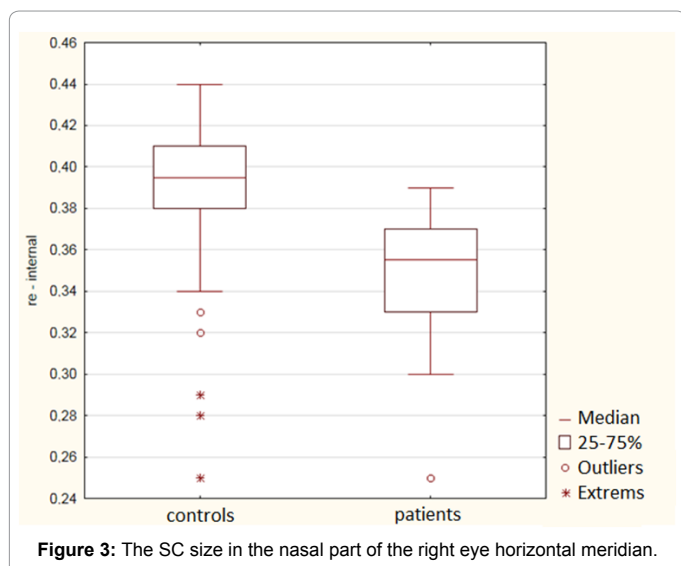
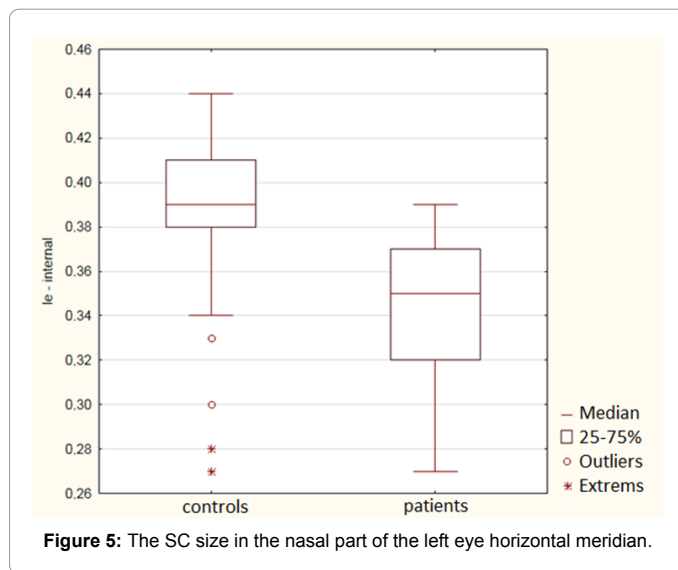
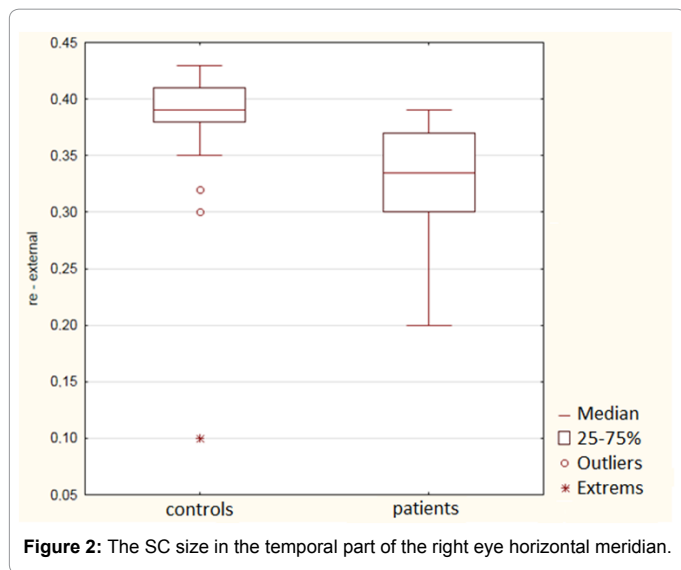
Until OCT tools were introduced, SC dimension was known only from histological findings. The average width of Schlemm's canal, determined by histological sections, is  $387.5 \pm 7.7 \mu\text{m}$  [2]. SC sizes in histological preparations were also investigated by Allingham et al. [3]. They showed that glaucomatous eyes had significantly smaller SC compared with a control group of healthy eyes. This reduction in SC dimension may account for approximately half of the decrease in outflow facility observed in POAG eyes.

SC dimension was investigated by ultrasound (80-MHz and Ultrasound probe) at the 12 o'clock position by Irshad et al. [4]. The average canal diameter was  $121 \mu\text{m}$  ( $\pm 45 \mu\text{m}$ ). The canal diameter in hyperopes was larger than canal diameter in myopes ( $180 \pm 69 \mu\text{m}$  vs.  $122 \pm 45 \mu\text{m}$ ;  $P < 0.001$ ). SC diameter was smaller in patients with previous glaucoma surgery compared with patients without surgery ( $98 \pm 4 \mu\text{m}$ ;  $P < 0.01$ ).

Kagemann et al. [5] investigated SC using Spectral-domain OCT and found that, in glaucoma patients, SC was smaller than in the controls. They also found that SC was significantly larger on the nasal side than on the temporal one. Our results are in agreement with the above mentioned studies. We have only not proven the difference in the size of the SC in the nasal versus temporal part. Similarly, Usui et al. [6] did not find a difference in the nasal in comparison with the temporal SC part as well.

We investigated the SC using Time-Domain AS OCT. Our results of a smaller SC in glaucoma eyes are in accordance with the above cited studies. Nevertheless, it was not possible to investigate the SC in every individual. The answer to that failure can be found in the article of Geering et al. [7]. The authors detailed the evaluation of angle structures, including SC and trabecular meshwork and explained the difficulties with the AS-TD-OCT. Detection of SC seemed to be beyond the limits of current technology. Even in histology, this structure is often difficult to see because of the variable of the slit-like and often septate canal, which measures between 200 and 400  $\mu\text{m}$  in the meridional axis but only 10 to 25  $\mu\text{m}$  in the opposite axis approaching the lateral and axial resolution of our OCT system.

We were also interested in possible changes of SC dimensions in the course of different anti-glaucoma treatments. We were inspired by the publication of Chen et al. [8] who found that the application of travoprost to healthy subjects brings about the expansion of SC. In our study with glaucoma patients, we noted no difference in SC size when they were treated with beta-blockers and prostaglandins.



	Controls	Glaucoma	P
re-external	0.38175	0.32955	0.000293
re-internal	0.38062	0.34545	0.003102
le-external	0.38222	0.34524	0.001587
le-internal	0.38385	0.34143	0.000222
re-IOP	14.8913	15.933	0.117715
le-IOP	15.108	19.000	0.102253

**Table 3:** The average SC sizes (in millimeters) in the eyes of the control group and in those of glaucoma patients.

### Conclusion

In POAG eyes, SC size is smaller than in the eyes of the control group. Eyes on prostaglandin treatment had the same size than those on beta blockers.

### References

- Grant WM (1951) Clinical measurements of aqueous outflow. Am J Ophthalmol 34: 1603-1605.
- Nesterov AP, Bunin AJa, Kacnelson LA (1974) Intraocular Pressure: Physiology and Pathology. Mir Publishers Moscow, pp: 381.
- Allingham RR, de Kater AW, Ethier CR (1996) Schlemm's canal and primary open Angle glaucoma: correlation between Schlemm's canal dimensions and outflow facility. Exp Eye Res 62: 101-109.
- Irshad FA, Mayfield MS, Zurakowski D, Ayyala RS (2010) Variation in Schlemm's canal diameter and location by ultrasound biomicroscopy. Ophthalmology 117: 916-920.
- Kagemann L, Wollstein G, Ishikawa H, Bilonick RA, Brennen PM, et al. (2010) Identification and assessment of Schlemm's canal by spectral-domain optical coherence tomography. Invest Ophthalmol Vis Sci 51: 4054-4059.
- Usui T, Tomidokoro A, Mishima K, Matakai N, Mayama C, et al. (2011) Identification of Schlemm's canal and its surrounding tissues by anterior segment fourier domain optical coherence tomography. Invest Ophthalmol Vis Sci 52: 6934-6939.
- Geerling G, Müller M, Winter C, Hoerauf H, Oelckers S, et al. (2005) Intraoperative 2-dimensional optical coherence tomography as a new tool for anterior segment surgery. Arch Ophthalmol 123: 253-257.
- Chen J, Huang H, Zhang S, Chen X, Sun X (2013) Expansion of Schlemm's canal by travoprost in healthy subjects determined by Fourier-domain optical coherence tomography. Invest Ophthalmol Vis Sci 54: 1127-34.