

## Ruxolitinib Chronic Myelomonocytic Leukemia-Associated Myelofibrosis: A Case Report

Guillermo J. Ruiz-Argüelles<sup>1,3\*</sup>, Guillermo J. Ruiz-Delgado<sup>1,3</sup>, Evelyn Galo-Hooker<sup>1</sup> and Sergio Sanchez-Sosa<sup>4</sup>

<sup>1</sup>Centro de Hematología y Medicina Interna, Clínica RUIZ, Puebla, México, USA

<sup>2</sup>Laboratorios Clínicos de Puebla, Clínica RUIZ, Puebla, México, USA

<sup>3</sup>Universidad Popular Autónoma del Estado de Puebla, USA

<sup>4</sup>Hospital Angeles de Puebla, Puebla, México, USA

### Introduction

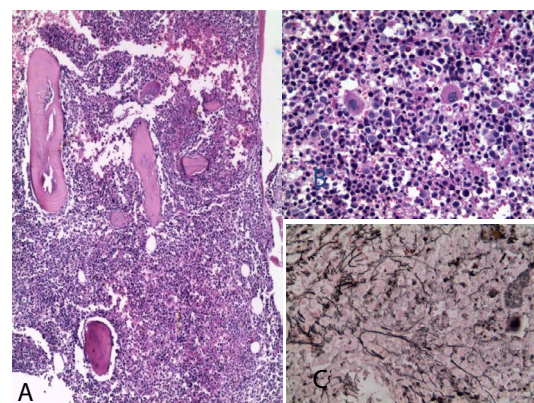
Myelodysplastic syndromes (MDS) are a heterogeneous group of clonal stem cell disorders which generally occur in older adults but may also affect children. Primary MDS should be distinguished from secondary MDS associated with antineoplastic or immunosuppressive therapy (t-MDS), exposure to toxic compounds, or genetic disorders [1]. Chronic myelomonocytic leukemia (CMML) has been considered a variant of MDS [1] and fibrotic forms have been observed in up to 16% of cases [2]. Accordingly, the histologic evaluation of a trephine bone marrow biopsy is of critical importance for the evaluation of fibrotic or hypocellular MDS since these patterns are not reflected by the cytological examination.

On the other hand, BCR-ABL negative myeloproliferative neoplasms (MPN's) include essential thrombocythemia (ET), polycythemia vera (PV) and primary myelofibrosis (MF), the latter notable for harboring the greatest morbidity and mortality amongst the subclass. The biological underscoring of these clonal hemopathies has historically stifled meaningful advances in gene-targeted therapies and compromised inhibition of the pro-inflammatory cytokines foundational to symptom development. The discovery of the Janus kinase 2 (JAK2) gain-of-function mutation, JAK2V617F, in 50-60% of patients with MF has led to the development of JAK2 inhibitors to treat the disease. This past decade has since been marked by the rapid development of JAK2 inhibitor therapies capable of reducing splenomegaly, cytopenias and constitutional symptoms with minimal myelosuppression and secondary toxicities. The recent Food and Drug Administration (FDA) approval in 2011 of the first JAK2 inhibitor, ruxolitinib, has heralded a new era for treatment of MF [3]. Ruxolitinib improves substantially the constitutional symptoms of the disease and decreases the splenomegaly [3]. Despite the fact that ruxolitinib is useful to control the constitutional symptoms of MF patients irrespective of the presence of the JAK2 V617F mutation, there is no information concerning the role of ruxolitinib in the treatment of secondary forms of MF.

We present here the case of a patient with CMML-associated MF who was treated with ruxolitinib, the constitutional symptoms improving and the splenomegaly decreasing. To the best of our knowledge, this is the first case which demonstrate the usefulness of ruxolitinib in secondary forms of MF.

### Case Report

In January 2012, this 54-year old lady was studied because of fatigue, pancytopenia, weight loss, constitutional symptoms and splenomegaly. She is a Mexican mestizo housewife measuring 1.66 meters, weighing 80 Kg. with a body mass index of 29.0. Her personal history was unremarkable and she denied the use of both alcohol and recreational drugs. She has a well-balanced diet. With the diagnosis of CMML, she was treated initially with danazol and prednisone. The bone marrow biopsy disclosed grade 2 myelofibrosis (Figure 1) and the bone marrow



**Figure 1:** A. Hypercellular bone marrow biopsy with a few fat cells 200X, H&E. B. Megakaryocytes are overtly abundant, some with nonlobulated nuclei, irregular and hyperchromatic. Granulocytes are also increased. 400 X, H&E. C. The Wylder stain shows abundance of fibrils. Grade 2 fibrosis, 400X.

aspirate showed: 17% nucleated red blood cells, 36% early granulocytes, 23% adult granulocytes, 16% lymphocytes and 8% blast cells which were found to be myeloblasts according to the cell surface expression of CD2, CD7, CD33, CD34, CD45, CD117, HLA-DR and MPO. Using the polymerase chain reaction in the bone marrow nucleated cells, BCR/ABL, JAK2 V617F, KIT D816V, MPL W515 L/K and inv 3 were negative. Since the constitutional symptoms were marked, she was given ruxolitinib 30 mg/day (15 mg bid). Ruxolitinib did not stop the leukocytosis from worsening despite the fact that it resulted in a decrease of the spleen size two weeks later and in diminishing the constitutional symptoms. The tip of the spleen was found 16 cm. below the costal margin when the ruxolitinib was started and 8 cm. below two weeks later. On the other hand, the WBC count continued to rise to  $102 \times 10^9/L$  while both the hemoglobin levels and the platelet count dropped. The flow-cytometric analysis of the mononuclear cells in the peripheral blood disclosed that they were normal granulocytes and monocytes; there were no blast cells. At this point the patient was

**\*Corresponding author:** Guillermo J Ruiz-Argüelles, Clínica Ruiz, Centro de Hematología y Medicina Interna, 8B Sur 3710, 72530, Puebla, Mexico, USA, E-mail: [gruiz1@clinicaruiz.com](mailto:gruiz1@clinicaruiz.com)

**Received** January 07, 2013; **Accepted** March 25, 2013; **Published** March 27, 2013

**Citation:** Ruiz-Argüelles GJ, Ruiz-Delgado GJ, Galo-Hooker E, Sanchez-Sosa S (2013) Ruxolitinib Chronic Myelomonocytic Leukemia-Associated Myelofibrosis: A Case Report. J Bone Marrow Res 1: 109. doi:10.4172/2329-8820.1000109

**Copyright:** © 2013 Ruiz-Argüelles GJ, et al. This is an open-access article distributed under the terms of the Creative Commons Attribution License, which permits unrestricted use, distribution, and reproduction in any medium, provided the original author and source are credited.

given dexamethasone, vincristine and adriamycin which resulted in a substantial decrease of the WBC count and in the disappearance of the bone pain. The dose of ruxolitinib was decreased to 10 mg/day (5 mg bid) and later on, withdrawn when the platelet count fell below  $20 \times 10^9/L$ . Four weeks later subcutaneous nodules appeared, its histologic examination revealing that they were granulocytic sarcomas. The patient is being treated with hidroxiurea and prednisone.

## Discussion

There is not enough information about the use of ruxolitinib in secondary forms of MF. Being a JAK2 inhibitor, ruxolitinib, heralding a new era for treatment of MF, has been shown to be useful in MF cases without JAK2V617F tyrosine kinase mutation [1,3-4]. Ruxolitinib has been shown to be of significant clinical benefit particularly in terms of regression of the splenomegaly of patients with intermediate or high-risk myelofibrosis, including primary myelofibrosis, post-polycythemia vera myelofibrosis and post-essential thrombocythemia myelofibrosis [5]. Since the presence of MF in a bone marrow biopsy can be primary or secondary, the demonstration of the JAK2V617F tyrosine kinase mutation supports the diagnosis of a myeloproliferative neoplasia [6], however, in MF without the molecular marker, the diagnosis relies in the study of the bone marrow biopsy, as in this case. The evolution of the hematological condition of this particular patient supports the possibility of the MF being secondary to the CMML and interestingly, the JAK2 inhibitor produced both amelioration of the constitutional

symptoms and regression of the splenomegaly. Since ruxolitinib is being used currently in some places on a compassionate basis, it is possible that other cases of secondary forms of MF are being treated with ruxolitinib. Prospective studies are needed to define the role of ruxolitinib in secondary forms of myelofibrosis.

## Acknowledgements

The authors are most grateful to Novartis-México, for supplying for free the ruxolitinib used to treat this patient. The comments of Drs. Rubén A MESA and José ATHIE are also acknowledged.

## References

1. Ruiz-Argüelles GJ (2009) Hipoplasias y displasias medulares. In Ruiz-Argüelles GJ, editor. Fundamentos de Hematología. 4th ed. Editorial Médica Panamericana. México City 117-127
2. Schmitt-Graeff A, Mattern D, Köhler H, Hezel J, Lübbert M (2000) [Myelodysplastic syndromes (MDS). Aspects of hematopathologic diagnosis]. Pathologie 21: 1-15.
3. Mesa RA (2013) The evolving treatment paradigm in myelofibrosis. Leuk Lymphoma 54: 242-251.
4. Komrokji RS, Verstovsek S, Padron E, List AF (2012) Advances in the management of myelofibrosis. Cancer Control 19: 4-15.
5. Randhawa J, Ostojic A, Vrhovac R, Atallah E, Verstovsek S (2012) Splenomegaly in myelofibrosis--new options for therapy and the therapeutic potential of Janus kinase 2 inhibitors. J Hematol Oncol 5: 43.
6. Ruiz-Argüelles GJ, Garcés-Eisele J, Reyes-Núñez V, Ruiz-Delgado GJ, Navarro-Vázquez M, et al. (2006) The Janus Kinase 2 (JAK2) V617F mutation in hematological malignancies in México. Rev Invest Clin 58: 458-461.