

Case Report

Open Access

Right Ventricular Mass: Intracardiac Ectopic Thyroid

Lu X, Liu Y, Liu L and Cao D*

Department of Radiology, The First Hospital of Jilin University, Chang Chun, China

*Corresponding author: Cao D, Department of Radiology, The First Hospital of Jilin University, XinMinZhu Street 71, Changchun, China, Tel: 15804300125; E-mail: caotianbo@126.com

Received date: February 13, 2017; Accepted date: February 20, 2017; Published date: February 27, 2017

Copyright: © 2017 Lu X, et al. This is an open-access article distributed under the terms of the Creative Commons Attribution License, which permits unrestricted use, distribution, and reproduction in any medium, provided the original author and source are credited.

Abstract

A 53-year-old woman complained of intermittent angina pectoris for 2 years and was admitted to our hospital to further evaluate cardiac mass. Electrocardiograph(ECG) showed sinus rhythm with incomplete right bundle branch block. Because a primitive cardiac tumor was highly suspected, exploratory surgery was performed. Intraoperative inspection revealed a red mass with a broad base arising from the middle-upper part of the interventricular septum close to the septal leaflet of the tricuspid valve.

Keywords: Intracardiac ectopic thyroid; Angiography; Malignant tumors; Thyroid scintigraphy

Case Report

A 53-year-old woman complained of intermittent angina pectoris for 2 years and was admitted to our hospital to further evaluate cardiac mass. Physical examination was unremarkable. Results of routine laboratory tests including thyroid function (FT3 5.32 pmol/L, FT4 21.07 pmol/L, TSH 4.1 uIU/ml) were all normal. Chest plain film showed a normal size heart (Figure 1).

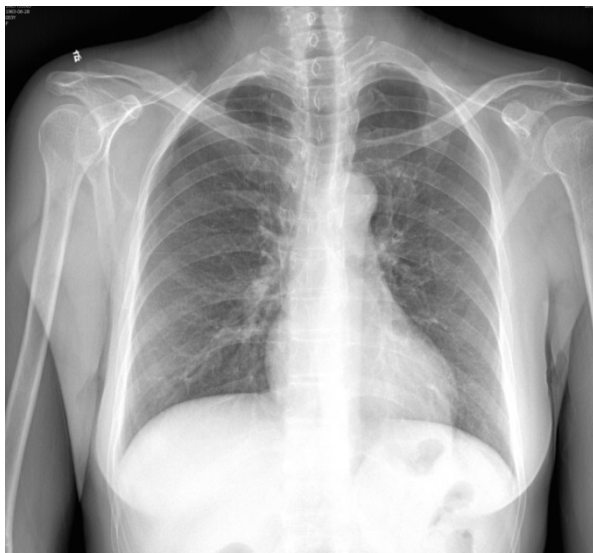

Figure 1: Chest X-ray film showed a normal size heart with clear lung markings.

Electrocardiograph(ECG) showed sinus rhythm with incomplete right bundle branch block. Transthoracic echocardiography demonstrated a normal left ventricle size (left ventricular end-diastolic diameter: 44 mm) and function, non-dilated left atrium, normal mitral

and aortic valves, a mildly dilated right ventricle (right ventricular end-diastolic diameter: 41 mm) with a broad base mass attached to the interventricular septum. Non-enhanced computed tomography(CT) showed spherical mass with circular opacity measuring 4.8 cm × 4.1 cm in the right ventricle, which was supplied by the first major septal branch of the left anterior descending artery and moderately enhanced on ECG-gated CT scan (Figure 2).

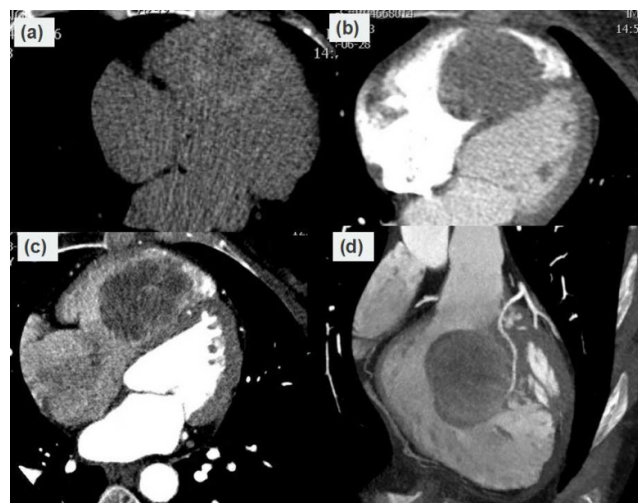
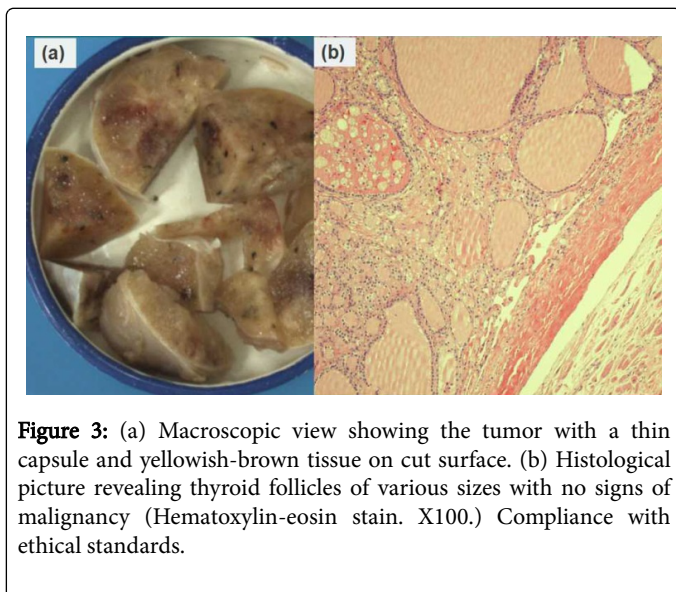


Figure 2: (a) Non-enhanced CT image demonstrating a spherical mass with circular opacity in the region of right ventricle. (b and c) Contrast ECG-gated cardiac CT demonstrating a hypodense mass with a broad base attached to interventricular septum and growing into right ventricular chamber. (d) Reconstructed coronary artery image revealing the first septal branch of left anterior descending artery feeding the tumor.

Angiography was not performed because of the potential risk of peripheral embolization due to the dislodgement of tumor fragment or surface thrombosis. Because a primitive cardiac tumor was highly suspected, exploratory surgery was performed. Intraoperative inspection revealed a red mass with a broad base arising from the

middle-upper part of the interventricular septum close to the septal leaflet of the tricuspid valve. Excised mass measured 4.8 cm × 3.7 cm × 3.5 cm with an incomplete fibrous capsule. The cut surface of the specimen was yellowish-brown tissue with scattered areas of hemorrhage. Histologic examination demonstrated thyroid follicles of various sizes filled with colloid tissue (Figure 3). Final diagnosis of intracardiac ectopic thyroid tissue was established. The patient's postoperative course was uneventful. Echocardiographic study did not show any evidence of the recurrence, and abnormalities of thyroid function were not found at postoperative 12 months follow-up.



Different pathologies like neoplastic, inflammatory or thrombotic process manifest as intracardiac masses. Intracardiac mass from ectopic thyroid tissue is an exceedingly rare condition, although ectopic thyroid tissue may be observed in abnormal location from the tongue base to the mediastinum [1]. The hypothesis that intracardiac ectopic thyroid is due to abnormal persistence of contact between the thyroid primordium and the bulbus cordis during embryogenesis is convincing, because the site of ectopic thyroid is almost in the right ventricular septal surface in those middle-age female patients. Certain characteristics identified on noninvasive imaging may help distinguish

neoplastic versus non-neoplastic masses and benign versus malignant tumors [2]. Echocardiography remains the first line technique for cardiac mass evaluation because of its widespread availability and its dynamic assessment of cardiac masses in the relation to the surrounding chambers, valves, and pericardium. Specific CT protocols unique from those typically utilized for coronary imaging can help obtain high quality images for assessing the cardiac masses, as described in our patient. CT appearances concerning intracardiac ectopic thyroid are rarely documented. Prior to surgery, we speculated this tumor to be benign possibility based on intracardiac mass with well-defined margin and paucity of feeding vessel after contrast enhancement. In this patient, intracardiac mass together with its feeding artery was clearly delineated. Unlike true neoplastic intracardiac tumour which necessitates surgical resection, both surgical and non-surgical approaches may be considered for an intracardiac ectopic thyroid. Therefore, for middle-age female patients with an intracardiac mass in the right ventricular septal surface detected by imaging investigations, ectopic thyroid tissue should be kept in mind in the differential diagnosis and may be further identified by thyroid scintigraphy [3].

Conclusion

In conclusion, intracardiac thyroid tissue presenting with solid mass detected by routine echocardiography is an exceedingly rare condition. ECG-gated CT scan can definitely demonstrate the lesion's site and its feeding vessels. Its possibility should be considered due to its typical location in the right ventricular outflow tract in those middle-age female patients.

References

1. Rabus MB, Poci N, Yilmaz F, Yerlikhan O, Aktemur T, et al. (2015) Right ventricular mass: intracardiac ectopic thyroid tissue: A case report. *Echocardiography* 32: 178-180.
2. Kassop D, Donovan MS, Cheezum MK, Nguyen BT, Gambill NB, et al. (2014) Cardiac masses on cardiac CT: A review. *Curr Cardiovasc Imaging Rep* 7: 9281.
3. Noussios G, Anagnostis P, Goulis DG, Lappas D, Natsis K (2011) Ectopic thyroid tissue: anatomical, clinical, and surgical implications of a rare entity. *Eur J Endocrinol* 165: 375-382.