

## Retinal Angiomatous Proliferation in Adult Onset Coat's Disease Angiomatous Proliferation in Coat's Disease

Nurgül Örnek<sup>1\*</sup>, Tevfik Oğurel<sup>1</sup>, Kemal Örnek<sup>2</sup>, and Hatice Ayhan Güler<sup>1</sup>

<sup>1</sup>Department of Ophthalmology, School of Medicine, Kırıkkale University, Turkey

<sup>2</sup>Private Practice, Ankara, Turkey

\*Corresponding author: Nurgül Örnek, Department of Ophthalmology, School of Medicine, Kırıkkale University, Turkey, Tel: +90 532 4309289; E-mail: nurgul\_ornek@hotmail.com

Received date: November 12, 2017; Accepted date: November 22, 2017; Published date: November 24, 2017

Copyright: © 2017 Örnek N, et al. This is an open-access article distributed under the terms of the Creative Commons Attribution License, which permits unrestricted use, distribution, and reproduction in any medium, provided the original author and source are credited.

### Abstract

A 31 year old female patient had decreased vision in her left eye for several months. Visual acuity was 20/20 in right eye and counting fingers from 2 m in left eye. Examination of left eye demonstrated massive macular exudation with grayish discoloration of central macula and, aneurysmal and telangiectatic vessels with surrounding exudation in temporal mid peripheral retina. Optical coherence tomography of left eye showed findings consistent with neovascular complex, pigment epithelial detachment, subretinal fluid and involvement of choroid. There was hyperfluorescent focus with perfusing retinal arteriole and draining venule at the fovea which was compatible with retinal angiomatous proliferation (RAP) in early phase fundus fluorescein angiography and leakage was observed in late phase. After 3 doses of monthly-injected intravitreal ranibizumab and argon laser photocoagulation applied on aneurysmal and telangiectatic vessels, we observed central macular fibrosis, minimal lipid exudation and no macular edema. So retinal angiomatous proliferation may be a feature of adult onset Coats' disease.

**Keywords** Adult onset Coats' disease; Retinal angiomatous proliferation

### Introduction

Adult onset Coats' disease is a rare, idiopathic and exudative retinal vascular disease without an inciting factor and with slow progression. It frequently occurs in males and is typically unilateral. Localized lipid deposition and hemorrhage around macroaneurysms are often present both at peripheral and juxtamacular areas [1,2].

Retinal Angiomatous Proliferation (RAP) (type 3 neovascularization) emphasizes the intraretinal location of the neovascularization and originates not only from deep retinal capillaries but also from the choroid. It is characterized by telangiectatic response associated with intraretinal proliferative activity, leading to retinal-retinal and retino-choroidal anastomosis [3].

Recently RAP has been reported in 24% (5 of 21 patients) of childhood Coats' disease by Sigler et al. [4]. But there is no adult onset Coats' disease associated with RAP in the literature. Herein we describe the first adult onset Coats' disease associated with RAP.

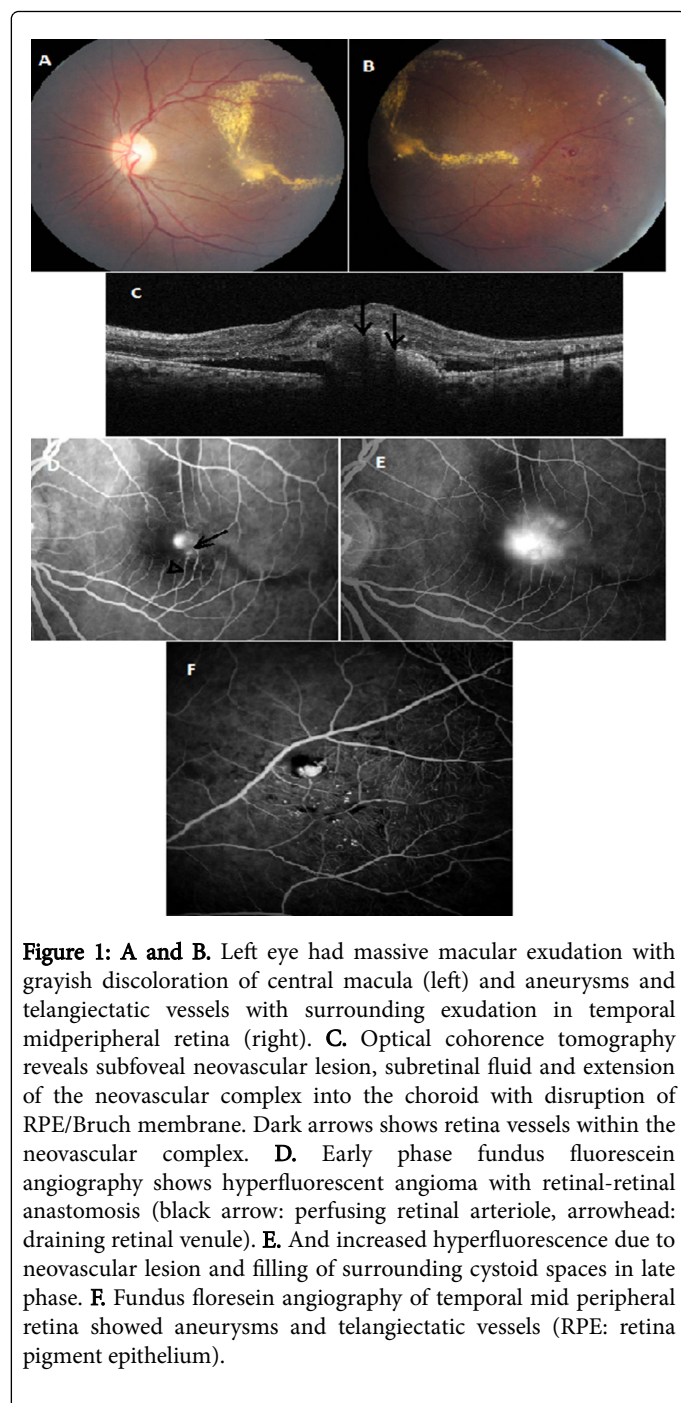
### Case Report

A 31 year old female patient had decreased vision in the left eye for several months. She did not have any systemic diseases. Best corrected visual acuity was 20/20 in the right eye and counting fingers from 2 m in the left eye. Anterior segment examination did not reveal any abnormal findings. Fundus examination of right eye was normal. There was dense macular exudation with grayish discoloration of central

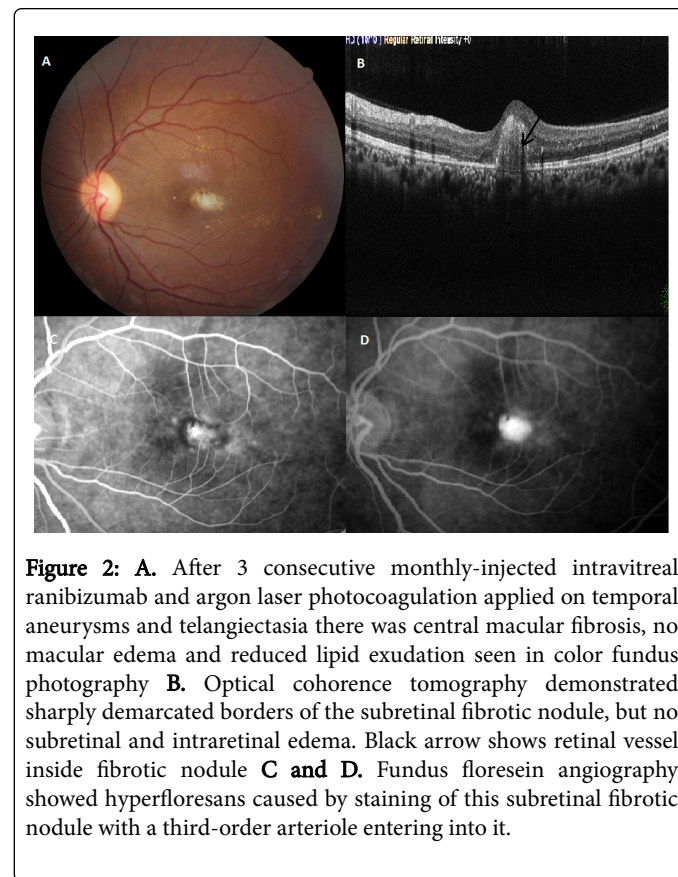
macula and aneurysmal and telangiectatic vessels with surrounding exudation at temporal midperipheral retina (Figures 1A and 1B).

After complete ophthalmological examination, optical coherence tomography (OCT) (Retinascan Advanced RS-3000; NIDEK, Japan) imaging and fundus fluorescein angiography (FFA) (Canon Inc., Tokyo, Japan) were performed. OCT demonstrated subretinal fluid, subfoveal neovascular complex extending into the choroid with disruption of RPE/Bruch membrane complex and hyporeflective vessel tracks in neovascular complex (black arrows) (Figure 1C). Early phase FFA showed hyperfluorescent angioma with perfusing retinal arteriole (arrow) and draining venule (arrowhead) (retinal-retinal anastomosis) at fovea and there was leakage due to neovascular complex and filling of surrounding cystoid spaces in late phase (Figures 1D and 1E). And FFA of temporal midperipheral retina showed aneurysmal and telangiectatic vessels (Figure 1F).

After 3 consecutive monthly-injected intravitreal ranibizumab and argon laser photocoagulation applied on temporal aneurysms and telangiectatic vessels, there was central macular fibrosis, no macular edema and reduced lipid exudation (Figure 2A). OCT also revealed sharply demarcated borders of the subretinal fibrotic nodule with retinal vessel inside (black arrow), but there was no subretinal and intraretinal edema (Figure 2B). Hyperfluorescens caused by staining of this subretinal fibrotic nodule with a third-order arteriole entering into it by FFA (Figures 2C and 2D). Best corrected visual acuity was counting fingers from 4 m in the left eye.



edema, macular exudation, epiretinal membrane, foveal ischemia, sensory macular detachment have been reported in adult onset Coats' disease [1,5].



**Figure 2:** A. After 3 consecutive monthly-injected intravitreal ranibizumab and argon laser photocoagulation applied on temporal aneurysms and telangiectasia there was central macular fibrosis, no macular edema and reduced lipid exudation seen in color fundus photography B. Optical coherence tomography demonstrated sharply demarcated borders of the subretinal fibrotic nodule, but no subretinal and intraretinal edema. Black arrow shows retinal vessel inside fibrotic nodule C and D. Fundus floresein angiography showed hyperfloresans caused by staining of this subretinal fibrotic nodule with a third-order arteriole entering into it.

RAP has rarely been reported in conditions other than age-related macular degeneration, such as radiation retinopathy, syphilitic retinopathy, retinitis pigmentosa and childhood Coats' disease [4,6-8]. Sigler et al. [4] reported presence of RAP lesion with chorioretinal anastomosis in 5 of 21 patients with childhood Coats' disease. And Rishi et al. [9] also showed chorioretinal anastomosis in a 4-year old patient with Coats' disease. Macular fibrosis in Coats' disease reveals subretinal white-gray scar which is usually associated with vascular component at subfoveal area. Association of macular fibrosis with retinal-retinal anastomosis, intraretinal, subretinal and choroidal neovascularization were reported in previous studies [4,9,10]. Although factors initiating neovascularization in Coats' disease are not clear yet, we agree with the previous manuscripts that severe macular lipid exudation leading to inflammatory stimulus, elevated vascular endothelial growth factor levels from ischemic peripheral retina and abortive defect during angiogenesis of retinal mid-capillary plexus can be possible causes [9,10]. Also we agree with Sigler and Rishi [4,9] that aberrant vascular communicating channels which are seen in Coats' disease could favor formation of retinal-retinal and retina-choroidal anastomosis which are poor prognostic sign for treatment of neovascular complex.

As far as we know, this is the only case in the current literature who has RAP (type 3 neovascularization) lesion complicating adult onset Coats' disease. Although indocyanine green angiography is needed for the diagnosis of RAP, spectral domain OCT and FFA when evaluated together can help for the diagnosis, as the case we reported herein.

## Discussion

Adult onset Coats' disease has retinal features different from the childhood onset Coat's disease. Although retinal exudation and telangiectasia are hallmark for diagnosis as in childhood Coats' disease, less extensive retinal involvement, more benign natural course and a more favorable treatment outcome were reported in adult onset Coats' disease. In their series of 48 eyes, Rishi et al. [1] reported that decreased vision was the most common (83%) presenting sign probably due to more prevalent macular involvement in adult onset Coats' disease. Macular involvement due to macular fibrosis, macular

Further studies would be required to understand this phenomenon more.

## References

1. Rishi E, Rishi P, Appukuttan B, Uparkar M, Sharma T, et al. (2016) Coats' disease of adult onset in 48 eyes. *Indian J Ophthalmol* 64: 518-523.
2. Jun JH, Kim YC, Kim KS (2008) Resolution of severe macular edema in adult Coats disease with intravitreal triamcinolone and bevacizumab injection. *Korean J Ophthalmol* 22: 190-193.
3. Freund KB, Ho IV, Barbazetto IA, Koizumi H, Laud K, et al. (2008) Type 3 neovascularization: the expanded spectrum of retinal angiomatous proliferation. *Retina* 28: 201-211.
4. Sigler EJ, Calzada JI (2015) Retinal angiomatous proliferation with chorioretinal anastomosis in childhood Coats disease: a reappraisal of macular fibrosis using multimodal imaging. *Retina* 35: 537-546.
5. Otani T, Yasuda K, Aizawa N, Sakai F, Nakazawa T, et al. (2011) Over 10 years follow-up of Coats' disease in adulthood. *Clin Ophthalmol* 5: 1729-32.
6. Mendrinós E, Pilly B, Baglivo E, Donati G, Safran AB, et al. (2009) Chorioretinal anastomosis as a rare complication of radiation retinopathy. *Acta Ophthalmol* 87: 473-475.
7. Rouvas A, Petrou P, Maselos S, Douvali M, Vergados I, et al. (2009) Retinal angiomatous proliferation (RAP) in a 42-year-old woman with syphilitic retinitis. *Ocul Immunol Inflamm* 17: 361-363.
8. Sayadi J, Miere A, Souied EH, Cohen SY (2017) Type 3 Neovascularization Associated with Retinitis Pigmentosa. *Case Rep Ophthalmol* 8: 245-249.
9. Rishi P, Rishi E, Bhojwani D (2017) Coats' disease with retinochoroidal anastomosis. *Oman J Ophthalmol* 10: 112-113.
10. Jumper JM, Pomerleau D, McDonald HR, Johnson RN, et al. (2010) Macular fibrosis in Coats disease. *Retina* 30: 9-14.