

Re-insertion of Gastric Feeding Tube via Previous Surgical Gastrostomy in Elderly Sick Patient with Reflux Oesophagitis Secondary to Gastrointestinal Motility Disorder: Case Report

Rauya EZ*, Rutahoile WM and Zhang BQ

Department of Gastroenterology, the First Affiliated Hospital of Chongqing Medical University, PR China

*Corresponding author: Rauya EZ, Department of Gastroenterology, Chongqing Medical University First Affiliated Hospital, Yuzhong District Chongqing, 400016, PR China, Tel: +8615803053539; E-mail: engelius@yahoo.com

Received date: April 27, 2017; Accepted date: May 11, 2017; Published date: May 15, 2017

Copyright: © 2017 Rauya EZ, et al. This is an open access article distributed under the terms of the Creative Commons Attribution License, which permits unrestricted use, distribution, and reproduction in any medium, provided the original author and source are credited

Abstract

Background: Reflux oesophagitis is an esophageal mucosal injury that occurs secondary to retrograde flux of gastric contents into the esophagus. Here, we reported a case of re-insertion of gastric feeding tube (RIGFT) to an old man who underwent gastrostomy due to progressive Dysphagia secondary to reflux oesophagitis.

Methods: We report the case of re-insertion of gastric feeding tube in an elderly man who could not undergo PEG and open surgical gastrostomy.

Case presentation: An 85-year-old man with advanced Parkinson dementia, presented with progressive Dysphagia, fever, disorientation and recurrent aspiration pneumonia. He had a history of open abdominal surgical gastrostomy which was performed under spinal anesthesia and gastric tube was inserted successfully. Three months later the patient pulled out the tube and was referred to our teaching hospital and the next day re-insertion was performed.

Conclusion: For elderly patients who cannot undergo the percutaneous endoscopic gastrostomy and open surgical gastrostomy under general anesthesia should be recommended for re-insertion of gastric feeding tube via previous surgical orifice under local anesthesia. Therefore, percutaneous re-insertion should be considered as option to all patients who are contraindicated to surgery.

Keywords: Dysphagia; Reflux oesophagitis; Parkinson dementia; Gastric feeding tube; Gastrostomy; Aspiration pneumonia

Introduction

Difficult of swallowing or Dysphagia is related with ageing and results from various co-morbid medical conditions. Dysphagia presents a major risk of aspiration pneumonia and malnutrition in frail older people [1,2].

To overcome the aspiration pneumonia and avoid malnutrition to old dysphagic patients; enteral feeding is preferred. There are several techniques which can be employed. The most preferable techniques are percutaneous endoscopic gastrostomy, percutaneous radiological gastrostomy and surgical gastrostomy [3,4]. However, surgical gastrostomy is technically simple, but it involves an abdominal incision under general anaesthesia. Since most elderly patients are malnourished, often present with co-morbidities, the operative risk is high and may involve complication such as leakage, poor healing, local infection and increased morbidity [5].

In our case of 85 years old man who had open abdominal gastrostomy but eventually three months later he pulled it out; and then, re-insertion of the gastric tube was performed successfully through the same previous surgical incision orifice under local anaesthesia; with the aid of X-ray, contrast material and guidance of guide wire.

Case Report

An 85 years old man with history of Parkinsonism and dementia disease for two years and had been diagnosed to have coronary arterial disease. He had been hospitalized for five months at the First Affiliated Hospital of Chongqing Medical University and he also suffered from severe aspiration pneumonia and reflux esophagitis. On admission he presented with history of progressive Dysphagia, fever and disorientation. He had undergone open abdominal surgical gastrostomy under spinal (lumbar) anaesthesia prior to admission. Due to his severe aspiration pneumonia and other co-morbidities the patient was not good candidate for either PEG or open abdominal gastrostomy. Therefore the option was to re-insert the gastric tube. This procedure was performed in the radiological room. The patient was supine positioned and aseptic technique was employed. We first identified the previous incision orifice on abdomen skin; Lidocaine 2% was used for pain relief. Cannula was inserted followed by guide wire. During catheter advancement we encountered difficulties to pass through the narrowed part of tract and then ballooning technique was employed to dilate the passage and aid the catheter advancement. With the aid of iohexol contrast material, the correct position of the tube was inserted into the intragastric region. After re-insertion of the tube, it was then fixed by suturing it on the abdominal skin and we confirmed intragastric positioning of the tube radiologically (Figures 1-4).

Image Representation of Procedure

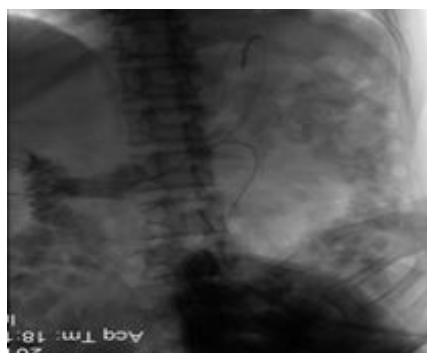

Figure 1: Shows the insertion of guide wire and angiographic catheter as it passes through previous surgical fistula, we could see the wire pass to the duodenum then back to the fundus of stomach.

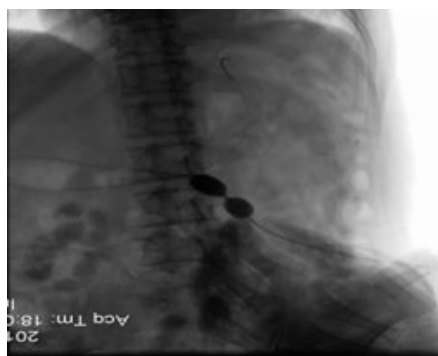

Figure 2: Demonstrates ballooning of narrow part of fistula to (enlarge the diameter) after injection of contrast material.

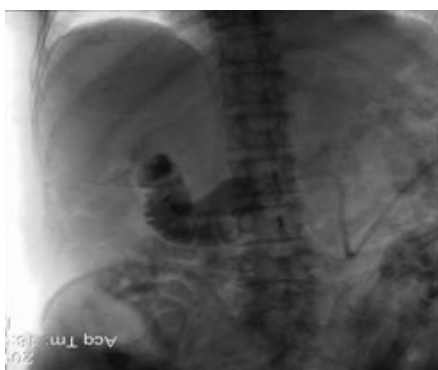

Figure 3: Shows a big size tube could pass through easily to the former narrow area.

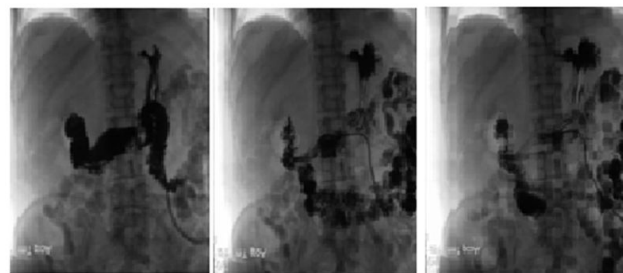


Figure 4: Clearly demonstrates the large tube inside the stomach (Left, centre and right), we can also see the contrast agent pass into the intestines, and severe reflux of gastro esophageal is seen on the right graph.

Discussion

Nutritional feeding to patients who are having difficulty on swallowing and succumb from severe aspiration pneumonia can be delivered into two methods, notably, parenterally or enterally depending on route of administration, calories contents and reason for indications. Enteral feeding is usually the favoured method over parenteral feeding in patients with a functional gastrointestinal system due to the associated risks of the intravenous route to septicemia and bacteremia, higher cost and incapability of parenteral nutrition to trigger enteral stimulation and subsequent weaken of the gut defense barrier [6]. The method for delivering nutrition through enteral can be via nasogastric tube or gastrostomy. Nasogastric tube is used for temporary bases and long term use of nasal tube can cause gastroesophageal reflux and aspiration pneumonia while gastrostomy is used for long term uses [6]. A gastrostomy tube is a tube placed into the stomach through the skin that can be used for giving fluid, nutrition, or medications. It can also be used for drainage. Access to insert the gastrostomy tube can be achieved by the use of endoscopy, radiological imaging, or surgical techniques (open or laparoscopic) 4 most of dementia patients with Dysphagia problem are prone to dislodgement of gastrostomy tube and they necessitate re insertion of gastric tube; the procedure to rescue the dislodgment is by doing cannulation of subcutaneous track of which when it is done within 24 hours to 48 hours the reported success rate is high as 87% but on average success rate most of the time is under achieved [7]. In order to prevent the closure of the stoma, blind cannulation of percutaneous track with a soft and blunt catheter such as folley catheter can be used immediately. It is safe and effective means of conserve access route [8] but if resistant is encountered on the way further proceeding should not be tried.

Since there are no guidelines or consensus regarding principles of gastrostomy tube replacement protocols [9]. There are some proposed principles on PEG replacement which include proper control of the replacement tube with a well-formed gastro-cutaneous tract; lesser insertion force during replacement; and reliable mode of confirmation of intragastric tube insertion. Re-inserting a new tube along the proper tract requires the railroad or the modification of Seldinger techniques or inserting a new tube under direct endoscopic view [10-17]. In the case of pulled out gastrostomy tube and patient is contraindicated to PEG or open surgical gastrostomy, but requires re-insertion of the tube through the previous existing stoma site; fluoroscopic guidance is the preferred procedure [18]. In our present case of an elder sick patient

was not good candidate for both PEG and surgery and we therefore employed the railroad fluoroscopic guidance to go through the previous stoma site and re-inserted the tube successfully.

The advantage of this technique requires shorter time to perform the procedure of about 20 minutes and also it is cost effective [18]. This is similar to our case in some extent since the procedure time was lesser than 20 minutes, less cost effective and in addition we used a new gastrostomy tube to decrease the risk of infection.

Conclusion

In conclusion, this case report shows that fluoroscopy-guided re-insertion of gastrostomy tube through the existing previous surgical stoma site is a safe procedure that does not require general anesthesia and it is less cost and less time consuming. We therefore recommend this procedure to elderly patients who cannot undergo the percutaneous endoscopic gastrostomy and open surgical gastrostomy.

Acknowledgements

Thanks to radiological team for figure images.

References

1. van der Maarel-Wierink CD, Vanobbergen JN, Bronkhorst EM, Schols JM, de Baat C (2011) Risk factors for aspiration pneumonia in frail older people: A systematic literature review. *J Am Med Dir Assoc* 12: 344-354.
2. Vanderwee K, Clays E, Bocquaert I, Gobert M, Folens B, et al. (2010) Malnutrition and associated factors in elderly hospitalpatients: a Belgian cross-sectional, multi-centre study. *Clin Nutr* 29: 469-476.
3. Rahnemai-Azar AA, Rahnemaiazar AA, Naghshizadian R, Kurtz A, Farkas DT (2014) Percutaneous endoscopic gastrostomy: Indications, technique, complications and management *World J Gastroenterol* 20: 7739-7775.
4. Tsukuda T, Ito K, Koike S, Sasaki K, Shimizu A, et al. (2005) Pre- and postprandial alterations of portal venous flow: evaluation with single breath-hold three dimensional half-fourier fast spin-echo MRI imaging and a selective inversion recovery tagging pulse. *J Magn Reson Imaging* 22:527-533.
5. Chen HL, Shih SC, Bair MJ, Lin IT, Wu CH (2011) Percutaneous endoscopic gastrostomy in the enteral feeding of the elderly. *Int J Gerontol* 5: 135-138.
6. DiSario JA (2006) Endoscopic approaches to enteral nutritional support. *Best Pract Res Clin Gastroenterol* 20: 605-6330.
7. Collares FB, Faintuch S, Kim SK, Rabkin DJ (2010) Reinsertion of accidentally dislodged catheters through the Original track: what is the likelihood of success? *J Vasc Interv Radiol* 21: 861-864.
8. Stiglick AJ, Baerlocher MO, Asch M, Myers A, Ho CS (2008) Percutaneous feeding tubes. *Can Fam Physician* 54: 1255-1257.
9. Varut Lohsiriwat (2013) Percutaneous endoscopic gastrostomy tube replacement: A simple procedure? *World J Gastrointest Endosc* 5: 14-18.
10. Higgs ZC, Macafee DA, Braithwaite BD, Maxwell-Armstrong CA (2005) The Seldinger technique: 50 years on. *Lancet* 366: 1407-1409.
11. Seldinger SI (1953) Catheter replacement of the needle in percutaneous arteriography; a new technique. *Acta radiol* 39: 368-376.
12. Au FC (1989) Reinsertion of a gastrostomy tube using the Seldinger technique. *J Parenter Enteral Nutr* 13: 436-437.
13. Frenz MB, Siuda G, McIntyre AS, Travis SP (2004) A simple and safe method of transcutaneous gastrostomy replacement using the Seldinger technique. *Endoscopy* 36: 250.
14. Chan SC, Ko SF, Ng SH, Cheung YC, Chang JT, et al. (2004) Fluoroscopically guided percutaneous Gastrostomy with modified gastropexy and a large-bore balloon-retained catheter in patients with head and neck Tumors. *Acta Radiol* 45: 130-135.
15. Konishi H, Okano H, Fukumoto K, Miyawaki K, Wakabayashi N, et al. (2012) Usefulness of a novel observation method using a small-diameter rigid telescope through the gastrostomy catheter at exchange. *Dig Endosc* 24: 243-246.
16. Turner P, Deakin M (2009) Percutaneous endoscopic gastrostomy Tube removal and replacement after "buried bumper syndrome": The simple way. *Surg Endosc* 23: 1914-1917.
17. Binnebösel M, Klink CD, Otto J, Schumpelick V, Truong S (2010) A safe and simple method for removal and replacement of a percutaneous endoscopic gastrostomy tube after "buried Bumper syndrome". *Endoscopy* 42: E17-E18.
18. Uflacker A, Qiao Y, Easley G, Patrie J, Lambert D, et al. Fluoroscopy-guided jejunal extension tube placement through existing gastrostomy tubes: Analysis of 391 procedures. *Diagn Interv Radiol* 21: 488-493.