

Review

Open Access

Rehabilitation Program after Cell Therapy for Treatment of Femoral Head Osteonecrosis: A Narrative Review of Literature

Tomoki Aoyama*

Human Health Sciences, Graduate School of Medicine, Kyoto University, Kyoto, Japan

*Corresponding author: Tomoki Aoyama, Department of Physical Therapy, Human Health Sciences, Graduate School of Medicine, Kyoto University, 53 Kawahara-cho, Shogoin, Sakyo-ku, Kyoto 606-8507, Japan, Tel: 81-75-751-3952; Fax: 81-75-751-3909; E-mail: blue@hs.med.kyoto-u.ac.jp

Received date: June 05, 2016; Accepted date: July 16, 2016; Published date: July 19, 2016

Copyright: © 2016 Aoyama T. This is an open-access article distributed under the terms of the Creative Commons Attribution License, which permits unrestricted use, distribution, and reproduction in any medium, provided the original author and source are credited.

Abstract

Recent development in the clinical application of cell therapy is potentially useful for treatment of osteonecrosis of the femoral head (ONFH). Rehabilitation is essential to improve the hip joint function and activity of patients. Rehabilitation program after cell therapy for ONFH treatment and other regenerative medicine fields is known. This narrative review aimed to assess the actual state of the rehabilitation program after cell therapy for ONFH. Seventeen publications met the inclusion criteria and were included in the review. This review focused on weight bearing, muscle strength exercise, range of motion exercise, and physical activity. Considerable information is available on weight bearing, but data on muscle strength exercise, range of motion exercise, and physical activity are insufficient. The initial timing of weight bearing may influence the result. Biomechanical, biophysical, physiological, and radiological knowledge are essential in designing the protocol. Moreover, knowledge on cell biology is required to promote the effect of cell therapy.

Keywords: Osteonecrosis; Femoral head; Cell therapy; Regenerative medicine; Rehabilitation program; Mesenchymal stromal cells; Bone marrow-derived mononuclear cells

Introduction

Cell therapy is a promising treatment for refractory diseases, such as idiopathic osteonecrosis of the femoral head (ONFH), which is difficult to treat [1]. ONFH is a painful disorder and progresses to femoral head collapse, which results in osteoarthritis of the hip joint in young adult [1]. Numerous joint-preserving procedures, such as core decompression (CD) surgery, osteotomy surgery, and physiotherapy, have been performed [2]. Recent development in the clinical application of cell therapy is expected to promote the joint-preserving procedure. Some promising results have been reported for the treatment of ONFH using cell therapy [3-5]. However, the rehabilitation program for this treatment still requires further development. This narrative review aimed to assess the actual state of the rehabilitation program after cell therapy for ONFH.

Literature Review Methods

Data sources

The PubMed database was searched for peer-reviewed, full text articles that are published in English from January 2005 to December 2015. The following search terms were used: osteonecrosis femoral head, cell therapy, and English [la] from 1/1/1995 to 12/31/2015.

Criteria for inclusion

The inclusion criteria were as follows: (1) clinical trials including clinical cases for the treatment of idiopathic osteonecrosis of the femoral heads in humans; (2) treatment was performed by cell transplantation; (3) participants were 18 years old and above; (4)

rehabilitation program was described; and (5) the publication was written in English.

Results

Search results

The literature search yielded 121 publications, with 34 publications reviewed in full (Figure 1). Seventeen publications met the inclusion criteria and were included (Figure 1). Publications were excluded based on the following criteria: (1) review article; (2) clinical trials on other diseases; (3) animal subjects; (4) patients <18 years of age; and (5) undescribed rehabilitation program (Figure 1).

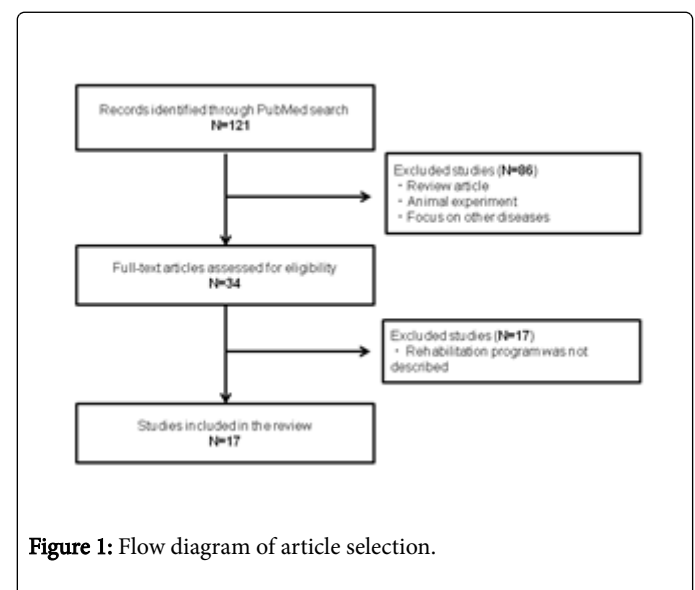


Figure 1: Flow diagram of article selection.

Treatment using cell therapy was performed in combination with CD surgery [4,6-15] or debridement of necrotic bone surgery [15-21] (Table 1). Bone marrow-derived mononuclear cells (BM-MNCs) [4,6-13,16-20] and cultured mesenchymal stromal cells (MSCs) [14,15,21] were used for the cell transplantation (Table 1). When debridement surgery is performed, some scaffolds, such as hydroxyapatite, cancellous bone chips, and beta tricalcium phosphate, are transplanted together [15-21]. Radiological staging used for the decision of inclusion criteria and clinical evaluation according to Ficat, Association Research Circulation Osseous, Specific Disease Investigation Committee, and Steinberg classification system is shown in detail in Table 2.

Author	Radiologic Stage	Transplantation Technique	Weight Bearing	Muscle Strength Exercise	Range Of Motion Exercise	Sports And Physical Activity
Hernigou et al. [4]		CD+BM-MNCS	NWB with crutches for 10 days FWB is allowed thereafter	NR	NR	NR
Wang et al. [6]	ARCO	CD+BM-MNCS	NWB with crutches for 2 weeks FWB is allowed thereafter	NR	NR	NR
Sen et al. [7]	ARCO	CD+BM-MNCS	FWB is allowed 6 weeks after surgery	NR	NR	NR
Zhao et al. [8]	ARCO	CD+BM-MNCS	FWB is allowed 6 weeks after surgery	Quadriceps muscle 1 day after surgery	Passive ROM 1 day after surgery	NR
Chotivichit et al. [9]	Ficat	CD+BM-MNCS	PWB is allowed 6 weeks after surgery	NR	NR	NR
Mao et al. [10]	Ficat	CD+BM-MNCS	PWB is allowed 4 days after surgery FWB is allowed 3 months after surgery	Functional training 1 day after surgery	NR	12 months after surgery
Ma et al. [11]	FICAT	CD+BM-MNCS	NWB was instructed for 4 weeks after surgery	NR	NR	NR
Chotivichit et al. [12]		CD+BM-MNCS	PWB is allowed 6 weeks after surgery	NR	NR	NR
Tabatabaee et al. [13]	ARCO	CD+BM-MNCS	FWB is allowed 3 weeks after surgery	NR	NR	NR
Rastogi et al. [14]	ARCO	CD+MSC	PWB is allowed 2 weeks after surgery FWB is allowed 4 weeks after surgery	NR	NR	NR
Persiani et al. [15]	Steinberg	CD+MSC	PWB is allowed 5 weeks after surgery FWB is allowed 8 weeks after surgery	Strengthen gluteus and quadriceps muscles	Gradual coxofemoral joint motion	NR
Yamasaki et al. [16]	SDIC	CD BM-MNCS +Porous Hydroxyapatite	PWB is allowed one week after surgery FWB is allowed 3 weeks after surgery	NR	NR	NR
Liu et al. [17]	ARCO A	CD +BM-MNCS +Porous Hydroxyapatite	PWB is allowed 3 months after surgery FWB is allowed 6 months after surgery	NR	NR	12 months after surgery
Kang et al. [18]	Steinberg	CD +BM-MNCS +Cancellous Bone Chip	PWB is allowed 6 weeks after surgery	NR	NR	NR

			FWB is allowed 12 weeks after surgery			
Martin et al. [19]	Ficat	CD +BM-MNCS +Platelet-rich Plasma	Weight bearing with crutches for 2 weeks	NR	NR	NR
Wang et al. [20]	ARCO	Debridement +BM-MNCS +Cancellous Bone Chip	PWB is allowed 12 weeks after surgery FWB is allowed 6 months after surgery	NR	NR	12 months after surgery
Aoyama et al. [21]	SDIC	Debridement +MSC +Cortical Bone +bTCP	PWB is allowed 6 weeks after surgery FWB is allowed 3 months after surgery	Isotonic exercises are allowed 6 weeks after surgery Isokinetic exercises are allowed 8 weeks after surgery	Passive ROM 2 weeks after surgery Active ROM 3 months after surgery	6 months after surgery
ARCO: Association Research Circulation Osseous Classification System; SDIC: Specific Disease Investigation Committee Classification System; CD: Core decompression; BM-MNCS: Bone Marrow Derived Mononuclear Cells; MSC: Mesenchymal Stromal Cell; bTCP: Beta Tricalcium Phosphate; NWB: Non-Weight Bearing; PWB: Partial Weight Bearing; FWB: Full-Weight Bearing; ROM: Range of Motion; NR: Not Reported; THA: Total Hip Replacement.						

Table 1: Rehabilitation program after cell therapy for the osteonecrosis treatment of the femoral head.

	Ficat	ARCO	SDIC	Steinberg
Stage 1	Normal radiographs	Normal radiographs. However, specific findings are observed on MRI, bone scintigram, or histology	No specific findings of osteonecrosis on X-ray images. However, specific findings are observed on MRI, bone scintigram, or histology	Normal radiographs. Abnormal bone scan and MRI
Stage 2	Subchondral cyst and sclerosis	Demarcating sclerosis is seen without collapse of the femoral head	Demarcating sclerosis is seen without collapse of the femoral head	"Cystic" and aclerotic changes in femoral head
Stage 3	Femoral head flattening, subchondral collapse, "crescent sign"	Femoral head collapse, "crescent sign", no joint space narrowing	Collapse of the femoral head, including crescent sign, is seen without joint-space narrowing. Mild osteophyte formation of the femoral head or acetabulum may be seen	Subchondral collapse without femoral head flattening
3A		Collapse<3 mm	Collapse of the femoral head is less than 3 mm	
3B		Collapse>3 mm	Collapse of the femoral head is 3 mm or greater	
Stage 4	Osteoarthritic joint space narrowing, degenerative changes	Osteoarthritic degenerative changes	Osteoarthritic changes are seen	Subchondral collapse, femoral head flattening, normal joint space
Stage 5				Flattening with joint space narrowing, acetabular changes, or both
Stage 6				Advanced degenerative changes, secondary osteoarthritis
ARCO: Association Research Circulation Osseous; SDIC: Specific Disease Investigation Committee; MRI: Magnetic Resonance Imaging.				

Table 2: Radiological staging of Osteonecrosis.

Weight bearing

Considerable information about the timing of initiation of weight bearing after cell therapy is available (Table 1). The clinical conditions of ONFH vary according to the radiological stages. In the early stages

(stages 1 and 2), the femoral head has not collapsed, whereas in the advanced stages (stages 3 and 4), it has already collapsed (Table 2). The timing of initiation of weight bearing should be according to radiological stages. The reports were re-sorted according to transplantation technique, radiologic stage, and timing of initiation of

weight bearing, and then compared with the clinical radiologic results (Table 3). The timing of initiation of weight bearing before 4 weeks was defined as “early bearing,” after 4 weeks to 3 months as “late bearing,” and after 3 months as “very late bearing” (Table 3).

Transplantation Technique	Radiologic Stage	Follow Up	Mean Age (Old)		Weight Bearing	Progression Of Disease	Author
CD+BM-MNCs (MSC)		13 years	39	Early Bearing	NWB with crutches 10 days. FWB is allowed thereafter	THA was needed in 17.6% (94/534) hips	Hernigou et al. [4]
	ARCO	27.6 months	37.5		NWB with crutches 2 weeks. FWB is allowed	Femoral head was collapsed in 23.7% (14/59) hips. THA was needed in 11.9% (7/59) hips	Wang et al. [6]
	ARCO	24 months	31		FWB allowed 3 weeks	Radiological progress was observed in 0% (0/14) hips. THA was needed in 10.0% (3/30) hips	Tabatabaee et al. [13]
	ARCO	24 months	34.7		PWB allowed 2 weeks and FWB allowed 4 weeks	Radiological progress was observed in 13.3% (4/30) hips. THA was needed in 19.3% (6/31) hips	Rastogi et al. [14]
	FICAT	24 months	35.6		NWB for 4 weeks	Radiological progress was observed in 8.0% (2/25) hips	Ma et al. [11]
	ARCO	24 months		Late Bearing	FWB allowed 6 weeks	Femoral head was collapsed in 8.6% (3/35) hips	Sen et al. [7]
	ARCO	60 months	32.7		FWB allowed 6 weeks	Femoral head was collapsed in 3.8 % (2/53) hips	Zhao et al. [8]
	Steinberg	37 months	34		PWB allowed 5 weeks. FWB is allowed 8 weeks	Radiological progress was observed in 19.3% (6/31) hips. THA was needed in 10.0% (3/30) hips	Persiani et al. [15]
	Ficat	4.8 years			PWB allowed 4 days. FWB is allowed 3 months	Radiological progress was observed in 43.6% (34/78) hips	Mao et al. [10]
	Ficat	3.6 years	36.2		PWB allowed 6 weeks	Radiological progress was observed in 72% (8/13) hips. THA was needed in 15% (2/13) hips	Chotivichit et al. [9]
		24.6 months	31.9		PWB allowed 6 months	Radiological progress was observed in 73.5% (25/34) hips	Chotivichit et al. [12]
CD +BM-MNC +Scaffold	SDIC	29 months	41	Early Bearing	PWB is allowed one week. FWB is allowed 3 weeks	Radiological progress was observed in 43.3% (13/30) hips	Yamasaki et al. [16]
	Ficat	17 months			With crutches for 2 weeks.	Radiological progress was observed in 21.0% (16/77) hips	Martin et al. [19]

	Steinberg	68 months	43.8	Late Bearing	PWB is allowed 6 weeks. FWB is allowed 12 weeks	Bad clinical results in 42.6% (26/61) hips	Kang et al. [18]
	SDIC	24 months	31.7		PWB is allowed 6 weeks. FWB is allowed 3 months	Radiological progress was observed in 20.0% (2/10) hips	Aoyama et al. [16]
	ARCO	26.7 months	38	Very Late Bearing	PWB is allowed 3 months. FWB is allowed 6 months	Radiological progress was observed in 21.4% (6/28) hips	Liu et al. [17]
	ARCO	24 months	35		PWB is allowed 3 months. FWB is allowed 6 months	Radiological progress was observed in 20.0% (4/20) hips	Wang et al. [20]

CD: Core Decompression; BM-MNCs: Bone Marrow Derived Mono Nuclear Cells; MSC: Mesenchymal Stromal Cell; ARCO: Association Research Circulation Osseous Classification System; SDIC: Specific Disease Investigation Committee Classification System; NWB: Non-Weight Bearing; PWB: Partial Weight Bearing; FWB: Full-Weight Bearing; THA: Total Hip Replacement.

Table 3: Initiation timing of weight bearing and radiological result.

CD with concentrated BM-MNCS was initially compared to CD with MSC. In the early stages (stages 1 and 2), there are two groups of initiation timing of weight bearing. In the early bearing group, the initiation timing of weight bearing is 10 days after surgery [4]. After the non-weight-bearing (NWB) period, full weight-bearing (FWB) is permitted [4]. In the late bearing group, the initiation timing of weight bearing is 6 weeks after surgery [7,8]. In the late bearing group, gradual weight bearing is also not programmed [7,8]. Factors, such as operation techniques and cell sources, between the early and later bearing types are not different. However, the collapse rates of the early bearing group (17.6% [4]) are higher than those of the late bearing type (8.6% [7] and 3.8% [8]).

When the advanced stage (stage 3) is included, the initiation timing of weight bearing is slightly delayed. Several patterns of weighting period exist in this stage. In the early bearing group, the start of FWB was allowed 2 weeks [6], 3 weeks [13], and 4 weeks [10,14] after surgery. In the late bearing group, FWB was allowed 8 weeks [20] or 3 months [11] after surgery. Although the quiet timing of FWB is unknown, the PWB timing was 6 weeks [9,12]. The collapse rates of the early bearing group (11.9% [6], 0% [13], 13.3% [14]) are lower than those of the late bearing type (19.3% [20], 43.6% [10], 72% [9], and 73.5% [12]).

In the case of surgical removal of necrotic bone and packed scaffold, weight bearing is performed more carefully. Even though the scaffold, such as cancellous bone chip or beta tricalcium phosphate, is filled in the cavity, the initial strength remains low until the transplanted cells becomes a new bone [16-21]. In one of the early bearing groups, the radiological result seems unsatisfactory (progression rate was 43.3% [16]). However, the radiological results in other reports were not different among the early, late, and very late bearing groups.

When stage 4 is included, the femoral head has already collapsed. The initiation timing of weight-bearing period is relatively late [15,18].

Muscle strength exercise

Little information is available about the protocol for muscle strength exercise. Only four articles described about muscle strength exercise (Table 1). In CD surgery, the invasion to muscle structure is relatively low [4,5]. After surgery, the patients are placed on bed rest with skin traction [8,10]. Muscle strength exercises mainly prevent disuse syndrome [8,10,15]. Water resistance exercises enable coxofemoral joint movement, strengthen the gluteus and quadriceps muscles, and prevent tendon and muscular retractions or harmful postural changes [15].

Debridement of necrotic bone results in muscular structure injury [22]. The purpose of muscle strength exercise is not only to recover muscle function, but also to promote the adaptability of the coxofemoral joint [21].

Range of motion (ROM) exercise

Little information exists about the protocol for ROM exercise (Table 1). In the early stages (stages 1 and 2), ROM is not declined, whereas in the advanced stages (stages 3 and 4), it is declined because of pain and destruction of the femoral head. In the early stages, ROM exercises are started immediately after the surgery [10]. However, in the advanced stages, these exercises are started carefully [21].

Sports and physical activity

Returning to sports or work is highly encouraged in patients. There is also little information about the timing of commencing sports and work (Table 1). In several reports, the timing of commencing sports and work are 6 months and 12 months, respectively, after surgery [10,17,21]. No clear explanation was found for the timing of initiation.

Discussion

In this review, limited information about the rehabilitation program after cell therapy for ONFH treatment was found. However, information about the timing of weight bearing was relatively described. The timing of initiation of weight bearing is important for the treatment of ONFH. Hip contact pressure is elevated to 2.5 times of body weight during weight phase [23]. Premature loading before the new bone formation worsens the disease state of ONFH. In an animal model of osteonecrosis, a 52% reduction of indentation stiffness was observed in necrotic femoral heads compared with the control heads at 2 weeks. The stiffness was recovered to 75% at 4 weeks, but reduced to 72% at 8 weeks because of femoral head collapse [24]. Kim et al. [25] used NWB in an animal model of femoral head necrosis. They succeeded in preventing the collapse of the femoral head but the bone volume decreased. The animal studies show two suggestive results. First, the initial strength of the necrotic femoral head is extremely reduced; hence initial weight bearing should be decreased. Second, only NWB cannot prevent the deformity of the femoral head. In both WB and NWB models, vascular tissues recover, but no bone structure is formed [24,25]. The lack of mechanical loading is known to cause bone loss [26]. Fluid flow, strain, and hydrostatic pressure stimulate the mechanoreceptors of osteocytes for activation [27,28]. Mechanical loading stimulates mesenchymal stromal cells to proliferate and differentiate [29-31]. Moderate loading is necessary for new bone formation. In this review, the collapse rate of the early bearing group was higher than that of the later bearing group even in the early stage (Table 3). The collapse rates of the early bearing group were lower than those of the late bearing type, when advanced stage was included (Table 3). These results suggest that careful planning of the initiation timing of weight and gradual weight bearing is required to prevent the collapse of the femoral head and stimulate bone regeneration.

The study by Kim et al. [25], which used NWB in the animal model of osteonecrosis, showed an interesting result. The femoral head was slightly collapsed even in the complete NWB group. Kim et al. [25] described that muscle contraction around the hip joint may contribute to deformity. Other models suggest that hip joint loading is a result of gravity-related weight bearing that is generated by ground reaction force and by muscular contractions across the joint [27]. Isometric hip extension and active hip flexion generate high pressure on the femoral head, equal to weight bearing and walking [32,33]. However, the pressure generated by isotonic and isokinetic exercises is less than that generated by the isometric exercise [32,33]. These results suggest that muscle strength and ROM exercise program should be planned carefully.

The peak pressure in standing up and sitting down is located at the edge of the posterior acetabulum [34]. The hydrodynamic pressure on the hip joint for bicycling is higher than that for walking [35]. In a medium-term study, femoral head collapse occurs even one year after the transplantation of bone marrow cells [36]. Appropriate instructions of ADLs and physical activities are required if favorable long-term results are to be expected.

Several instructive results in the field of basic research have been reported. Treadmill running has a synergistic effect on healing injured skeletal muscles after transplantation of muscle-derived stem cells [37,38]. Yamaguchi et al. reported that treadmill running after transplantation of bone marrow-derived MSCs can promote cartilage regeneration [39]. Some mechanical stimulations, such as ultrasound and gravity force, also promote cell differentiation and proliferation [40,41]. Biomechanical, biophysical, physiological, and radiological

knowledge are essential in designing the protocol for musculoskeletal rehabilitation. However, treatment programs for ONFH without cell therapy have not been improved since the report of Neumayr et al. [42]. Developing a rehabilitation program is important. In addition, knowledge in cell biology is necessary to promote the effect of rehabilitation after cell transplantation.

Conclusion

An unclear rehabilitation protocol after cell transplantation for ONFH treatment was found. Initial timing and intensity of weight bearing were significant factors. Information about muscle strength exercise, ROM exercise, and instructions of physical activity was poor. Further research is necessary to establish a rehabilitation protocol to promote the effect of cell transplantation.

Acknowledgement

This work was supported by grants-in-aid for scientific research from the Japan Society for the Promotion of Science, the Ministry of Education, Culture, Sports, Science, and Technology.

Conflict of Interest Statement

There are no conflicts of interest to declare.

References

1. Mankin HJ (1992) Nontraumatic necrosis of bone (osteonecrosis). *N Engl J Med* 326: 1473-1479.
2. Kaushik AP, Das A, Cui Q (2012) Osteonecrosis of the femoral head: An update in year 2012. *World J Orthop* 3: 49-57.
3. Hernigou P, Trousselier M, Roubineau F, Bouthors C, Chevallier N, et al. (2016) Stem cell therapy for the treatment of hip osteonecrosis: A 30-year review of progress. *Clin Orthop Surg* 8: 1-8.
4. Hernigou P, Poignard A, Zilber S, Rouard H (2009) Cell therapy of hip osteonecrosis with autologous bone marrow grafting. *Indian J Orthop* 43: 40-45.
5. Gangji V, Hauzeur JP, Matos C, De Maertelaer V, Tounouz M, et al. (2004) Treatment of osteonecrosis of the femoral head with implantation of autologous bone-marrow cells: A pilot study. *J Bone Joint Surg Am* 86: 1153-1160.
6. Wang BL, Sun W, Shi ZC, Zhang NF, Yue DB, et al. (2010) Treatment of nontraumatic osteonecrosis of the femoral head with the implantation of core decompression and concentrated autologous bone marrow containing mononuclear cells. *Arch Orthop Trauma Surg* 130: 859-865.
7. Sen RK, Tripathy SK, Aggarwal S, Marwaha N, Sharma RR, et al. (2012) Early results of core decompression and autologous bone marrow mononuclear cells instillation in femoral head osteonecrosis: A randomized control study. *J Arthroplasty* 27: 679-686.
8. Zhao D, Cui D, Wang B, Tian F, Guo L, et al. (2012) Treatment of early stage osteonecrosis of the femoral head with autologous implantation of bone marrow-derived and cultured mesenchymal stem cells. *Bone* 50: 325-330.
9. Chotivichit A, Korwutthikulrangsri E, Auewarakul C, Sarirasirid S (2012) Core decompression and concentrated autologous bone marrow injection for treatment of osteonecrosis of the femoral head. *J Med Assoc Thai* 95: S14-S20.
10. Mao Q, Wang W, Xu T, Zhang S, Xiao L, et al. (2015) Combination treatment of biomechanical support and targeted intra-arterial infusion of peripheral blood stem cells mobilized by granulocyte-colony stimulating factor for the osteonecrosis of the femoral head: A randomized controlled clinical trial. *J Bone Miner Res* 30: 647-656.

11. Ma Y, Wang T, Liao J, Gu H, Lin X, et al. (2014) Efficacy of autologous bone marrow buffy coat grafting combined with core decompression in patients with avascular necrosis of femoral head: A prospective, double-blinded, randomized, controlled study. *Stem Cell Res Ther* 5: 115.
12. Chotivichit A, Korwutthikulrangsri E, Pornrattanamaneewong C, Achawakulthep C (2014) Core decompression with bone marrow injection for the treatment of femoral head osteonecrosis. *J Med Assoc Thai* 97: S139-S143.
13. Tabatabaee RM, Saberi S, Parvizi J, Mortazavi SM, Farzan M (2015) Combining concentrated autologous bone marrow stem cells injection with core decompression improves outcome for patients with early-stage osteonecrosis of the femoral head: A comparative study. *J Arthroplasty* 30: 11-15.
14. Rastogi S, Sankineani SR, Nag HL, Mohanty S, Shivanand G, et al. (2013) Intraleisional autologous mesenchymal stem cells in management of osteonecrosis of femur: A preliminary study. *Musculoskelet Surg* 97: 223-228.
15. Persiani P, De Cristo C, Graci J, Noia G, Gurzi M, et al. (2015) Stage-related results in treatment of hip osteonecrosis with core-decompression and autologous mesenchymal stem cells. *Acta Orthop Belg* 81: 406-412.
16. Yamasaki T, Yasunaga Y, Ishikawa M, Hamaki T, Ochi M (2010) Bone-marrow-derived mononuclear cells with a porous hydroxyapatite scaffold for the treatment of osteonecrosis of the femoral head: A preliminary study. *J Bone Joint Surg Br* 92: 337-341.
17. Liu Y, Liu S, Su X (2013) Core decompression and implantation of bone marrow mononuclear cells with porous hydroxylapatite composite filler for the treatment of osteonecrosis of the femoral head. *Arch Orthop Trauma Surg* 133: 125-133.
18. Kang JS, Moon KH, Kim BS, Kwon DG, Shin SH, et al. (2013) Clinical results of auto-iliac cancellous bone grafts combined with implantation of autologous bone marrow cells for osteonecrosis of the femoral head: A minimum 5-year follow-up. *Yonsei Med J* 54: 510-515.
19. Martin JR, Houdek MT, Sierra RJ (2013) Use of concentrated bone marrow aspirate and platelet rich plasma during minimally invasive decompression of the femoral head in the treatment of osteonecrosis. *Croat Med J* 54: 219-224.
20. Wang T, Wang W, Yin ZS (2014) Treatment of osteonecrosis of the femoral head with thorough debridement, bone grafting and bone-marrow mononuclear cells implantation. *Eur J Orthop Surg Traumatol* 24: 197-202.
21. Aoyama T, Fujita Y, Madoba K, Nankaku M, Yamada M, et al. (2015) Rehabilitation program after mesenchymal stromal cell transplantation augmented by vascularized bone grafts for idiopathic osteonecrosis of the femoral head: A preliminary study. *Arch Phys Med Rehabil* 96: 532-539.
22. Aoyama T, Goto K, Kakinoki R, Ikeguchi R, Ueda M, et al. (2014) An exploratory clinical trial for idiopathic osteonecrosis of femoral head by cultured autologous multipotent mesenchymal stromal cells augmented with vascularized bone grafts. *Tissue Eng Part B Rev* 20: 233-242.
23. Heller MO, Bergmann G, Deuretzbacher G, Dürselen L, Pohl M, et al. (2001) Musculo-skeletal loading conditions at the hip during walking and stair climbing. *J Biomech* 34: 883-893.
24. Pringle D, Koob TJ, Kim HK (2004) Indentation properties of growing femoral head following ischemic necrosis. *J Orthop Res* 22: 122-130.
25. Kim HK, Aruwajoye O, Stetler J, Stall A (2012) Effects of non-weight-bearing on the immature femoral head following ischemic osteonecrosis: An experimental investigation in immature pigs. *J Bone Joint Surg Am* 94: 2228-2237.
26. Fritton SP, Weinbaum S (2009) Fluid and solute transport in bone: Flow-induced mechanotransduction. *Annu Rev Fluid Mech* 41: 347-374.
27. Klein-Nulend J, van der Plas A, Semeins CM, Ajubi NE, Frangos JA, et al. (1995) Sensitivity of osteocytes to biomechanical stress in vitro. *FASEB J* 9: 441-445.
28. Burgers TA, Williams BO (2013) Regulation of Wnt/ β -catenin signaling within and from osteocytes. *Bone* 54: 244-249.
29. Sen B, Xie Z, Case N, Styner M, Rubin CT, et al. (2011) Mechanical signal influence on mesenchymal stem cell fate is enhanced by incorporation of refractory periods into the loading regimen. *J Biomech* 44: 593-599.
30. Sen B, Guilluy C, Xie Z, Case N, Styner M, et al. (2011) Mechanically induced focal adhesion assembly amplifies anti-adipogenic pathways in mesenchymal stem cells. *Stem Cells* 29: 1829-1836.
31. Li YJ, Batra NN, You L, Meier SC, Coe IA, et al. (2004) Oscillatory fluid flow affects human marrow stromal cell proliferation and differentiation. *J Orthop Res* 22: 1283-1289.
32. Strickland EM, Fares M, Krebs DE, Riley PO, Givens-Heiss DL, et al. (1992) In vivo acetabular contact pressures during rehabilitation, Part I: Acute phase. *Phys Ther* 72: 691-699.
33. Krebs DE, Elbaum L, Riley PO, Hodge WA, Mann RW (1991) Exercise and gait effects on in vivo hip contact pressures. *Phys Ther* 71: 301-309.
34. Yoshida H, Faust A, Wilckens J, Kitagawa M, Fetto J, et al. (2006) Three-dimensional dynamic hip contact area and pressure distribution during activities of daily living. *J Biomech* 39: 1996-2004.
35. Meyer DM, Tichy JA (2003) 3-D model of a total hip replacement in vivo providing hydrodynamic pressure and film thickness for walking and bicycling. *J Biomech Eng* 125: 777-784.
36. Gangji V, De Maertelaer V, Hauzeur JP (2011) Autologous bone marrow cell implantation in the treatment of non-traumatic osteonecrosis of the femoral head: Five year follow-up of a prospective controlled study. *Bone* 49: 1005-1009.
37. Ambrosio F, Miceli G, Pasquarello A (2015) Redox levels in aqueous solution: Effect of van der Waals interactions and hybrid functionals. *J Chem Phys* 143: 244508.
38. Ambrosio F, Ferrari RJ, Distefano G, Plassmeyer JM, Carvell GE, et al. (2010) The synergistic effect of treadmill running on stem-cell transplantation to heal injured skeletal muscle. *Tissue Eng Part A* 16: 839-849.
39. Yamaguchi S, Aoyama T, Ito A, Nagai M, Iijima H, et al. (2016) The effect of exercise on the early stages of mesenchymal stromal cell-induced cartilage repair in a rat osteochondral defect model. *PLoS One* 11: e0151580.
40. Ito A, Aoyama T, Yamaguchi S, Zhang X, Akiyama H, et al. (2012) Low-intensity pulsed ultrasound inhibits messenger RNA expression of matrix metalloproteinase-13 induced by interleukin-1 β in chondrocytes in an intensity-dependent manner. *Ultrasound Med Biol* 38: 1726-1733.
41. Tajino J, Ito A, Nagai M, Zhang X, Yamaguchi S, et al. (2015) Intermittent application of hypergravity by centrifugation attenuates disruption of rat gait induced by 2 weeks of simulated microgravity. *Behav Brain Res* 287: 276-284.
42. Neumayr LD, Aguilar C, Earles AN, Jergesen HE, Haberkern CM, et al. (2006) Physical therapy alone compared with core decompression and physical therapy for femoral head osteonecrosis in sickle cell disease. Results of a multicenter study at a mean of three years after treatment. *J Bone Joint Surg Am* 88: 2573-2582.