

Rehabilitation of Organophosphate Induced Delayed Polyneuropathy

Pabitra Kumar Sahoo*, Faiz Mohamed, Mamata Manjari Sahu and Shankar Ganesh

Department of Physical Medicine & Rehabilitation, Swami Vivekanand National Institute of Rehabilitation, India

*Corresponding author: Pabitra Kumar Sahoo, Department of Physical Medicine & Rehabilitation, Swami Vivekanand National Institute of Rehabilitation, India, Tel: +91-9437081993; E-mail: pabitra2406@gmail.com

Received date: July 12, 2018; Accepted date: September 14, 2018; Published date: September 18, 2018

Copyright: ©2018 Sahoo PK, et al. This is an open-access article distributed under the terms of the Creative Commons Attribution License, which permits unrestricted use, distribution, and reproduction in any medium, provided the original author and source are credited.

Abstract

Background: Accidental exposure and suicidal attempts using large toxic doses of organophosphorus cause acute necrotic neuronal cell death in the brain leading to death of individual whereas sublethal or subclinical dose produce apoptotic neuronal cell death and involve oxidative stress. Patients survived of the acute cholinergic crisis develop organophosphate induced polyneuropathy (OPIDN) 1-5 weeks after exposure. Besides the treatment for the acute phase, no specific treatment exists to prevent occurrence of OPIDN following exposure. There is paucity of literature on rehabilitation of OPIDN conditions.

Methods: Long term follow up of 3 cases presenting with features of OPIDN are included in the study. On admission the clinical and functional assessment was done using Overall Neuropathy Limitation Scale (ONLS). A comprehensive rehabilitation management was done.

Results: There was significant improvement of ONLS score ($p = .000$) with functional improvement in all the cases. Hand functions were almost recovered to near normal. Community ambulation was possible with orthosis.

Conclusion: The long-term study of our OPIDN cases showed remarkable rehabilitation potential. All our cases are ambulatory with orthosis and integrated to community socially as well as vocationally.

Keywords: Polyneuropathy; Cholinergic crisis; Organophosphate

Introduction

Organophosphorus (OP) poisoning is the most commonly used poison for suicide in India accounting for almost 50% of hospital admission due to poisoning [1]. Accidental and occupational exposure leading to poisoning also observed occasionally. It produces three distinct neurological complications. The first and immediate lethal complication is acute cholinergic crisis leading to death most of the times. The second is the intermediate syndrome which may occur after 1-4 days if the patient survives of the first stage. This stage involves bulbar, ocular, neck, proximal limb, and respiratory muscle, that is usually reversible. This may be because of functionally down-regulated acetylcholine receptors due to heavy activation by excessively accumulated acetylcholine esterase leading to their premature endocytosis [2]. Organophosphate induced delayed neuropathy (OPIDN) is the third stage which occurs 1-5 weeks after exposure. The OPIDN is a rare neurodegenerative complication of OP ingestion as currently used organophosphates have potent cholinergic activity leading to death. The disorder is characterized by distal degeneration of long and large diameter axons in peripheral nerve and spinal cord [3]. On the appearance of clinical signs of OPIDN, axonal swelling occurs with aggregation of neurofilaments, the proliferation of endoplasmic reticulum and multivesicular vesicles and after that gradual disappearance of neurofilaments [3]. There is a functional loss of the distal sensory and motor axons of peripheral nerves and also affects the central nervous system involving pyramidal tract and posterior column of the spinal cord. The gradual increase of muscle tone and motor impairment affecting the distal part of extremities are

the prominent features of this condition. Sensory impairment may be present but is less severe than the motor involvement. Besides the treatment for the acute phase, no specific treatment exists to prevent the occurrence of OPIDN following exposure [2]. Role of a physical medicine and rehabilitation specialist is substantial in all the stages starting from mechanical ventilation in early intensive care to functional independence and early integration into the community [4].

The literature on OPIDN following OP poisoning are limited and only sporadic case presentations are available with a limited follow-up period. There is still a literature gap on the rehabilitation aspect of OPIDN condition. Here we present a series of three cases presented with features of OPIDN and their rehabilitative management with long-term follow-up.

Material and Method

3 patients with OPIDN were admitted to our Physical Medicine and rehabilitation department from December 2013 to July 2017. 2 were male and one was female. 2 patients had tried to commit suicide by consumptions of organophosphorus pesticide and one had accidental ingestion of organophosphorus in a paddy field while working on a defective pesticide sprayer. Immediately after exposure, all the patients were managed for their acute condition of cholinergic crisis in intensive care Units of tertiary medical setups. Investigations like CSF study, EMG, Serum choline esterase estimation was done in all the cases at the primary treating hospital. All the patients had a similar electrophysiological finding in their EMG study which shows an absence of compound muscle action potential (CMAP) in distal muscles of lower limbs and diminished CMAPs in the upper limb. Sensory nerve action potential was normal in all the limbs. These

findings are suggestive of pure motor axonal neuropathy. After management of 1st stage and intermediate stage, they were referred for rehabilitation of OPIDN condition. The clinical and functional

assessment was done at their admission using Overall Neuropathy Limitation Scale (ONLS) [10] (Table 1).

Arm grade
0 = Normal
1 = Minor symptoms in one or both arm but not affecting any of the functions listed
2 = Disability in one or both arms affecting but not preventing any of the functions listed
3 = Disability in one or both arm preventing at least one but not all functions listed
4 = Disability in both arms preventing all functions listed but purposeful movements still possible
5 = Disability in both arms preventing all purposeful movements
Leg grade
0 = Walking/climbing stairs/running not affected
1 = Walking/climbing stairs/running is affected but gait does not look abnormal
2 = Walks independently but gait looks abnormal
3 = Requires unilateral support to walk 10 metres (stick, single crutch, one arm)
4 = Requires bilateral support to walk 10 metres (sticks, crutches, crutch and arm, frame)
5 = Requires wheelchair to travel 10 metres but able to stand and walk 1 metre with the help of one person.
6 = Restricted to wheel chair, unable to stand and walk 1 metre with the help of one person
7 = Restricted to wheel chair or bed most of the day, unable to make any purposeful movements of the legs.

Table 1: Overall Neuropathy Limitation Scale (ONLS).

All the patients had undergone intensive inpatient condition based rehabilitation programs. The therapeutic program was aimed at prevention of neuromusculoskeletal comorbidities. Protocol of therapy includes stretching of spastic contracted muscles, strengthening and proprioceptive neuromuscular facilitation of weak muscles, and intermittent stimulation with galvanic current to paralyzed distal muscles of lower and upper extremities. Patients with mild spasticity were managed by applying a cold pack to the affected group of muscles. Medical management involved chiefly of spasticity control by oral baclofen with a starting dose of 10 mg to 40 mg per day. One patient with uncontrolled adductor spasticity was managed by Botulinum Toxin A injection to hip adductors at a dose of 100 units to adductor magus and 100 units to adductor longus. The third patient had mild gastrosoleus tightness which was corrected with serial plaster casting for three times. Tilt table supported standing with a gradual increase of duration helps to prevent the effect of prolonged bed lying postural hypotension. They were reassessed again on their subsequent follow up using the same assessment scales. The details of individual cases were as follows.

Case 1

A 45 years male had accidental organophosphorus pesticide ingestion while working on a defective pesticide spraying machine in a paddy field in December 2015. Suddenly he became unconscious and was admitted to the intensive care unit of the nearest hospital where he was managed for OP poisoning and his vital parameters were monitored. He was discharged from ICU after 6 days. After 15 days he

regains consciousness but his cognition was fair, the speech was slurred, unable to swallow solid food. Functionally rolling on the bed and sitting balance was absent, all the 4 limbs were spastic with MAS2, dependent for all ADL activities, claw deformity of both the hand. The bladder was under an indwelling catheter which was removed after 3 weeks on the return of voluntary control. However sensory impairment was not marked. He was under the home exercise program for 4 months because of social and financial issues.

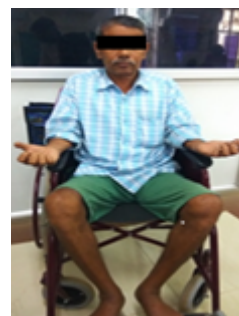

Figure 1: Showing patient on 1st follow up.

On 1st follow up after 6 months of exposure, higher mental function and speech was normal. He had weakness of all the four limbs with poor sitting balance, dependant on all ADL activities. Spasticity in the upper limb was MAS 1+ and lower limb MAS2. All the deep tendon

reflexes of upper and lower limb were exaggerated. Babinski sign was bilateral up-going. Bladder, bowel and sensory impairments were fully recovered. Claw hand deformity, equinus foot deformity, and hamstring tightness were stretchable (Figure 1).

The patient was put into institutional based rehabilitation protocol with a goal setting of prevention and correction of deformities, achieving both static and dynamic sitting balance, transfer activities, supported standing. Most of the goals were achieved after 6 weeks of therapy except standing balance. Before discharge, the clinical and functional level of the patient was assessed using ONLS scoring. The home exercise program was demonstrated.

On 2nd follow up after 2 years of exposure to OP poisoning, his higher function was normal. Upper limb was completely recovered and independent of all his upper limb activities. For lower limb, his neurological motor level regressed to L3 but the sensation was intact. Muscle tone on both lower limbs MAS1 with exaggeration of all the tendon reflexes except ankle jerk which was diminished. Babinski sign was bilateral non-responsive. He was able to stand with maximal support. Readmission was done for a course of therapy with goal setting for improving sit to stand, standing balance and supported walking. After 6 weeks of therapy, his balance was improved and was advised for supported walking with Polypropylene Knee ankle foot orthosis (KAFO) and a pair of sandals (Figure 2) assisted with a walking aid. Post-intervention ONLS scoring was done before discharge.

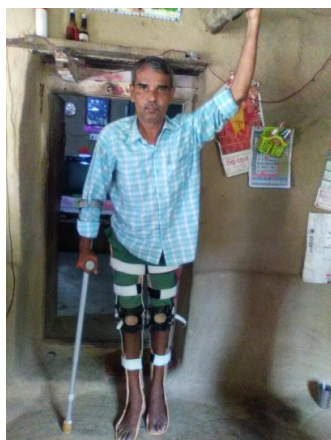

Figure 2: After 6 weeks of therapy, patient balance was improved and was advised for supported walking.

Case 2

A 28 years male (Figure 3) had a suicidal attempt consuming organophosphorus pesticide in September 2013. He was primarily managed at a nearby hospital for 1st stage of the cholinergic crisis and for intermediate stage. He developed weakness of all 4 limbs but upper limbs were less affected than lower limbs. After his vital conditions became stable and recovered from his cognitive deficiencies, he was reported after 2 months for rehabilitative management.

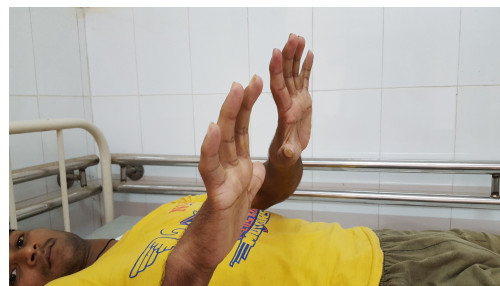

Figure 3: Showing 28 years male.

On admission at 1st follow up, his higher mental function was normal without any visual and speech impairment. Ambulation was assisted with a wheelchair. Atrophy of muscles of both lower limbs and upper limbs especially small muscles of the hand (Figure 3). Muscle tone upper limbs MAS 1 and lower limb MAS2. Deep tendon reflexes of lower limbs were exaggerated and Babinski sign showed planter up going. There was the tightness of gastrosoleus and hamstring group of muscles which were stretchable to neutral. Besides the bilateral equinovarus deformity he did not have any other deformity. His static sitting balance was good but the dynamic sitting balance was poor.

On the assessment of hand function, initiation and reach were good. Cylindrical, spherical, hook grasp was fair. Lateral pinch and tip to tip pinch were poor. Activities of daily living using the upper limb required minimal assistance and ambulation is assistive with a wheelchair. As a part of institutional based rehabilitation, goal setting was done, and therapy was directed towards improvement of hand function, self-propelling of a wheelchair, and prevention of development of fixed deformity in the lower limb.

Follow up after 3 and ½ years, his upper limb and hand function were completely recovered. No sensory impairment. Persisting lower limb weakness with MRC grading of muscles around Hip 4, muscles around knee 3 and around the ankle was 2. Spasticity of muscles of lower limb MAS 1+. There was no fixed deformity and was walking with maximal support. Rehabilitation protocol and goal setting were done with a course of therapy including stretching, strengthening exercises, ADL training, MAT activities, and Neurodevelopmental therapy. Functional walking was tried with use of Supracondylar Knee Ankle Foot Orthosis (SKAFO). As a part of social rehabilitation, counseling sessions were fixed and suggested for participating vocational training of our Rehabilitation Department.

Case 3

A 27 years Female presented with the history of suicidal attempt taking organophosphorus poison on March 2016. She was primarily treated at nearby medical college. After recovery from acute cholinergic crisis condition, she developed weakness of all the four limbs predominantly affecting the distal part of the limbs. Sensations were impaired. She was diagnosed as OPIDN and referred for further rehabilitation management. On admission, her higher function was normal. No sensory impairment marked. Muscle tone in upper limb MAS1, and lower limb MAS2. Biceps and triceps jerk brisk, Knee jerk exaggerated, Ankle and supinator jerk not elicitable. Trunk Muscle power was normal. Except for hip flexors, all the muscles of lower limb had power MRC grading 2 or less. Muscle power around the shoulder

and elbow MRC grade 4 and power of wrist extensor, small muscles of hand were MRC grade 2. On assessment of hand activities, initiation and reach present, spherical cylindrical and hook grasp were fair. Except eating with a spoon, she was dependent for all activities of daily living. There was tightness of hip flexors, hamstrings, and gastrosoleus. The static sitting balance was good, dynamic balance was fair. Her bladder and bowel function was intact. Rehabilitation protocol was planned to aim for improvement of wheelchair transfer, dynamic balance of sitting, standing endurance using tilt table, stretching, strengthening of muscles of the lower limb and task-oriented activities. Counseling sessions were arranged both for parents and the patient.

Follow up of after 8 weeks of therapy in the rehabilitation unit, her muscle power and balance was improved considerably. Gait training was done with the use of bilateral Knee Ankle Foot Orthosis (KAFO) with a pair of an axillary crutch. 2nd follow up after 7 months, she had complete recovery of hand functions and independent of ADL with respect to the upper limb. Her quadriceps power recovered to MRC grade 4, dorsiflexors of ankle grade 2. Community ambulation was possible with use of bilateral Ankle foot orthosis assisted with an elbow crutch.

Results

Mobility and functional evaluation were done using Overall Neuropathy Limitation Scale (ONLS) score on each visit (Table 2). The ONLS is a scale that measures the limitation in the everyday activities of the upper limb and lower limb [10]. Hand functions for different activities of daily living and leg function for climbing stairs, surface walking, walking with different levels of walking aids or use of ankle foot orthosis, 10 meters walk test, were graded into Arm grade and leg grade respectively. The serial changes as limitations in arm grade and leg grade were objectified using ONLS score. All the patients have significant improvement in ONLS score adopting a comprehensive rehabilitation protocol. Hand function was recovered to near normal. Residual deficit persists in lower limb in all the patients (Figure 4). Community ambulation was possible with the use of Knee Ankle Foot Orthosis (KAFO) or Ankle Foot Orthosis (AFO), assisted with elbow crutch or walking stick.

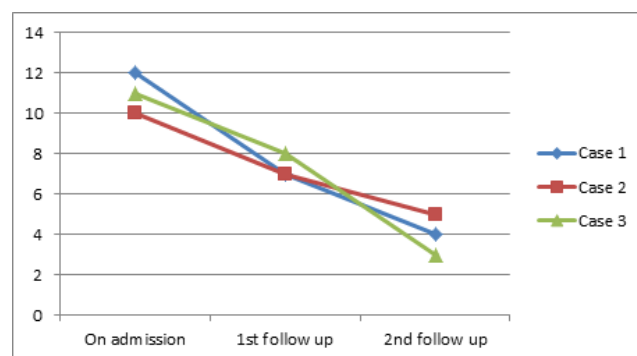
Case 1	On Admission	1 st Follow up	2 nd Follow up
ONLS Arm Grade	5	2	0
ONLS Leg grade	7	5	4
Total ONLS	12	7	4
Case -2			
ONLS Arm grade	4	2	1
ONLS Leg grade	6	5	4
TotalONLS	10	7	5
Case-3			
ONLS Arm grade	4	3	0
ONLS Leg grade	7	5	3
Total ONLS	11	8	3

Table 2: Result profile.

Statistics: Statistical analysis was done with the Friedman test (NPar) using SPSS software. There was a statistically significant difference in overall functional improvement among the patients and in their subsequent follow up of rehabilitative management [$X^2(2)=17.176$, $p=0.000$]. The mean Rank of arm, leg, and the total score was 1.00, 2.11 and 2.89 respectively.

Chi-Square	17.176
df	2
Asymp. Sig.	0

Table 3: Friedman Test Statistics.



Discussion

The mechanism of development of OPIDN is inhibition of neuropathic target esterase (NTE) *via* phosphorylation. NTE is an

integrated membrane protein, important for axonal maintenance. Clinical manifestation of OPIDN depends on sources of NTE inhibited. Inhibition of spinal cord NTE results in spastic spinal cord syndrome whereas inhibition of NTE of peripheral nerve results in flaccid paralysis typical of polyneuropathy [6]. Although phosphorylation of NTE occurs immediately after OP exposure, it takes 1-3 weeks for OPIDN to develop. The reason for this delay is not cleared [6]. Most of the authors have shown the onset of features of OPIDN toward the 6th week of exposure [7], but in all our cases, symptoms are established at the end of 3rd week. Some report correlates the volume of OP consumption with OPIDN clinical manifestations, which is not observed in our study. OPIDN is observed in certain susceptible individuals even with OP inhalation [8]. Some patients present with predominant central nervous system involvement. This might be because of wallerian degeneration from diffuse cortical neuron death in certain individuals [8]. Clinical involvement of the corticospinal tract and posterior column become apparent when the peripheral neuropathy improves [11]. All the patients in our series had shown features of pyramidal tract involvement. Recurrent laryngeal nerve axonopathy, although rare can lead to vocal cord paralysis and that requires to prolong rehabilitation [2,4]. In our series, vocal cord paralysis was noticed in one case. Intrinsic muscle involvement, wrist drop are the prominent features in upper extremity [7], also marked in our series. Prognosis of OPIDN depends upon the age of the patient, persistence of myelopathic features, and degree of CNS involvement in peripheral nerve dysfunction [9]. All our patients have shown mixed features but intense spasticity around proximal joints of lower limb masks all other findings. By the time there is a regeneration of peripheral nerves, signs of CNS involvement are predominant [6].

Though OPIDN is an uncommon condition, drawing of a conclusion from a series of 3 cases is the limitation of this study. Further study with more number of case and long-term follow up is required to establish the rehabilitation outcome of this condition.

Conclusion

Organophosphate induced delayed polyneuropathy is a delayed complication seen in a survived patient with OP poisoning. Susceptibility, presentation, and outcomes are not uniform in all the cases across the literature. More research is required to find out the cause of delayed onset and target specific tissue involvement. So far no

specific treatment has been identified. The long-term study of our OPIDN cases showed remarkable rehabilitation potential. Rehabilitation management plays a substantial role in making the patients functionally independent. All our cases are ambulatory with orthosis and integrated to community socially as well as vocationally.

Conflict of Interest

No potential conflict of interest related to this article. Consent has been taken from the patients to publish their photographs.

References

1. Singh S, Sharma N (2000) Neurological complications following organophosphate poisoning. *Neurol* 48: 308-313.
2. Chattergy M, Sharma P (2003) Unusual complications in a case of organophosphate poisoning. *Neurol* 51: 290-291.
3. Masoud A, Sandhir R (2012) Increased oxidative stress is associated with the development of organophosphate-induced delayed neuropathy. *Hum Exp Toxicol* 31: 1214-1227.
4. Shetye JV, Swati M, Karnik ND, Mehta A (2014) Delayed onset neuropathy along with recurrent laryngeal nerve palsy due to organophosphate poisoning and role of physiotherapy rehabilitation. *Indian J Crit Care Med* 18: 102-104.
5. Singh S, Ranjit A, Parthasarathy S et al. Organophosphate induced delayed neuropathy: report of two cases. *Neurol India* 52: 524-525.
6. Yalbuздag S, Ince B, Kaya T (2017) Organophosphate induced delayed neuropathy- A case report. *Turk J Phys Med Rehab* 63: 88-91.
7. Jokanovic M, Kosanovic M, Brkic D (2011) Organophosphate induced played polyneuropathy in man: An overview. *Clin Neurology Neurosurg* 113: 7-10.
8. Wang J, Shao Y, Shi K, Yang H (2015) Restricted diffusion in the splenium of the corpus callosum in organophosphate-induced delayed neuropathy: Case report and review kinds of literature. *Int J Clin Exp Med* 8: 14246-14250.
9. Thivakaran T, Gamage R, Gooneratne IK (2012) Chlorpyrifos induced delayed myelopathy and pure motor neuropathy: A case report. *Neurologist* 18: 226-228.
10. Graham RC, Hughes RA (2006) A modified peripheral neuropathy scale: The Overall Neuropathy Limitation Scale. *J Neurol Neurosurg Psychiatry* 77: 973-976.
11. Nand N, Aggarwal HK, Bhatti K, Chakrabarti D (2007) Organophosphate induced delayed neuropathy. *J Assoc Physicians India* 55: 72 -73.