

Refractory Hypocalcemia Effectively Treated with Steroids in Prostate Cancer Metastatic to Bone

Nicole Gebara¹, Chadia Beaini², Fadi El Karak³ and Georges Hajje^{4*}

¹Departments of Medicine, Bellevue Medical Center, Saint Joseph University, Beirut, Lebanon

²Department of Nephrology, Bellevue Medical Center, Saint Joseph University, Beirut, Lebanon

³Department of Oncology, Bellevue Medical Center, Saint Joseph University, Beirut, Lebanon

⁴Department of Endocrinology, Bellevue Medical Center, Saint Joseph University, Beirut, Lebanon

Received date: June 15, 2017; Accepted date: July 6, 2017; Published date: July 30, 2017

*Corresponding author: Georges Hajje, Department of Nuclear Medicine and Endocrine Tumors, Bellevue medical center, Saint Joseph University, Beirut Lebanon, Tel: 009613238449; E-mail: hajjgeorges@hotmail.com

Copyright: © 2017 Gebara N, et al. This is an open-access article distributed under the terms of the Creative Commons Attribution License, which permits unrestricted use, distribution, and reproduction in any medium, provided the original author and source are credited.

Introduction

Prostate cancer is the most common cancer in men and the second most common cause of cancer related death in men [1]. Patients with metastatic prostate cancer to bones have hypocalcemia in 30% of cases [2]. True symptomatic hypocalcemia based on the serum ionized calcium level is rare and reported in only 2% of cases [3]. We will be reporting a case of prostate cancer patient with bone metastases who presented with severe symptomatic refractory hypocalcemia.

Case Summary

A 71 year old patient, with no previous medical or surgical history, was diagnosed in 2009 with stage III prostate cancer. He was treated with combination of hormonal blockade from 2009 till 2012 (Triptorelin Acetate: 1 injection every three months) and radiation (72 Gy). He was then in remission until November 2016 when he was admitted to the Intensive Care Unit for confusion, general weakness, icterus, dark urine and clear stools. Clinical examination revealed an icteric sclera and a hepatosplenomegaly. His blood tests at the initial assessment revealed a severe hypocalcemia (Calcium (Ca)=4.8 mg/dl, albumin=2.91 g/dL, corrected calcium level=5.67 mg/dl) with a perturbation of the liver function tests (LFT's) mainly as cholestasis (Alanine transaminase (ALAT)=116 U/L, Aspartate aminotransferase (ASAT)= 163 U/L, Alkaline Phosphatase (ALP)=2868 U/L, Gamma-Glutamyl Transferase (GGT)=2977 U/L, Total Bilirubin=10.94 mg/dl, direct bilirubin=9.92 mg/dl). His Prostate-specific antigen (PSA) level was high (34.49 ng/ml), his serum creatinin and his Magnesium level were normal. The abdomen and pelvis MRI revealed a prostatic gland around 30 g with signs suggestive of scarring post radiotherapy, large iliac lymphadenopathy and diffuse metastatic infiltration of the pelvic bone and the lower lumbar spine.

A CT guided biopsy of the iliac bone lesion showed metastatic deposits of a poorly differentiated adenocarcinoma consistent with a prostate origin. The patient was started on hormone therapy (2 injections of degarelix acetate) and he received one cycle of chemotherapy (Docetaxel 60 mg/m²).

The complete workup of hypocalcemia revealed an elevated parathyroid hormone (PTH=97.26 pg/ml) and low vitamin D (8.42 ng/ml) levels. The initial treatment of the hypocalcemia was based on intravenous (IV) calcium gluconate 2 g every 6 hours, calcium tablets 600 mg every 12 hours per os, 10000 U of vitamin D per os daily and intravenous magnesium sulfate (MgSO₄) 1 g daily. Three days later, the calcemia level increased by only 0.5 mg/dl when calcitriol 1 µg per day

was added. The IV calcium gluconate dose was increased progressively until reaching 2 g every 4 hours, the calcium per os dose was increased to 1200 mg every 8 hours and the calcitriol to 2 µg per day with only mild improvement of the calcium level. The maximum corrected calcium level reached 6.9 mg/dl. While trying to decrease the doses, the calcemia decreased the next day to 5.7 mg/dl. After one week of abnormal and refractory hypocalcemia despite the administration of high doses of calcium and vitamin D, 1 mg/kg of steroids were initiated. He received 60 mg IV daily of Solumedrol. The day after, the corrected calcium level increased to 7.3 mg/dl and normalized after 2 days (Figure 1).

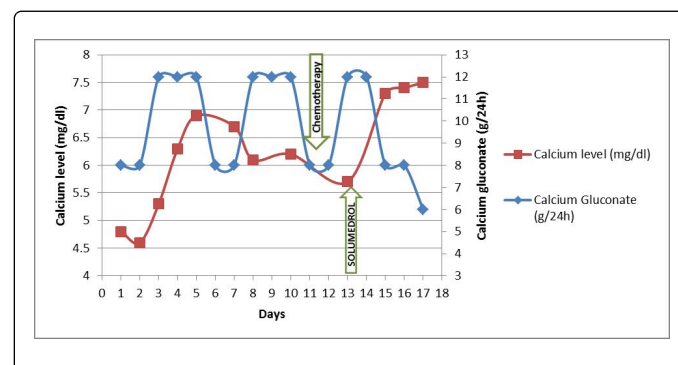


Figure 1: Evolution of calcium level regarding the dose of intravenous calcium gluconate.

The Solumedrol was continued for 7 days then tapered progressively and stopped. The calcitriol, the IV calcium gluconate and the IV MgSO₄ were also decreased progressively then stopped and the calcemia remained normal. Upon discharge the corrected calcium was 8.9 mg/dl with only 6 tablets per day of calcium 600 mg per os. Three weeks later, the corrected calcemia was 9.5 mg/dl and the calcium per os was decreased to 3 tablets per day.

Concerning the cholestasis, the history of the patient did not reveal any past episode of jaundice, nor any excess alcohol abuse or blood transfusion or recent travel abroad. There was no infection. The imaging (ultrasound and MRI) did not reveal any obstruction of the liver ducts neither liver metastasis. His liver enzymes dropped down progressively after the initiation of the hormonal treatment and the chemotherapy until reaching slightly higher normal levels upon discharge (ALAT=55 U/L, ASAT=39 U/L, ALP=661 U/L, Total Bilirubin=1.27 mg/dl, direct bilirubin=0.86 mg/dl, GGT=515 U/L).

Discussion

We report here a rare case of severe symptomatic hypocalcemia responding to steroids therapy in a patient with prostate cancer and bone metastases.

Hypocalcemia is a known condition in patients with prostatic carcinoma and bone metastases [4]. Bone metastases from prostate cancer are predominantly blastic and commonly cause decreased serum calcium level as calcium ions are transferred from serum into blastic bone leading to increased serum levels of parathyroid hormone (PTH). Osteoblastic metastases have been reported to be associated with hypocalcemia in patients with breast carcinoma and prostate cancer [3-6]. However, severe hypocalcemia remains rare in such patients. It is usually mild and clinical signs are rare. In a study of 112 patients with metastatic prostate cancer, only 0.9% of the patients were actually found to have symptomatic hypocalcemia although cases of severe hypocalcemia have also occasionally been reported [3,6-10]

The mechanism responsible of the hypocalcemia in prostate cancer metastatic to bones is not well defined. The most probable cause is the calcium uptake by the osteoblastic metastasis leading to hypocalcemia [2,3,11]. Another common etiology of hypocalcemia in malignant diseases is vitamin D deficiency associated with the malignant state. Rare reported causes of hypocalcemia in cancer are hypoparathyroidism due to destruction of parathyroid glands by metastases from a breast carcinoma [5,12], severe hypomagnesemia due to paraneoplastic renal loss of magnesium described in ovarian carcinoma [13], renal impairment or a tumor lysis syndrome following the use of various chemotherapeutic agents [14].

In our patient, the extensive metastatic bone lesions and the subsequent rapid disease progression played a central role in the pathophysiology of the hypocalcemia by the increased utilization of calcium by the avid osteoblastic metastases in addition to the vitamin D deficiency.

The clinical signs of hypocalcemia vary according to its severity and chronicity [15] ranging from mild to life-threatening manifestations such as seizures, refractory heart failure, or laryngospasm. Our patient had a severe hypocalcemia leading to confusion and general weakness. The aim of the acute management isn't only to return the serum calcium to the normal level but rather to ameliorate the acute manifestations of hypocalcemia [16] which have a direct impact on patient's daily life. Some studies concluded that moderate hypocalcemia has an increased incidence of mortality compared to mild hypocalcemia [17]. Moreover, a large retrospective study showed that calcium supplementation during the ICU stay improved 28-day survival in critically ill adult patients [18].

In this case, treating the refractory hypocalcemia was challenging, especially that – to our knowledge – there is no other case discussing refractory hypocalcemia in metastatic prostate cancer. A multidisciplinary team composed by endocrinologist, nephrologist, oncologist and primary care physician collaborated to improve the quality of care of the patient and tried to understand the etiology of the refractory hypocalcemia despite optimal treatment. The solid cooperation between the care manager and the patient and the collaboration between the treating physician and the consultants had a positive impact on patient health and management.

The recommended treatment of hypocalcemia in metastatic prostate cancer is supplementation with calcium and active metabolite of vitamin D along with the correction of the hypomagnesemia

[15,19,20]. In our patient, despite high doses of IV and oral calcium associated with high doses of calcitriol (2 µg/day), inactive vitamin D (10000 U/day) and magnesium, the corrected calcemia remained very low over several days. We decided then to initiate a treatment by steroids (Solumedrol 60 mg) knowing that the steroids inhibit the osteoblastic activity which is activated in bone metastases from prostate cancer and inhibit the differentiation of osteoblasts by down regulating hepatocyte growth factor synthesis in human osteoblasts [21,22]. The result was unpredicted. In only 24 hours, the calcium level raised by 2 points and normalized in 2 days. The steroid dose was tapered gradually and stopped after 7 days.

Initiation of prostate cancer treatment (hormonal treatment and chemotherapy) might have played a role in controlling the hypocalcemia. However, this is probably unlikely since the calcium level was significantly corrected just after the administration of steroids, possibly implying an action-to-effect relationship.

To our knowledge, this is the first case described in the literature of severe symptomatic hypocalcemia in a metastatic prostate cancer, not responding to conventional supplementation of calcium and vitamin D, and effectively treated with steroids.

As for the jaundice, in the absence of biliary tract obstruction, liver metastasis, infection or metabolic etiologies, paraneoplastic cholestasis should be considered. The latter will be discussed in a separate article.

Conclusion

Severe symptomatic hypocalcemia in metastatic prostate cancer is a rare condition. The hypocalcemia is mainly due to the osteoblastic action of the metastatic bone lesions. When it is refractory to conventional therapy, a treatment with steroids could be an effective option.

Declaration of Interest

No conflict of interest

References

1. Humphrey PA (2014) Cancers of the male reproductive organs. In: World Cancer Report. Stewart BW, Wild CP (Editors), World Health Organization, Lyon.
2. Szentirmai M, Constantinou C, Rainey JM (1995) Loewenstein JE: Hypocalcemia due to avid calcium uptake by osteoblastic metastases of prostate cancer. *West J Med* 163: 577-578.
3. Kukreja SC, Shanmugam A, Lad TE (1988) Hypocalcemia in patients with prostate cancer. *Calcif Tissue Int* 43: 340-345.
4. Rizzo C (2015) Refractory hypocalcaemia complicating metastatic prostatic carcinoma Rep. *BMJ Case Report*.
5. Hall TC, Griffiths CT, Petranek JR (1966) Hypocalcaemia - an unusual metabolic complication of breast cancer. *N Engl J Med* 275:1474-1477.
6. Berruti A, Dogliotti L, Bitossi R (2000) Incidence of skeletal complications in patients with bone metastatic prostate cancer and hormone refractory disease: predictive role of bone resorption and formation markers evaluated at baseline. *J Urology* 164: 1248-1253.
7. Szentirmai M, Constantinou C, Rainey JM, Loewenstein JE (1995) Hypocalcaemia due to avid calcium uptake by osteoblastic metastases of prostate cancer. *West J Med* 163: 577-578.
8. Lim SC, Tan CE, Aw TC (2000) A man with osteoblastic metastasis and hypocalcaemia. *Singapore Med J* 41: 74-76.

9. Smallridge RC, Wray HL, Schaaf M (1981) Hypocalcaemia with osteoblastic metastases in a patient with prostatic carcinoma, a cause of secondary hyperparathyroidism. *Am J Med* 71:184-188.
10. Fokkema (2005) Severe hypocalcaemia with extensive osteoblastic metastases. 63: 137.
11. Tommaso CL, Tucci JR (1979) Metabolic studies in a case of hypocalcemia and osteoblastic metastases. *Arch Intern Med* 139: 238-241.
12. Watanabe T, Adachi I, Kimura S (1983) A case of advanced breast carcinoma associated with hypocalcaemia. *Jpn J Clin Oncol* 13: 441-448.
13. Leese GP, Jung RT, Browning MC (1993) Hypomagnesaemia and hypocalcaemia in a patient with ovarian carcinoma. *Postgrad Med J* 69: 583-585.
14. Kalemkerian GP, Darwish B, Vartesian ML (1997) Tumor lysis syndrome in small cell carcinoma and other solid tumors. *Am Med J* 103: 363-367.
15. Cooper MS, Gittoes NJ (2008) Diagnosis and management of hypocalcaemia. *BMJ* 336: 1298-1302.
16. Tohme JF, Bilezikian JP (1993) Hypocalcemic emergencies. *Endocrinol Metab Clin North Am* 22: 363.
17. Zhang Z, Xu X, Ni H, Deng H (2014) Predictive value of ionized calcium in critically ill patients: an analysis of a large clinical database MIMIC II. *PLoS One* 9: e95204.
18. Zhang Z, Chen K, Ni H (2015) Calcium supplementation improves clinical outcome in intensive care unit patients: a propensity score matched analysis of a large clinical database MIMIC-II. *Springerplus* 4: 594.
19. Thakker R (2006) Hypocalcemia: pathogenesis, differential diagnosis, and management. In *Primer on the Metabolic Bone Diseases and Disorders of Mineral Metabolism*. Am Society of Bone and Mineral Res 6: 213.
20. Schilling T, Ziegler R (1997) Current therapy of hypoparathyroidism-a survey of German endocrinology centers. *Exp Clin Endocrinol Diabetes* 105: 237.
21. Pereira RM, Delany AM, Canalis E (2001) Cortisol inhibits the differentiation and apoptosis of osteoblasts in culture. *Bone* 28: 484-490.
22. Tsunashima Y, Kondo A, Matsuda T, Togari A (2011) Hydrocortisone inhibits cellular proliferation by downregulating hepatocyte growth factor synthesis in human osteoblasts. *Biol Pharm Bull* 34: 700-703.