

Reduced Efficacy of Enzyme Replacement Therapy in a Child with Late-Onset Pompe Disease

Satoru Takahashi^{*}, Ryosuke Tanaka, Satomi Okano, Akie Okayama, Nao Suzuki and Hiroshi Azuma

Department of Pediatrics, Asahikawa Medical University, Japan

^{*}Corresponding author: Satoru Takahashi, Department of Pediatrics, Asahikawa Medical University, 2-1-1-1 Midorigaoka-Higashi, Asahikawa 078-8510, Japan, Tel: 81-166-68-2481; Fax: 81-166-68-2489; E-mail: satoru5p@asahikawa-med.ac.jp

Rec date: Apr 29, 2016, Acc date: May 23, 2016, Pub date: May 25, 2016

Copyright: © 2016 Takahashi S, et al. This is an open-access article distributed under the terms of the Creative Commons Attribution License, which permits unrestricted use, distribution and reproduction in any medium, provided the original author and source are credited.

Abstract

Pompe disease is an autosomal recessive disorder caused by a deficiency of acid alpha-glucosidase (GAA), resulting in failure of lysosomal glycogen degradation. Patients with late-onset Pompe disease experience progressive muscle weakness and decreased respiratory function. Enzyme replacement therapy (ERT) for late-onset Pompe disease became available for clinical use in 2006. Clinical studies have since demonstrated beneficial effects on motor and respiratory functions in treatment periods up to 4 years. We report an 8-year period wherein a patient with late-onset Pompe disease received ERT with recombinant human GAA. The patient initially showed marked improvement in motor functions. However, these improvements stopped approximately 5 years after ERT, followed by progressive declines in muscle strength. Our case demonstrates that resistance to ERT might develop after long-term treatment. Elucidating the underlying mechanism is expected to have significant implications for the development of new therapeutic strategies in patients with late-onset Pompe disease.

Keywords: Computed tomography; Enzyme replacement therapy; Glycogen-storage disease; Lysosome; Myopathy; Pompe disease

site c.546G>T mutation and a recurrent missense p.R600C mutation [2].

Introduction

Pompe disease, an autosomal recessive disorder caused by a deficiency of acid alpha-glucosidase (GAA), results in failure of lysosomal glycogen degradation, leading to a progressive glycogen accumulation in tissues. Patients with late-onset Pompe disease experience progressive muscle weakness and decreased respiratory function. Enzyme replacement therapy (ERT) for Pompe disease supplements deficient GAA by intravenous administration of recombinant human GAA (rhGAA). ERT treatment is effective in stabilizing motor and respiratory functions in late-onset Pompe disease [1]. The treatment for Pompe disease became available for clinical use in 2006; thus, long-term effects can be reported only now. We report an 8-year period wherein a patient with late-onset Pompe disease received ERT.

Case Report

The patient, male and aged 16 years at the time of this report, was the first child of healthy unrelated Japanese parents. The patient was born at term after an uneventful pregnancy and was healthy in the neonatal period. Early motor development was not delayed: he could walk unaided at the age of 1 year and 3 months. At the age of 3 years, he suffered from influenza and was found to show elevated creatine kinase (CK) levels (1500–3000 U/l). An examination revealed mild muscle weakness with proximal dominance. Echocardiography was normal. Biopsied skeletal muscle showed many vacuoles filled with glycogen and with increased acid phosphatase activity. An enzyme assay revealed reduced GAA activity in the skin fibroblasts (0.76 nmol/mg protein per 30 min or 10.4% of the average control activity of 7.3 ± 2.2 nmol/mg protein per 30 min). Genetic analysis revealed compound heterozygous mutations of *GAA*: a newly discovered splice-

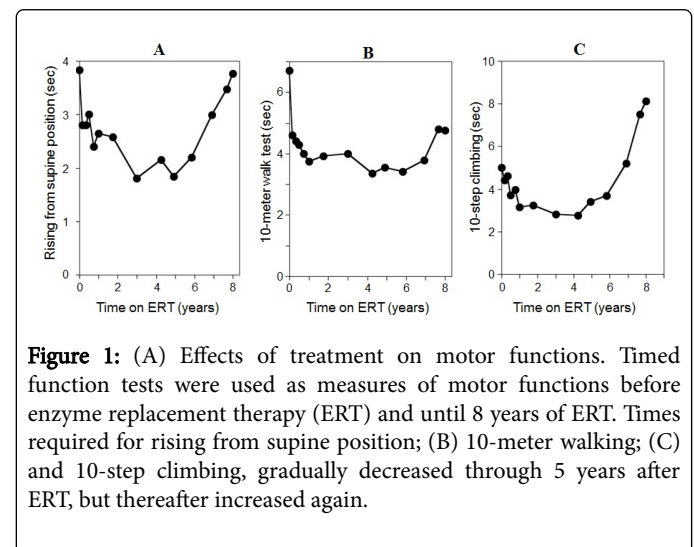


Figure 1: (A) Effects of treatment on motor functions. Timed function tests were used as measures of motor functions before enzyme replacement therapy (ERT) and until 8 years of ERT. Times required for rising from supine position; (B) 10-meter walking; (C) and 10-step climbing, gradually decreased through 5 years after ERT, but thereafter increased again.

The patient started ERT at 7 years of age when he exhibited proximal dominant muscle weakness and difficulty in jumping and running. The patient received intravenous infusions (20 mg/kg body weight) of rhGAA every 2 weeks. After starting ERT, the patient exhibited a good clinical response with partial recovery of exercise abilities (Figure 1). He gained the ability to jump and could enjoy mountain climbing and skiing. Serum CK levels decreased by 42% of the levels before ERT (Figure 2). However, these improvements stopped approximately 5 years after ERT, and were followed by progressive declines in motor functions (Figure 1). Muscle weakness was more pronounced in the proximal muscles than the distal muscles and more in the lower extremities than the upper extremities. He

showed Gower's sign and a waddling gait. He could not jump and needed to hold a rail to climb stairs. Serum CK levels increased with clinical deteriorations (Figure 2). Whereas, pulmonary function remained stable. His percentage of predicted forced vital capacity (FVC) was 65.1% at 8 years of age and 69.1% at 15 years of age. Anti-rhGAA IgG antibodies became detectable by 2 years after ERT and remained at low titers, in the range of 1:200 and 1:800. No consistent association was found between serum IgG antibody titer and therapeutic efficacy. Serial computed tomography (CT) scans of the thigh muscles demonstrated no atrophic changes (Figure 3).

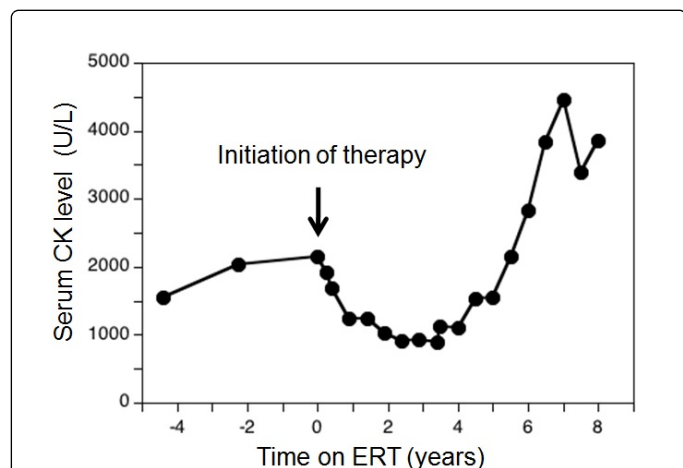


Figure 2: Serial changes in the serum creatine kinase (CK) levels in the patient with late-onset Pompe disease. Serum CK levels were elevated before enzyme replacement therapy (ERT), but decreased immediately after initiation of ERT. However, serum CK levels increased again 4 years after ERT.

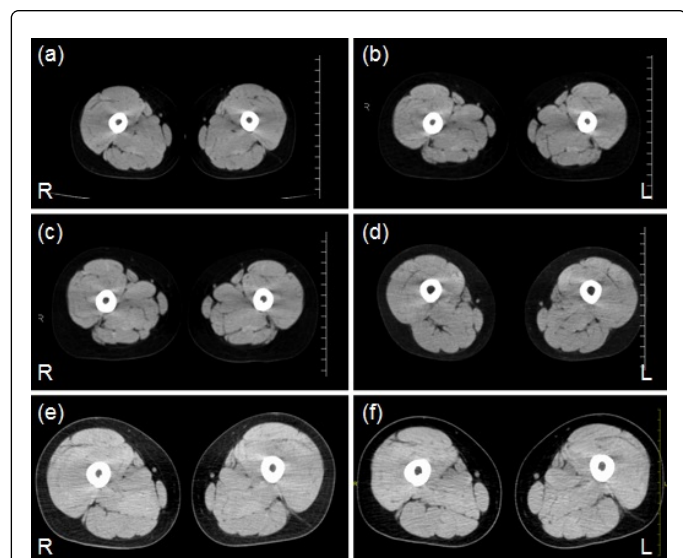


Figure 3: (a) Serial computed tomography scans of the thigh muscles before initiation of enzyme replacement therapy; (b) and after therapy, 1 year 4 months; (c) 2 years 5 months; (d) 4 years 9 months; (e) 6 years 3 months; (f) and 7 years 8 months.

Discussion

Clinical studies of ERT for late-onset Pompe disease demonstrate beneficial effects on motor and respiratory functions in treatment periods up to 4 years [1,3]. We report here an 8-year period wherein a patient with late-onset Pompe disease received ERT. The patient initially improved in terms of motor functions, but began to deteriorate after 4-5 years on ERT. Timed function tests clearly demonstrated changes in his muscle strength over time. Serum CK levels were a useful indicator of the treatment response: its reduction and elevation corresponded well with clinical improvement and deterioration, respectively.

In ERT, intravenously administered rhGAA is endocytosed at the plasma membrane and delivered to lysosomes. ERT efficacy depends on the accessibility of the affected cells to the infused enzyme. Uptake of the rhGAA is mediated by the cation-independent mannose-6-phosphate receptors (CI-MPRs). Expression levels of CI-MPR vary between tissues with the highest expression noted in the liver and heart and the lowest expression noted in skeletal muscles [4]. A predominant feature of late-onset Pompe disease is the early development of respiratory failure because of diaphragmatic involvement. A study demonstrated progressive deterioration of pulmonary function, showing mean annual declines of 1.6% in the percentage of predicted FVC [5]. Considering the progressive nature of this disease, stabilization of pulmonary function in this patient could be considered a positive treatment outcome. CI-MPR expression in the diaphragm is higher than in skeletal muscles [4]. Therefore, the poor response of skeletal muscles might be attributed, at least in part, to the low abundance of CI-MPR. New therapeutic approaches such as drugs enhancing CI-MPR expression or chemically modified rhGAA with high receptor affinity may contribute to overcome poor enzyme uptake by skeletal muscles.

Earlier model animal studies of Pompe disease demonstrated that incomplete lysosomal glycogen degradation disrupted autophagy, a major lysosome-dependent degradation pathway, resulting in intracellular accumulation of autophagic vacuoles [6]. Autophagic build-up causes muscle fiber damages and interferes with delivery of infused enzymes to lysosomes [7]. Elucidating the mechanism underlying the age-dependent development of ERT resistance is expected to have significant implications for the development of new therapeutic strategies in patients with late-onset Pompe disease.

Acknowledgements

We thank the patient and his parents for their willingness to participate in this report. We also thank Dr. Hideo Sugie for his assistance with the enzyme assay and Drs. Ichizo Nishino and Ikuya Nonaka for their assistance in pathological diagnosis.

References

1. van der Ploeg AT, Clemens PR, Corzo D, Escolar DM, Florence J, et al. (2010) A randomized study of alglucosidase alfa in late-onset Pompe's disease. *N Engl J Med* 362: 1396-1406.
2. Maimaiti M, Takahashi S, Okajima K, Suzuki N, Ohinata J, et al. (2009) Silent exonic mutation in the acid-alpha-glycosidase gene that causes glycogen storage disease type II by affecting mRNA splicing. *J Hum Genet* 54: 493-496.
3. Angelini C, Semplicini C, Ravaglia S, Bemi B, Servidei S, et al. (2012) Observational clinical study in juvenile-adult glycosinosis type 2 patients

-
- undergoing enzyme replacement therapy for up to 4 years. *J Neurol* 259: 952-958.
 4. Raben N, Danon M, Gilbert AL, Dwivedi S, Collins B, et al. (2003) Enzyme replacement therapy in the mouse model of Pompe disease. *Mol Genet Metab* 80: 159-169.
 5. Van der Beek NA, Hagemans ML, Reuser AJ, Hop WC, Van der Ploeg AT, et al. (2009) Rate of disease progression during long-term follow-up of patients with late-onset Pompe disease. *Neuromuscul Disord* 19: 113-117.
 6. Fukuda T, Ewan L, Bauer M, Mattaliano RJ, Zaal K, et al. (2006) Dysfunction of endocytic and autophagic pathways in a lysosomal storage disease. *Ann Neurol* 59: 700-708.
 7. Fukuda T, Ahearn M, Roberts A, Mattaliano RJ, Zaal K, et al. (2006) Autophagy and mistargeting of therapeutic enzyme in skeletal muscle in Pompe disease. *Mol Ther* 14: 831-839.