

Recurrent Uveitis-Glaucoma-Hyphema Syndrome due to Positional Pupillary Capture after Suture-Less Scleral-Fixated Secondary Intraocular Lens Placement

Hossein Ameri^{1*}, Sagar B. Patel²

¹Department of Ophthalmology, USC Roski Eye Institute, Keck School of Medicine, University of Southern California, Los Angeles, CA, USA; ²Department of Ophthalmology, Retina Consultants of Texas, Houston, TX, USA

ABSTRACT

Case of floppy iris leading to positional pupillary capture by a sutureless, scleral-fixated intraocular lens (IOL) causing recurrent uveitis-glaucoma-hyphema (UGH) syndrome. The patient developed recurrent episodes of UGH syndrome after dislocated IOL removal and placement of sutureless, scleral-fixated IOL. Gravitationally dependent pupillary capture was noted with the superior iris moving in front of and behind the IOL depending on head positioning. Ultrasonography showed a floppy iris that moved with shifting gaze. Lack of capsular bag may have contributed to extreme iris movements. Secondary IOL placement behind a peripherally preserved capsular bag may reduce the risk of UGH in similar cases.

Keywords: UGH syndrome; Intraocular lens; Floppy iris

INTRODUCTION

Several approaches for secondary intraocular lens (IOL) placement have been described. The ideal approach IOL placement in the bag or sulcus as these have the best visual outcomes and the fewest complications [1]. Without adequate capsular support options include an anterior chamber IOL, iris-fixated IOL, or scleral-fixated IOL. Each procedure has advantages and disadvantages [2]. The technique chosen depends on the ocular morbidities and surgeon preference.

No clear consensus exists on which technique is best [3]. One concern with scleral sutured IOLs is suture breakage or extrusion [4]. Due to this concern, the approach was modified with suture less scleral-fixation of a PCIOL. Both techniques have similar visual outcomes and complication rates [5]. but given the novelty of the suture less technique, specific complications are not known.

We report a case of floppy iris leading to positional pupillary capture by a suture less, scleral-fixated IOL causing recurrent uveitis-glaucoma-hyphema (UGH) syndrome and vitreous hemorrhage.

CASE STUDY

A 79 year-old female presented with blurred vision in the right eye and was noted to have a displaced IOL. She underwent pars plana vitrectomy and posterior chamber IOL exchange with sutureless scleral fixation. A complete vitrectomy was performed and the remaining capsular bag was removed. The IOL was removed through corneal incision. A 20.5 diopter MA60AC IOL was fixated to the sclera 3 mm posterior to the limbus using the modified Yamane technique [6].

On post-operative month one, the superotemporal iris was noted to be behind the IOL (Figure 1).

Correspondence to: Hossein Ameri, Department of Ophthalmology, USC Roski Eye Institute, Keck School of Medicine, University of Southern California, 1450 San Pablo Street, Los Angeles, CA 90033, USA, Tel: +1 3238656825; E-mail: ameri@med.usc.edu

Received date: September 8, 2021; **Accepted date:** September 22, 2021; **Published date:** September 29, 2021

Citation: Ameri H, Patel SB (2021) Recurrent Uveitis-Glaucoma-Hyphema Syndrome due to Positional Pupillary Capture after Suture Less Scleral-Fixated Secondary Intraocular Lens Placement. J Clin Exp Ophthalmol. 12:885.

Copyright: © 2021 Ameri H, et al. This is an open-access article distributed under the terms of the Creative Commons Attribution License, which permits unrestricted use, distribution, and reproduction in any medium, provided the original author and source are credited.

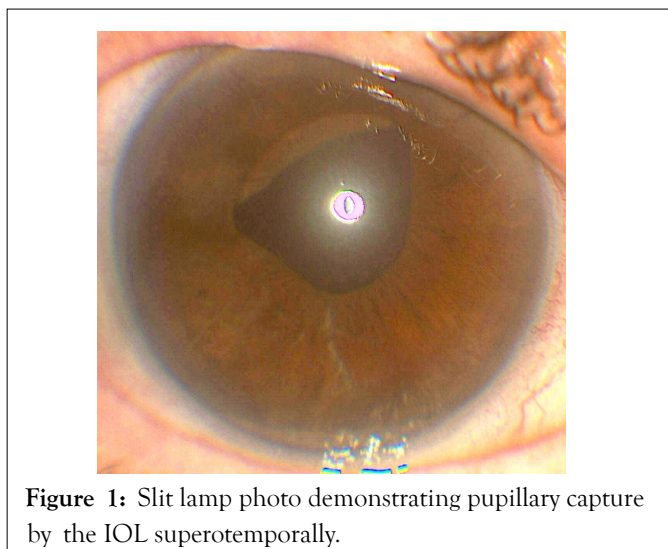


Figure 1: Slit lamp photo demonstrating pupillary capture by the IOL superotemporally.

Examination also but significant iris movement when patient looked up and down without IOL movement. Interestingly, when the patient was asked to bend forward the iris moved to the front of the IOL but when the exam chair reclined backwards, the iris moved to behind the IOL. Ultrasound biomicroscopy showed iridodonesis and IOL-chafing at 10:30 (Figure 2).

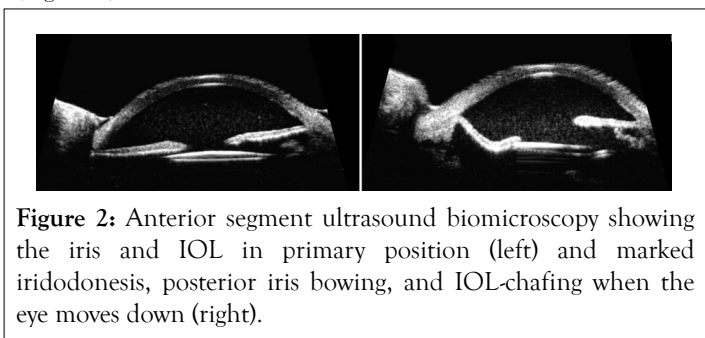


Figure 2: Anterior segment ultrasound biomicroscopy showing the iris and IOL in primary position (left) and marked iridodonesis, posterior iris bowing, and IOL-chafing when the eye moves down (right).

The superior iris was noted to have significant movement when the eye moved from superior gaze to inferior gaze. The IOL was slightly decentered and tilted at 10:30, but was stable.

The floppy iris resulted in multiple episodes of elevated IOP (range 9-46), and vitreous hemorrhage. Her visual acuity ranged from 20/25 between the episodes to 20/1000 to hand-motions during the episodes. Pilocarpine 1% was tried to keep the iris in front of the IOL and prevent recurrent chafing, but the patient continued to have episodes of UGH and pupillary capture.

Iridoplasty versus removal of the IOL were discussed with the patient and she opted for the latter. The IOL was successfully explanted and the patient left aphakic. Following the IOL removal, her IOP remained within normal limits without the use of medications and her visual acuity was 20/25 with an aphakic contact lens.

DISCUSSION

Secondary IOL placement is a useful technique to address complications of cataract surgery, including dislocated IOLs [6]. Complications associated with scleral-fixated IOLs include hemorrhage (hyphema or vitreous), cystoid macular edema, glaucoma, corneal edema, uveitis, and retinal detachment [1].

UGH syndrome has been reported to occur in 3% of cases after sutured scleral-fixated IOLs [7]. Intermittent pupillary capture of the IOL optic has been reported in 7.9% of these patients [8]. Most studies analyzing outcomes and complications of scleral-fixated IOLs have studied scleral sutured IOLs. These studies have shown that long-term complications related to the suture remain a problem [9]. Newer techniques have been developed to reduce suture-related complications by using suture less scleral fixation [6]. Given the recent advent of this technique, unforeseen complications may exist.

We present a patient with recurrent episodes of UGH syndrome due to floppy iris leading to positional pupillary capture after suture less scleral fixation of the IOL. We noted that the iris moved posterior to the IOL optic while the patient was supine, and the iris moved anterior to the IOL when the patient bent forward. The ultrasound biomicroscopy showed the iris to be significantly floppy with a wide range of movement when shifting between up and down gaze, repeatedly chafing on the IOL. While the IOL showed slight tilt, it did not show any movement. This gravitationally dependent pupillary capture may have resulted in episodes of iris chafing that worsened when the patient was supine, leading to recurrent UGH syndrome. Even when the pupil was constricted using pilocarpine, the episodes continued.

While pupillary capture has been described in up to 7.9% of patients after scleral sutured IOL, we present the first case of gravitationally dependent pupillary capture from floppy iris after suture less secondary IOL placement. We suspect that the lack of zonules and capsular bag support as well as the lack of vitreous support following the vitrectomy may have contributed to the extreme iris movements in this case, leading to the pupillary capture. Another consideration is the placement of the haptics 3 mm from the limbus. A more anterior placement of 2 mm may have supported the iris better and limited its floppiness. Previous reports have found floppy iris' to occur following scleral sutured IOL implantation in patients with Marfan syndrome [10]. Our case is unique due to the gravitational dependence of the pupillary capture. It is plausible that intraocular fluid flow around the IOL during movement of the eye between an upright and supine position may result in extreme movement of the iris due to the lack of capsular bag and zonular support posterior to the iris (Figure 3).

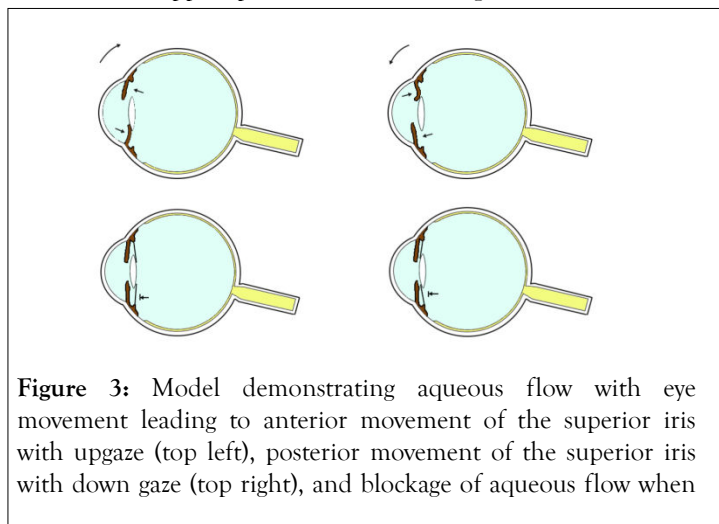


Figure 3: Model demonstrating aqueous flow with eye movement leading to anterior movement of the superior iris with upgaze (top left), posterior movement of the superior iris with down gaze (top right), and blockage of aqueous flow when...

the capsular bag is in place (shown in black) behind the IOL (bottom left) or in front of the IOL (bottom right). Note the haptics of the IOL are not shown.

If the capsular bag and zonules were intact, the vitreous fluid motion would not be transmitted to the iris. When examining the ultrasound biomicroscopy video, the iris exhibited a sporadic and sinusoidal floppiness with movement of the eye.

CONCLUSION

The suture less technique remains a useful and effective approach due to lack of suture related complications. As with any surgery, the risks and benefits of suture less surgery must be considered. Lack of capsular bag support may have contributed to the extreme iris movement in this case. Preservation of zonules and peripheral capsular bag and placement of the secondary IOL in front of or behind the partially preserved capsular bag may prevent this complication. If the IOL is going to be placed behind the capsular bag, a large central capsulotomy is needed to allow the passage of the IOL. Prior to placing a suture less, scleral-fixated IOL, the surgeon should examine for any signs of floppy iris. Proper patient selection is key to successful secondary suture less IOL placement.

FINANCIAL SUPPORT

Unrestricted Grant to the Department of Ophthalmology from Research to Prevent Blindness, New York, NY, USA.

ACKNOWLEDGEMENTS

Sagar Patel: None, Hossein Ameri: Spark Therapeutics, Consultant.

REFERENCES

1. Brunin G, Sajjad A, Kim EJ, Montes de Oca I, Weikert MP, Wang L, et al. Secondary intraocular lens implantation: Complication rates, visual acuity, and refractive outcomes. *J Cataract Refract Surg.* 2017; 43:369-376.
2. Gross JG, Kokame GT, Weinberg DV. For the Dislocated In-The-Bag Intraocular Lens Study Group. In-the-bag intraocular lens dislocation. *Am J Ophthalmology.* 2004; 137:630-635.
3. Wagner M, Cox T, Ariyasu R. Intraocular lens implantation in absence of capsular support. *Ophthalmology.* 2003; 110:840-859.
4. Dick HB, Augustin AJ. Lens implant selection with absence of capsular support. *Curr Opin Ophthalmol.* 2001;12:47-57.
5. Sindal MD, Nakhwa CP, Sengupta S. Comparison of sutured versus sutureless scleral-fixated intraocular lenses. *J Cataract Refract Surg.* 2016;42(1):27-34.
6. Yamane S, Sato S, Maruyama-Inoue M, Kadonosono K. Flanged intrascleral intraocular lens fixation with double-needle technique. *Ophthalmology.* 2017; 124(8):1136-1142.
7. Dimopoulos S, Dimopoulos V, Blumenstock G, Trevino-Rodriguez H, Bartz-Schmidt KU, Spitzer MS, et al. Long-term outcome of scleral-fixated posterior chamber intraocular lens implantation with the knotless Z-suture technique. *J Cataract Refract Surg.* 2018;44(2): 182-185.
8. Bading G, Hillenkamp J, Sachs HG, Gabel VP, Framme C. Long-term safety and functional outcome of combined pars plana vitrectomy and scleral-fixated sutured posterior chamber lens implantation. *Am J Ophthalmol.* 2007; 144:371-377.
9. Vote BJ, Tranos P, Bunce C, Charteris DG, da Cruz L. Long-term outcome of combined pars plana vitrectomy and scleral fixated sutured posterior chamber intraocular lens implantation. *Am J Ophthalmol.* 2006;141:308-312.
10. Bardorf CM, Epley KD, Lueder GT, Tychsen L. Pediatric transscleral sutured intraocular lenses: Efficacy and safety in 43 eyes followed an average of 3 years. *J AAPOS.* 2004;8: 318-324.