

Rapid Quantification of Mean Myocardial Wall Velocity in Ischemic Cardiomyopathy by Cardiac Magnetic Resonance: An Index of Cardiac Functional Abnormalities during the Cardiac Cycle

Srilakshmi M Adhyapak^{1*}, Prahlad G Menon^{2*}, Abhinav Mehra³, Stephen Tully⁴ and Rao Parachuri V⁵

¹Department of Cardiology, St. John's Medical College Hospital, India

²Electrical & Computer Engineering Sun Yat-sen University - Carnegie Mellon University (SYSU-CMU) Joint Institute of Engineering (JIE), Pittsburgh PA, USA

³Department of Biomedical Engineering, Georgia Institute of Technology, Atlanta, GA, USA

⁴QuantMD, LLC, Pittsburgh, PA, USA

⁵Heart Lung Transplantation Program Narayana Hrudayalaya, Institute of Medical Sciences, India

Abstract

Background: Characterization of regional Left Ventricular (LV) function in Heart Failure (HF) patients may have application in assessing response and choice of HF therapy.

Methods: 4D LV endocardial function from cine cMR data in 12 NYHA Class III /IV Heart Failure (HF) patients with antero-apical aneurysms was compared against normal controls. The endocardial surface contours were extracted at each cardiac phase using Medviso Segment. An in-house plugin was used to compute a signed Hausdorff Distance (HD), establishing point-correspondences between endocardial segmentations at consecutive cardiac phases and tracking their surface motion throughout the cardiac cycle. The LV averaged myocardial velocity, was computed based on phase-to-phase displacement at several uniformly spaced endocardial surface points and the displacement histories of each point were recorded. The average and standard deviation in the endocardium-averaged displacement history characteristic curves for the HF patients and normal controls were compared.

Results: The endocardium-averaged phase-to-phase displacement history curves of HF cohort revealed diminished displacement magnitudes; and indistinct individual end-systolic and diastole instants with large standard deviations across the LV. When the cumulative phase to phase displacement plots for controls and HF patients were compared, there was a statistically significant difference between the two characteristic curves during the ejection phase, early filling phase of diastole, and the end diastolic phase.

Conclusions: Shape-based Mean Myocardial Velocity (MMV) characterization constitutes a promising paradigm which may have application to prognosticate response to therapy.

Keywords: Left ventricular aneurysms; Cardiomyopathy; Heart failure; Cardiac magnetic resonance imaging

Introduction

Ischemic cardiomyopathy is characterized by Intraventricular Dyssynchrony (IVD) owing to the presence of islands of viable myocardium interspersed with non-viable, non-contractile areas of scarred myocardium which correspond with regional wall motion abnormalities [1]. Despite the availability and increasing popularity of semi-automated cardiac contouring tools, visual estimation of regional endocardial wall velocity from echocardiography or cine short-axis Cardiac Magnetic Resonance (cMR) imaging is subjective and confounded by observer dependence, leading to inter-observer and intra-observer variability [2,3]. The rapid four dimensional (4D=3D+time) assessment of myocardial velocities across the cardiac cycle from cine imaging of the heart may constitute a more sensitive and specific indicator of myocardial motion throughout the cardiac cycle which is observer independent and objective [4].

Although assessment of Mean Myocardial Velocity (MMV) is currently done using Doppler tissue imaging, cMR has been identified as a sensitive, specific and better spatio-temporally resolved imaging modality for reporting velocity of wall motion [5]. However, accurate assessment of regional myocardial displacement, velocities or strain currently requires the use of tagged cMR owing to the challenge of tracking regional phase-to-phase tissue correspondences through the cardiac cycle from gated volume-image datasets acquired over time. The primary aim of this study is to define a novel shape-derived metric

of cardiac function at each available phase of the cardiac cycle from untagged cine cMR image data segmented in 3D for endocardial contours, by automatically establishing the required regional phase-to-phase tissue correspondences at several points on the Left Ventricular (LV) endocardium and tracking them for accurate velocity estimation. We characterize a time-resolved metric of Mean Myocardial Velocity (MMV) over the cardiac cycle using the average of Phase-to-Phase Displacement (PPD) computed between consecutive cardiac phases. Additionally, IVD is quantified across the entire 3D endocardial surface based upon phase-to-peak displacement computed at each of

***Corresponding authors:** Srilakshmi M Adhyapak, Department of Cardiology, St. John's Medical College Hospital, Bengaluru, India, Tel: +91-80-27835000; E-mail: srii2881967@yahoo.com

Prahlad G Menon, PhD, Assistant Professor of Electrical & Computer Engineering Sun Yat-sen University - Carnegie Mellon University Joint Institute of Engineering 700 Technology Drive, #4319, Pittsburgh, PA: 15219, USA, E-mail: pgmenon@andrew.cmu.edu

Received January 23, 2014; **Accepted** February 18, 2014; **Published** February 25, 2014

Citation: Adhyapak SM, Menon PG, Mehra A, Tully S, Rao Parachuri V (2014) Rapid Quantification of Mean Myocardial Wall Velocity in Ischemic Cardiomyopathy by Cardiac Magnetic Resonance: An Index of Cardiac Functional Abnormalities during the Cardiac Cycle. J Clin Exp Cardiol 5: 288. doi:10.4172/2155-9880.1000288

Copyright: © 2014 Adhyapak SM, et al. This is an open-access article distributed under the terms of the Creative Commons Attribution License, which permits unrestricted use, distribution, and reproduction in any medium, provided the original author and source are credited.

the 4D-tracked endocardial surface points. The presented techniques have been applied to LV function characterization but are eminently applicable to characterization of other anatomical structures segmented in 3D over time from cine medical image data, to characterize for instance regional right ventricular dyssynchrony, regional wall thickening function, mechanical timing of valve motion or even arterial pulse wave propagation across arterial walls. MMV has potential to augment current global indices of cardiac function extracted from cine cMR images and better characterize patients with ischemic heart disease, which may lead to more objectify clinical decision for patient management, including perhaps more appropriate patient-selection for Heart Failure (HF) therapy.

Methods

Patients

We studied 12 patients diagnosed with ischemic cardiomyopathy with anterior LV aneurysms. All patients had a past history of ST-Segment Elevation Myocardial Infarction (STEMI) and had received pharmacological thrombolytic therapy. Inclusion was based on Q-waves on the surface electrocardiogram and regional wall motion corresponding to the infarct area as per 2D Echocardiography. All patients were subjected to cMR studies detailed in the sections below, after institutional review board approval. In order to compare the mean myocardial velocity metric against that computed for normal patients, 12 normal age and sex matched controls (ejection fraction, EF>55%, no infarction, no hypertrophy) extracted from the Sunnybrook cardiac database via the CardiacAtlas.org portal, were also studied. The study was approved by the Institutional Ethics Committee and all patients gave informed consent for the cMR imaging [6-8].

Imaging

Using a 1.5T cMR system (Sign ACV/I, GE Healthcare, Milwaukee, WI) equipped with a 4-channel phased-array chest radiofrequency coil, we performed MR imaging in standard short-axis and long-axis planes in two orthogonal directions for each plane. The imaging sequences analyzed in this study for wall-motion analysis were primarily ECG-gated 2D Steady-State Free Precession (SSFP) cine cMR images from LV base to apex (8 mm thick slices, zero spacing). Late Gadolinium Enhancement (LGE) cMR image were also quantified for scar burden percentages in order to correlate wall motion abnormalities with the extent of scar burden.

Image analysis

LV endocardial surface contours were first extracted in a supervised fashion from 2D MRI data using the active-contours, in Medviso Segment (MedvisoAB, Lund, Sweden), following which endocardial surface was reconstructed in 3D, at each cardiac phase. Next, to establish a metric of intraventricular dyssynchrony, an in-house plugin was developed in Paraview (Kitware, Inc., Clifton Park, NY) to compute a Hausdorff Distance (HD) metric at each endocardial surface point prefixed with a sign (positive or negative) based on the direction of phase-to-phase surface motion [9]. The HD characterizes a Phase-to-Phase Displacement (PPD, in mm) - a velocity metric - which inherently establishes point-correspondences of several uniformly spaced surface points between consecutive pairs of cardiac phases. The PPD histories were recorded as result of tracking endocardial point motion, therefore allowing us to define an endocardium-averaged metric of myocardial velocity at each cardiac phase viz. mean myocardial velocity (MMV, in mm/phase). The displacement histories of each point were recorded.

Surface colormaps of regional endocardial PPD were prepared at each instant of the cardiac cycle to provide a qualitative sense for the nature of regional wall motion. Further, phase of peak PPD during systole was also computed at each tracked endocardial surface location and presented as a color map at the end-systolic phase endocardial surface reconstruction, as an objective metric for the existence of regional mechanical dyssynchrony.

The average and standard deviation in the endocardium-averaged displacement history viz. MMV characteristic curves for our cohort of HF patients and normal controls were compared over uniform spaced temporal intervals through the cardiac cycle. The cardiac cycle was then discretized using only MMV characteristic curves into six standardized period labels: atrial contraction/late diastolic filling (AC), Isovolumetric Contraction (IC), Ventricular Ejection (VE), Isovolumetric Relaxation (IR), Rapid Ventricular Filling (RVF), and diastasis. AC was the equivalent period between the P wave and the R wave of the simultaneously recorded electrocardiogram. Similarly, IC was the period between the R wave of the electrocardiogram and the opening of the aortic valve. VE was between the opening of the aortic valve and the end of the T wave of the electrocardiogram. IR was the period between the closing of the aortic valve at the end of the T wave and the electrocardiogram and the opening of the mitral valve. RVF was regarded as the period between the opening of the mitral valve and the end of the E wave of the anterior leaflet of the mitral valve. Diastasis was the period between the end of the E wave of the anterior leaflet of the mitral valve and the P wave of the electrocardiogram.

All patients underwent a standard 2D echocardiographic evaluation including Doppler studies. The MMV was compared with the standard 2D echocardiographic indices of systolic and diastolic function.

Finally, all three individuals who analyzed the images were blinded to the patient data to avoid bias.

Statistical analysis

All continuous values were expressed as mean \pm standard deviation (SD) and categorical variables as numbers (%). The Wilcoxon signed rank test was used to compare the continuous variables between the patients and controls. The Pearson's correlation coefficient was used to correlate the systolic indices of peak ejection with LVEF and early filling in diastole with Doppler indices of LV diastolic dysfunction. A p-value of ≤ 0.05 was considered significant. SPSS v13 (SPSS Inc., Chicago, IL, USA) was used for statistical analyses.

Results

Clinical data

The study patient cohort comprised of 10 males and 2 females, with an age range of 45 to 70 years (mean age: 55.6 ± 12.9 years). All patients had a past history of transmural anterior wall myocardial infarction corresponding to the Left Anterior Descending Coronary Artery (LAD). The interval from infarction to LV aneurysm formation was 39.3 ± 13.3 months. The interval from the occurrence of myocardial infarction to cMR imaging was 41.8 ± 12.2 months. All patients had received thrombolytic therapy. Nine of the twelve patients had history of diabetes mellitus and hypertension. All patients presented with congestive cardiac failure-NYHA Class 3 ± 1.2 . None had history of angina, arrhythmias or cerebrovascular accident. All were on maximal tolerated doses of beta blockers, ACE inhibitors, aldosterone antagonists, statins and anti-platelet agents. After initiating decongestive measures,

coronary angiography conducted in all patients revealed single vessel disease affecting the LAD in 8 patients and 2 vessel disease involving the LAD and LCX in 2 patient. Two patients had a re canalized LAD.

All controls were age and sex matched. None had hypertension, diabetes mellitus or history of myocardial infarction. All had normal LV systolic and diastolic functions.

Imaging results

All patients had LV dilatation with large anterior LV aneurysms, with a mean LV EDV of 176.7 ± 99 mL/m² BSA and mean LV ESV of 161.8 ± 99.3 mL. The mean LVEF was $18.2 \pm 8.8\%$. The HD shape analysis resulted in an objective colored rendering of regional shape deformation to visually establish existence of hypokinetic (yellow), akinetic (green) and dyskinetic (red at systole, blue at diastole) regions (Figures 1A). The objective colored rendering of regional shape deformation at the instant of peak ejection and peak filling demonstrated the areas of dyskinesia/akinesia as colored green, whereas the normal contractile myocardium exhibited uniform colors viz. blue and red during systole and diastole, respectively (Figure 1B). This colored rendering ensured a visual estimate of regional LV shape, heterogeneity of LV contraction and relaxation and intra ventricular dyssynchrony. The areas activated first, and the areas activated last with their relaxation patterns provided an objective accurate estimate of the extent of LV remodeling and mechanical dyssynchrony. All patients demonstrated large areas of akinesia/dyskinesia colored green corresponding to the anterior and anteroseptal LV areas. These areas were dyssynchronous during contraction in systole and during relaxation in diastole which presented a stark distinction from the mostly synchronous contraction (see uniformly blue, indicating inward surface motion) and relaxation (see uniformly red, indicating outward surface motion) of the normal LVs (Videos 1 and 2).

When the cumulative PPD for controls and HF patients were compared, there was a significant difference in the ejection phase ($p=0.002$) and early filling phase of diastole ($p=0.001$), and the end diastolic phase ($p=0.01$; Figure 2 and Table 1). It was also noted that the isovolumetric contraction phase was prolonged in patients with ischemic cardiomyopathy. The ejection phase demonstrated lower myocardial velocities and extended into the isovolumetric relaxation phase of diastole. In diastole, the early filling phase has significantly lesser myocardial velocities as with the late filling phase. At end diastole, there was a significantly lower myocardial velocity which extended into the beginning of the next cardiac cycle. The MMV in the ejection phase correlated significantly with the LVEF, $r^2=0.98$, $p=0.001$. The MMV in the early filling phase of diastole correlated significantly with LV diastolic dysfunction in the patients, mainly the early filling E wave of the mitral inflow velocities $r^2=0.86$, $p=0.02$.

When the MMV was correlated to the patients' clinical findings, the patients with the largest scar burden ($40 \pm 8\%$ as per LGE CMR data) had the lowest MMV during the ejection phase of systole ($r^2=-0.78$, $p=0.04$). The isovolumetric contraction phase in these patients was more prolonged extending into the ejection phase ($r^2=0.83$, $p=0.04$). Clinically, these patients were in NYHA class IV and had greater re-admission rates for HF (14 re-admissions versus 8). This also had a significant negative correlation with the early diastolic MMV ($r^2=-0.9$, $p=0.024$). The patients with lesser re-admissions ($n=8$) had a significantly lesser scar burden ($32 \pm 7.2\%$, $p=0.04$ as per LGE CMR data).

3D color renderings of phase of peak PPD during systole (Figure 3, color map rendered at end-systolic phase), provided an objective confirmation for the regions poor mechanical function and dyssynchrony, the presence of which was evidenced by the MMV characteristic plots. In the HF patients, the dyssynchronous mechanical

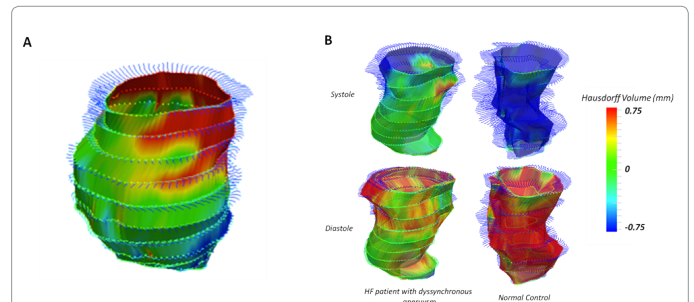
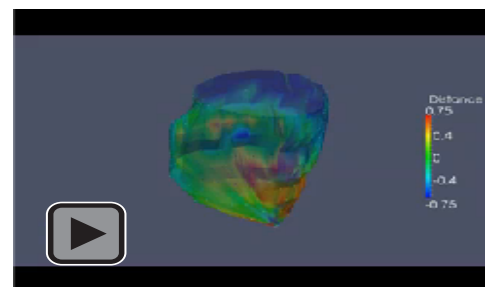
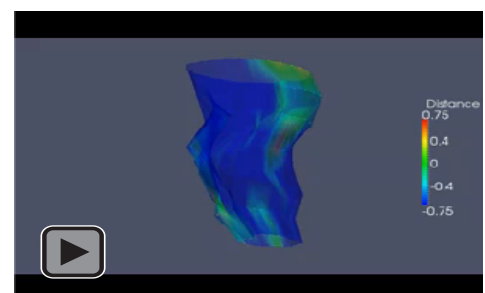


Figure 1: (A) Patient with antero-apical aneurysm (LAD infarct) with LV colored by HD at the instant of peak diastolic filling with regional P2PD history lines plotted showing a distinct (longer) history of contraction (blue) in viable LV regions (red, during diastolic filling). (B) HF patient and normal LVs compared at peak ejection (systole) and peak filling (diastole) instants, indicating that normal LV contraction showed uniformly blue (contraction) and red (expansion) whereas patient LVs had large akinetic (green) territories.



Video 1: The objective colored rendering of regional shape deformation (i.e. phase to phase HD, in mm) throughout the cardiac cycle for a representative HF patient with an antero-septal (toward apex) aneurysm (Video 1), and a normal patient (Video 2). It is possible to visually establish existence of hypokinetic (yellow), akinetic (green) and dyskinetic (red at systole, blue at diastole) regions, for the HF patient, whereas the normal contractile myocardium exhibits mostly synchronous contraction with uniform colors viz. blue and red during systole and diastole, respectively.



Video 2: The objective colored rendering of regional shape deformation (i.e. phase to phase HD, in mm) throughout the cardiac cycle for a representative HF patient with an antero-septal (toward apex) aneurysm (Video 1), and a normal patient (Video 2). It is possible to visually establish existence of hypokinetic (yellow), akinetic (green) and dyskinetic (red at systole, blue at diastole) regions, for the HF patient, whereas the normal contractile myocardium exhibits mostly synchronous contraction with uniform colors viz. blue and red during systole and diastole, respectively.

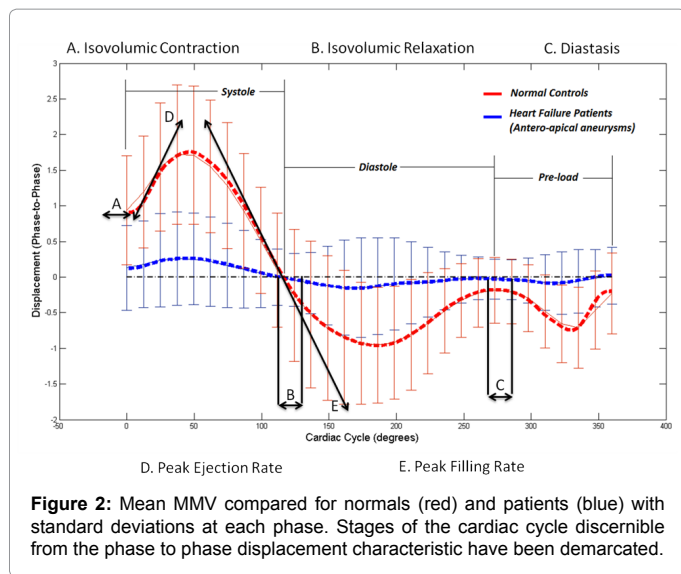


Figure 2: Mean MMV compared for normals (red) and patients (blue) with standard deviations at each phase. Stages of the cardiac cycle discernible from the phase to phase displacement characteristic have been demarcated.

Cardiac cycle	MMV patients (mm/phase)	MMV Controls (mm/phase)	p Value
Systole			
Iso volumetric contraction	1.01 ± 0.02	1.00 ± 0.4	0.56
Ejection Phase	0.05 ± 0.21	0.93 ± 0.54	0.00
Diastole			
Iso volumetric relaxation	-0.31 ± 0.43	-0.43 ± 0.21	0.89
Early filling	-0.25 ± 0.02	-0.98 ± 0.30	0.001
Late filling	-0.76 ± 0.2	-0.26 ± 0.03	0.01

MMV: Mean Myocardial Velocity

Table 1: Comparison of mean myocardial velocities at the phases of the cardiac cycle between patients and controls.

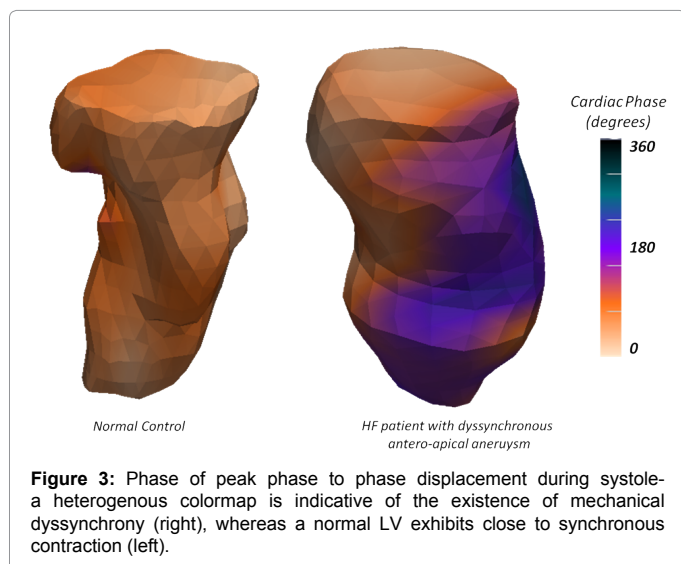


Figure 3: Phase of peak phase to phase displacement during systole—a heterogenous colormap is indicative of the existence of mechanical dyssynchrony (right), whereas a normal LV exhibits close to synchronous contraction (left).

activation regions were collocated with the territories of adverse LV remodeling (i.e. aneurysm). The inter-observer and intra-observer variability was 0.02%.

Discussion

The presented methodology for analyzing propagation of

mechanical contraction is a regional shape-based myocardial velocity metric which is more highly resolved and more objective to correlate abnormalities to regional LV shape (or remodeled territories) than that which is possible to discern by analysis of LV time-volume curves presented in a 17-segment American Heart Association (AHA) bulls-eye plot [10,11]. The technique of MMVs was also sensitive to the considerable heterogeneity in the mean myocardial velocities between the inter-ventricular septum (IVS) and the LV posterior wall during the cardiac cycle in normal individuals, as is evidenced from the standard deviations in our MMV characteristic plots (Figure 2) [12]. The IVS was observed to have a significantly greater MMV than the LV posterior wall in isovolumetric contraction in systole, isovolumetric relaxation and diastasis in diastole, while the LV posterior wall has a significantly greater MMV than the IVS during peak ejection in systole, peak filling and late filling in diastole.

The MMV estimation by cMR is an accurate and sensitive index of myocardial wall motion and provides invaluable information for the management of patients in HF. As cMR-based interpretation of endocardial wall location is objective as it is clearly discernible, the supervised image-segmentation strategy employed for this study minimized the occurrence of intra-observer and inter-observer variability. The objective mapping of MMV not only leverages the full richness of the cMR based wall-motion information during the cardiac cycle but also gives a clue as to which phase of the cardiac cycle is most affected by pathological processes, especially LV remodeling related dyssynchrony.

We have studied patients in advanced HF and extensive LV remodeling following transmural myocardial infarctions. The MMV of the patients was significantly different from the controls during the ejection phase of systole and the early and late diastolic filling phases. The LV scar burden correlated negatively with the ejection velocities and positively with the duration of isovolumetric contraction during systole, which is expected owing to scarred regions having diminished contractility. Scar burden also correlated negatively with the MMV of early filling during diastole. The patients with advanced remodeling had abnormal contraction patterns with in-effective ejection and impaired LV filling during diastole which correlated with standard indices of systolic function; LVEF and Doppler indices of LV diastolic dysfunction; LVDD grade III/IV [13]. They were clinically in advanced NYHA class IV HF and had significantly greater number of re- admissions for HF than the patients with lesser advanced LV remodeling evidenced by the amount of scar burden. This subtle differentiation between the two groups of patients was possible due to the MMV quantification during systolic and diastolic phases of the cardiac cycle.

Myocardial velocities are known to have a direct correlation with myocardial wall thickening [14]. Myocardial wall thickening is an invaluable index of assessing viability by 2D echocardiography [15]. The maximal wall thickening occurs at end systole, correlating with maximal mean myocardial velocities during the phase. In dilated cardiomyopathy, the wall thickening although lesser than normal is uniform in all segments of the LV. In ischemic cardiomyopathy involving the anterior wall, the anterior wall has been demonstrated to show significant wall thinning in the anterior LV segments during end systole and end diastole [16]. Although we do not present myocardial wall thickening data, all our patients had extensive myocardial remodeling with scar burden with thinned myocardial walls, the presence of which is consistent in principle with our MMV findings. However, in patients with ischemic cardiomyopathy, the remote myocardial

characteristics adjacent to the scar are possible to be delineated by the techniques presented in this manuscript.

In addition, by studying the color coded 3D surface renderings of MMV, we were able to establish an objective parameter of mechanical dyssynchrony during systole and diastole. This color map rendering of mechanical dyssynchrony may also have application in the rapid and objective assessment of mechanical dyssynchrony in the context of patient selection for resynchronization procedures after other basic selection criteria are met. To further to validate the applicability of MMV to patients eligible for cardiac resynchronization therapy, myocardial velocity may additionally be further quantified using tagged cMR studies or speckle tracking echocardiographic methods in a larger-cohort clinical study; this is a subject of our ongoing efforts [12,17]. While other sensitive methods like Fourier indices of temporal uniformity of strain may help quantify mechanical dyssynchrony, such indices require the use of tagged cMR images which may require longer imaging times in contrast with the standard cine cMR sequences used for the analyses presented in this study.

This study constitutes a pilot study of a novel index quantifying the MMV in patients with ischemic cardiomyopathy during the phases of the cardiac cycle, using time-resolved cMR data. The presented techniques are as eminently applicable to time-resolved Computed Tomography (CT) segmentations at several cardiac phases, as it has been demonstrated on MRI data in this manuscript. Although this was tested in patients with advanced HF and extensive LV remodeling; LV aneurysms following myocardial infarctions, this index identifies patients with worse prognosis in terms of NYHA class and HF re-admissions. This helps in triaging these patients to early therapy in terms of cardiac transplantation, if eligible or to surgical ventricular restoration. The objective rendering of dyssynchronous contraction and relaxation patterns aids in patient selection for cardiac resynchronization therapy. This index helps quantification of abnormalities of myocardial mechanics in systole and diastole. Although, our study sample size was small (n=12), comparison with age and sex matched controls demonstrated significant abnormalities of contraction and relaxation which was consistent with standard parameters of systolic and diastolic LV function. Validation of this method needs prospective studies with larger sample size. Further, this study can be used to assess prognosis and response to therapy. The onset of subtle or incipient heart failure may also be detected by this technique. CMR minimizes inter-observer and intra-observer variability as it is a more objective imaging modality. Other imaging modalities like echocardiography are more subjective and hence prone to significant inter-observer and intra-observer variability.

Further this novel index can be tested in patients with acute ischemia and early HF to identify subtle abnormalities in MMV during the phases of the cardiac cycle. Response to therapy can also be assessed with this index. The degree of residual abnormality can be quantified and therapy can be tailored accordingly targeting pre-load or after-load reductions.

Limitations

Our sample size limits our ability to draw definite conclusions. However, the clinical application of this technique shows promise as the results of this pilot study reflects definitive delineation of ischemic cardiomyopathy correlating with standard defining parameters. Although MMV estimation is more accurate and less observer dependent than regional wall motion abnormalities, given that it

represents a condensed metric derived from a far richer analysis of regional wall motion which we present, it has its inherent limitations. We demonstrate assessment of the MMV of the total LV without limiting ourselves to estimation of functional parameters at the level of segments in AHA standard polar plots. Therefore, while color maps of regional HD and phase to peak regional systole are to be used as visual confirmations of the conclusion derived from MMV analysis, reduction of the 3D color maps at each cardiac phase into AHA standard segmental polar plot of MMV may help identify regional wall motion abnormalities in a more standard form familiar to cardiologists. Such polar plot representation may be useful for assessment of the degree of recovery of stunned myocardium, in patient-by-patient follow-up studies.

Assessment of regional myocardial wall thickening has not been done as all patients had extensive myocardial infarcts with aneurysms. However, this would be of immense help in patients presenting with ischemia or early HF and therefore establishing a regional wall-motion analysis using the HD quantification methodology is a subject of our ongoing efforts.

Conclusions

Our novel shape-based parameter establishing phase to phase endocardial surface correspondences between consecutive phases of the cardiac cycle quantifies mean myocardial velocity throughout the cardiac cycle, starting with un-tagged cMR images. In patients with ischemic cardiomyopathy, the period of isovolumetric contraction was prolonged and rapid ejection velocities were significantly lesser than controls in systole. In diastole, the IR was prolonged and the velocities during rapid filling and late filling were significantly lesser than controls. These parameters extracted from MMV analysis correlated significantly with established metrics of systolic function identifiable from cMR (e.g.: LVEF) as well as Doppler indices of diastolic function. The novel indices presented in this study were also found to correlate significantly with the clinical status of advanced HF and the anatomical substrate of myocardial infarct/ scar. The objective color rendering of MMV on 3D endocardial surface contours demonstrates a clear map of regional of mechanical dyssynchrony. In future, MMV may constitute an accurate and observer independent metric to evaluate patients with ischemic heart disease and quantify their response to therapy.

Acknowledgement

This work was supported by the Open Field Entrepreneurs Fund award to Menon PG.

Disclosure

Menon PG is the founder of QuantMD, LLC, a Pittsburgh, PA based healthcare startup working in the space of commercializing shape-based cardiovascular function analytics for diagnostics, surgical planning and intra-operative guidance applications. Both Menon PG and Tully S are shareholders in QuantMD, LLC.

References

- DiDonato M, Sabatier M, Dor V, Buckberg G; RESTORE Group (2004) Ventricular arrhythmias after LV remodelling: surgical ventricular restoration or ICD? *Heart Fail Rev* 9: 299-306.
- de Jonge GJ, van Ooijen PM, Overbosch J, Gueorguieva AL, Janssen-van der Weide MC, et al. (2011) Comparison of (semi-)automatic and manually adjusted measurements of left ventricular function in dual source computed tomography using three different software tools. *Int J Cardiovasc Imaging* 27: 787-794.
- Jaspers K, Freling HG, van Wijk K, Romijn EI, Greuter MJ, et al. (2013) Improving the reproducibility of MR-derived left ventricular volume and function measurements with a semi-automatic threshold-based segmentation algorithm. *Int J Cardiovasc Imaging* 29: 617-623.

4. Palka P, Lange A, Fleming AD, Sutherland GR, Fenn LN, et al. (1995) Doppler tissue imaging: myocardial wall motion velocities in normal subjects. *J Am Soc Echocardiogr* 8: 659-668.
5. Lardo AC, Abraham TP, Kass DA (2005) Magnetic resonance imaging assessment of ventricular dyssynchrony: current and emerging concepts. *J Am Coll Cardiol* 46: 2223-2228.
6. Alfakih K, Plein S, Thiele H, Jones T, Ridgway JP, et al. (2003) Normal human left and right ventricular dimensions for MRI as assessed by turbo gradient echo and steady-state free precession imaging sequences. *J Magn Reson Imaging* 17: 323-329.
7. Radau P, Lu Y, Connelly K, Paul G, Dick AJ, et al. (2009) Evaluation Framework for Algorithms Segmenting Short Axis Cardiac MRI. *The MIDAS Journal*.
8. Fonseca CG, Backhaus M, Bluemke DA, Britten RD, Chung JD, et al. (2011) The Cardiac Atlas Project—an imaging database for computational modeling and statistical atlases of the heart. *Bioinformatics* 27: 2288-2295.
9. Hausdorff, F (1918) Dimension und äußeres maß. *Mathematische Annalen* 79: 157-179.
10. Sohail M, Shetty A, Duckett S, Chen Z, Sammut E, et al. (2013) Noninvasive assessment of LV contraction patterns using CMR to identify responders to CRT. *JACC Cardiovasc Imaging* 6: 864-873.
11. Menon PG, Adhyapak SM, Parachuri VR (2013) Quantitative analysis of regional morphology and mechanical dyssynchrony using cardiac MRI for optimal surgical ventricular restoration. American Heart Association (AHA) Scientific Sessions, Texas, USA.
12. Bijnens B, Claus P, Weidemann F, Strotmann J, Sutherland GR (2007) Investigating cardiac function using motion and deformation analysis in the setting of coronary artery disease. *Circulation* 116: 2453-2464.
13. Nagueh SF, Appleton CP, Gillebert TC, Marino PN, Oh JK, et al. (2009) Recommendations for the evaluation of left ventricular diastolic function by echocardiography. *J Am Soc Echocardiogr* 22: 107-133.
14. Gorcsan J 3rd, Gulati VK, Mandarino WA, Katz WE (1996) Color-coded measures of myocardial velocity throughout the cardiac cycle by tissue Doppler imaging to quantify regional left ventricular function. *Am Heart J* 131: 1203-1213.
15. Myers JH, Stirling MC, Choy M, Buda AJ, Gallagher KP (1986) Direct measurement of inner and outer wall thickening dynamics with epicardial echocardiography. *Circulation* 74: 164-172.
16. Ardekani S, Weiss RG, Lardo AC, Miller MI, Winslow RL, et al. (2009) Cardiac Motion Analysis in Ischemic and Non-Ischemic Cardiomyopathy Using Parallel Transport. *Proc IEEE Int Symp Biomed Imaging*.
17. Bax JJ, Ansalone G, Breithardt OA, Derumeaux G, Leclercq C, et al. (2004) Echocardiographic evaluation of cardiac resynchronization therapy: ready for routine clinical use? A critical appraisal. *J Am Coll Cardiol* 44: 1-9.