

Radiological and Clinical Outcome of Distal Radial Fractures Managed by Variable Angle 2.4 mm Titanium Volar Plate

Khalid Masood*, Muhammad Akhtar, Khalid Zulfiqar Qureshi, Muhammad Umar Zahoor, Muhammad Siraj, Muzna Nazir Chaudhary and Alam Zeb

Hand and Upper Limb Surgery Center, Lahore, Pakistan

*Corresponding author: Khalid Masood, Hand and Upper Limb Surgery Centre (HULS), Opposite CMH, Abdul Rehman Road, Lahore, Pakistan, Tel: 00-923449032131; E-mail: kmasoodsurg@hotmail.com

Received date: July 05, 2016; Accepted date: July 15, 2016; Published date: July 22, 2016

Copyright: © 2016 Masood K, et al. This is an open-access article distributed under the terms of the Creative Commons Attribution License, which permits unrestricted use, distribution and reproduction in any medium, provided the original author and source are credited.

Abstract

Objective: To evaluate radiological and clinical outcome in fractures of the distal radius treated with internal fixation by applying variable angle 2.4 mm volar locking plate.

Study design: Prospective interventional study.

Place and duration of study: Hand and Upper Limb Surgery (HULS), Lahore, Pakistan between January 2014 and December 2015.

Methodology: Forty two patients (34 males, 08 females) with different types of fractures of distal radius were treated. Open reduction and Internal fixation was performed by applying 2.4 mm titanium variable angle volar locking plate. Anatomical restoration was evaluated by good-quality postero-anterior and lateral radiographs obtained preoperatively, immediately postoperatively and 09 months of follow up to evaluate Radial Height (RH), Radial Inclination (RI) and Volar Tilt (VT). Data was analyzed by One way repeated measure ANOVA test.

Results: There was perfect anatomical restitution in AO type A and B fractures that retained till 09 months follow up. In type C fractures, there was significant postoperative improvement but slight loss in radiological parameters by 09 months that was insignificant with P-value less than 0.01. There was credible improvement in wrist movements and grip.

Conclusion: The rigid characteristics of variable angle volar plate provide the best anatomical restoration and fixation of distal radius fractures and maintain stability to promote early postoperative wrist motion.

Keywords Internal fixation; Distal radius fractures; Variable angle locking plate; Volar fixation

Introduction

Fractures of the distal radius are extremely common. Incidence rates vary from 5.7 to 124.6 per 10,000 persons per year [1]. These fractures are being managed uniformly with conservative means showing satisfactory results [2]. There is a recent rise in high energy fractures of the distal radius in young adults, because of motor vehicle accidents and recreational activities, which invariably require surgical management [3].

Studies have shown that, in the distal radius fractures, function is related to the radiographic findings [2]. Restoration of normal alignment and articular congruity after a displaced fracture can be difficult but is essential for a good functional outcome in terms of early wrist motion, improvement in range of motion and grip strength [4,5]. It has been shown in the laboratory and clinical studies that extra and intra-articular malunion alters the function of wrist [4,6,7]. Conservative treatment options may result in inability to manipulate displaced or depressed articular fragments and may also overlook associated soft-tissue and ligamentous injuries, which are being recognized with increasing frequency [8,9]. A variety of treatment

options are available including closed reduction and cast immobilization, K-wire fixation, external fixation and Open Reduction and Internal Fixation (ORIF) with volar locking plate. The latter is a fixed angle implant which is being widely promoted by the surgeons and implants manufacturers [10] because biologically fracture treatment aims at restoring the axis and length of the injured bone, reconstructing the articular surface, and achieving a stable fixation that allows early motion and weight bearing [10]. Different studies have proved that internal fixation with fixed angle volar plate showed better results in terms of restoration of anatomy, fixation, stability and function in comparison with other methods.

The purpose of this study was to determine anatomical restoration and stabilization of acute fracture of the distal radius and clinical outcome, treated with ORIF by applying variable angle locking volar plate.

Materials and Methods

This was a prospective study of 42 patients with distal radius fractures who were treated by ORIF by using fixed angle volar plate in Hand and Upper Limb Surgery (HULS) Centre Lahore, Pakistan for a period of two years from January 2014 to December 2015. Two surgeons performed the procedure.

All patients with displaced fractures were offered ORIF. Willing patients underwent the surgery. Patients having age less than 16 Years and more than 75 Years, open fractures, bilateral fractures, who had undergone satisfactory closed reduction and external fixation or who had associated multiple injuries were excluded from the study.

All fractures were classified according to AO (the Association for Osteosynthesis) classification system [11] by getting Postero-Anterior (PA) and Lateral (Lat) views of radiographs of the wrist at the time of the initial injury. Some patients needed CT scan of wrist for further evaluation of intra-articular fractures.

All these patients were admitted to the hospital and operated on as early as possible, depending on local condition of tissue, oedema, hematoma and fitness of the patient for anaesthesia. After informed written consent, ORIF was performed via a volar approach and using 2.4 mm titanium variable angle volar locking plates (Figures 1 and 2). Surgery was performed under regional or general anesthesia and fluoroscopic guidance.

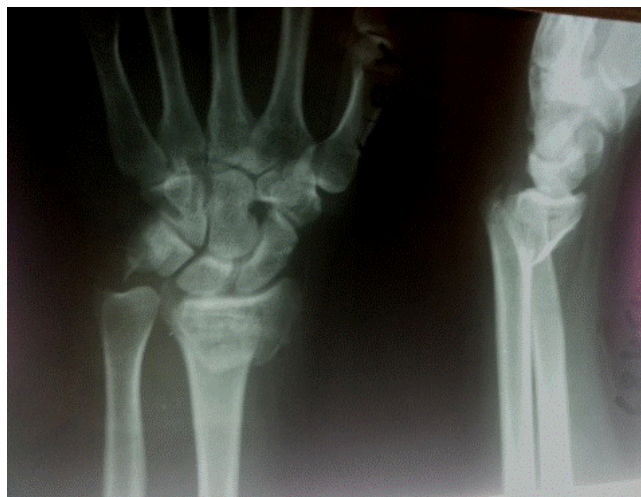

Figure 1: Pre-op.

All surgeons performing the surgery had necessary experience with the procedure and familiarity with the used implants. Post-operative cast splintage of the wrist did not exceed 10 days.

Radiographic evaluation

To evaluate type of fracture and post fixation restoration of anatomy, the study design mostly depends upon plain radiographs made at the patient's initial visit (pre op), immediate postoperatively (post op) and at 09 months of follow up (follow up). Radiological parameters included measurement of Radial Height (RH), Radial Inclination (RI) and Volar Tilt (VT) through PA and true lateral radiographs.

All imaging studies were assessed in a blind fashion by 2 independent investigators, and the 2 measurements were averaged. PA view provided information about RH (Radial height) or radial length and RI (Radial Inclination). Normal RI is 22 degrees and it was measured as an angle formed between a line drawn through the tip of the radial styloid and the medial corner of the lunate facet and a line drawn perpendicular to the long axis of the radius (Figure 3).

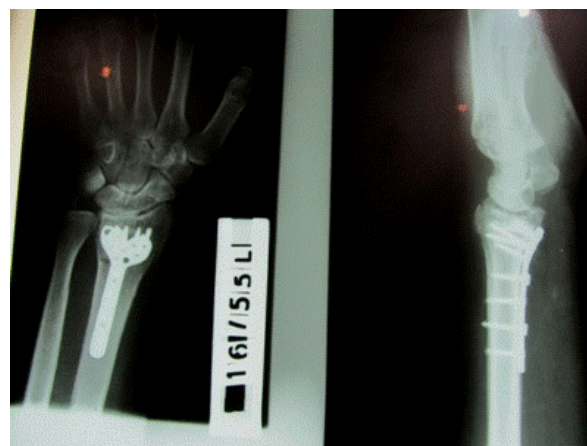


Figure 2: Post-op.

Normal RH is 11 mm and was measured as the distance between 2 lines perpendicular to the long axis of the radius, one drawn at the tip of the radial styloid and another drawn at the distal ulnar articular surface (Figure 4).

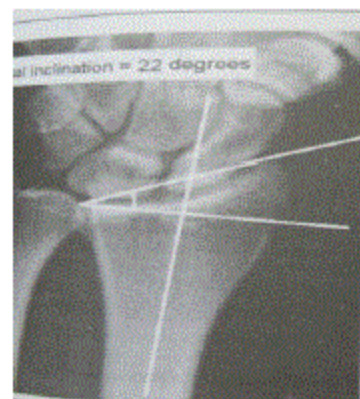

Figure 3: Radial Inclination.

In the Lat view, the VT (Volar Tilt) of the distal radius articular surface was measured [12,13]. Its normal value is 11degree (Figure 5).

These measurements were taken at three stages i.e; pre op, immediately post op and at 09 months follow up. The differences between various measurements were evaluated by One way measure ANOVA test. Statistical significance was defined as $p < 0.05$.

Clinical evaluation

Clinical evaluation was performed by the two different surgeons by determining wrist flexion, extension and grip strength in percentage in comparison with normal contra lateral limb. These findings were recorded preoperatively, immediate postoperatively (post op) and at 09 months of follow up (follow up).

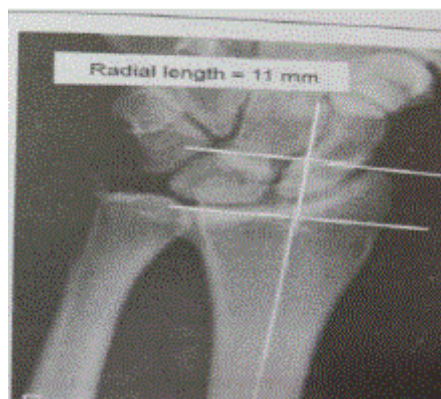


Figure 4: Radial Height.

Results

Total 42 patients underwent this surgery those included 34 males and 08 females. The mean age and Standard Deviation (SD) at the time of the injury was 40.64 ± 12.36 years (range from 19 to 70 years). Twenty two (52.4%) fractures involved right side while 20 (47.6%) fractures occurred on the left.

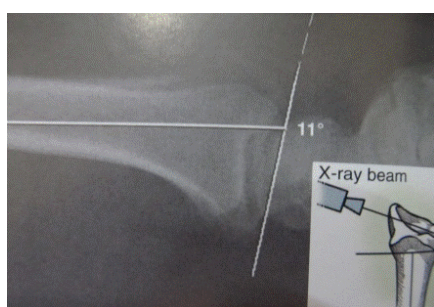

Figure 5: Volar Tilt.

According to AO classification, most of the cases were of C (n = 21) 50% and B (n = 10) 23.8% type probably because of increased incidence of high velocity injuries (Table 1).

Type of fracture	Number of cases	RH (SD) mm	RI (SD) degrees	VT (SD) degrees
Type A	11 (26.82%)	12 (0.00)	21.81 (0.603)	11.90 (0.301)
Type B	10 (23.39%)	12 (0.00)	21.5 (0.707)	11.5 (0.706)
Type C	21 (51.21%)	10.71 (0.956)	20.85 (0.573)	10.76 (1.30)

Table 3: Improvement on the basis of type of fracture, (Mean values) on the basis of type of fracture at 9 months.

So, the net improvement in RH, RI and VT at the time of 9 months follow up was 6.11 ± 2.77 , 7.26 ± 2.89 and 15.65 ± 14.26 respectively (Table 4, $p > 0.05$ for all comparisons).

Type of fracture	Frequency	Percent	Valid Percent
A2	4	9.5	9.5
A3	7	16.6	16.6
B2	1	2.3	2.3
B3	9	21.4	21.4
C1	5	11.9	11.9
C2	9	21.4	21.4
C3	7	16.6	16.6
Total	42	100	100

Table 1: Types of fracture.

Radiographic evaluation in different stages of management.

Distal radius deformity was assessed by measuring RH, RI and VT at different stages of treatment. There was significant improvement in RH and RI in initial post op stage that almost retained till 09 months of follow up (Table 2, $p < 0.05$ for all comparisons). Similarly VT was comprehensively improved from an average of -4.78° to an average of 11.40° immediately after surgery, and then remained persistent at 11.21° at the time of follow up of 09 months (Table 2).

Stage	RH (SD) mm	RI (SD) degrees	VT (SD) degrees
Pre-Op	5.35 (3.32)	13.83 (3.71)	-5.43 (11.9)
Post-Op	11.54 (0.63)	21.22 (0.736)	11.30 (0.822)
Follow up	11.42 (0.800)	21.09 (0.793)	11.22 (0.951)

Table 2: Radiological evaluations of RH, RI and VT, Mean values in three stages (Pre-op, Post Op, and Followup at 9 months).

In terms of type of fractures, all three parameters were perfectly improved in AO type A and B fractures. However, in type C fractures, final mean achievement in RH and VT was 10.71 ± 0.95 mm and 10.76 ± 1.30 degrees respectively, but the parameters were still in quite acceptable range (Table 3).

Clinical outcome

Averagely, surgeries were performed within 3 to 20 days of injury. Average hospital stay was 04 days. There was no immediate post operative complication i.e infection or nerve injury. Wrist movement was started within 1-2 weeks. Volar flexion and dorsal flexion were

87% and 84% respectively in comparison to the contra lateral side. Grip improved up to 92% of the normal side. 1 case required removal of implant after 07 months because of stiffness and persistent pain.

Stage	RH (SD) mm	RI (SD) degrees	VT (SD) degrees
Post-Op	6.19 (2.85)	7.39 (2.99)	16.75 (14.41)
Follow up	6.11 (2.77)	7.26 (2.89)	15.65 (14.26)

Table 4: Post-op and follow up stage, Net Improvement in radiological parameters.

Discussion

Distal radial fractures are being treated by traditional methods in our country i.e. Closed reduction with Cast immobilizations, external fixation and ORIF with conventional T-plate. As mentioned earlier, Studies have shown that, in the distal radius fractures, function is related to the radiographic findings [2]. Intra or Extra-articular mal-united fractures have been shown to alter function and patient satisfaction with the outcome of treatment. In a study, Arora et al. [14] mentioned an obvious clinical deformity in 77% of cast group and malunion occurred in 89% of primarily reduced fractures. Another study showed 33% patients managed with pins and plaster treatment had some complications due to their pins and 16% required reoperation [15]. External fixation is a popular method to improve the reduction of osseous deformity but cannot effectively protect comminuted distal radial fractures from loss of reduction, which may be associated with shortening and displacement [16].

Although Rozental et al. [17] showed satisfactory results with closed reduction and pin fixation for unstable distal radius fractures, but there is insufficient evidence to confirm a better reduction in displacement, functional outcome and minimum complications in patients managed conservatively [2].

Evidence in the literature indicates a strong correlation between restoration of bone anatomy and recovery of function [18], because the position of the fracture at the time of union rather than the position at the time of presentation has the greatest correlation with long-term functional results [19]. Assessment of type of fractures was vital to predict the outcome of management because comminuted intra-articular fractures of distal radius are very difficult to manage. Severe comminution is associated with shortening and re-displacement [12]. This corresponds to the visco-elastic characteristic of ligaments [20]. This prevents longitudinal traction alone from restoring volar tilt and may explain why the volar tilt of the distal radius deformity did not improve significantly with conservative measures.

For distal radius fractures, high frequencies of ligamentous injuries are commonly associated with both intra-articular and extra-articular subtypes [20]. These are the factors involved in the development of redisplacement even after satisfactory reduction and fixation with K-wires [21]. Even if no ligamentous injuries existed coincidentally and the distal radius fractures were well reduced at the time of initial management, the stretched ligaments will gradually become deformed and the stress relaxed, followed by re-displacement of well reduced fractures as proved in our previous study [22].

The locking plates result in wonderful stability even in the osteoporotic bone that's why there is increased rate of surgical procedures for fractures that had rather been managed conservatively in the past [10]. The use of ORIF with a volar fixed angle implant

resulted in stable fixation, allowing early postsurgical wrist motion. Moreover, intra-articular step-off, volar tilt and radial height were better in ORIF group and early wrist ROM was initiated without loss of reduction [23]. Wright et al. [23] showed in their study averaged 5 degrees volar tilt and 25 degrees radial inclination improvement while ORIF with volar plating significantly improved these parameters in our study. In a study by Figl et al. [6] 75% patients had no radial shortening and 25% had a mean radial shortening of only 1.8 mm compared to our study where 50% maintained their height while other 50% lost only 0.9mm. While in comparison to on average 22 degrees radial inclination and 6 degree volar tilt our study showed 21.09 degrees and 11.22 degrees respectively [6].

Another study showed that radiographic results (VT, RH and RI) were significantly better in ORIF group treated by using fixed angle volar plate rather than in those treated by cast immobilization [14].

The purpose of our study was to establish the stabilization effect of low profile fixed angle volar plate on fractures of the distal radius in our set up. As we have noted, the bony deformity of the distal radius showed significant improvement in the measurements of RH, RI and VT immediately after reduction and fixation with fixed angle volar plate that was maintained successfully till follow up of 09 months (Tables 2 and 3). We found that Intra-articular fractures i.e., Type B and C treated by fixation with fixed angle volar plate significantly improved the RH, RI and VT. Fractures with less comminution got perfect correction after fixation that persisted till follow up of 09 months (Table 4). Our results are well comparable with many international studies rather showed better findings in VT [6,23-25].

However conservative measures are acceptable even with disability in elderly people and patients with dementia or multiple medical comorbidities [26].

Conclusions

There is increased tendency of young patients to sustain comminuted distal radius fractures due to high energy trauma. Conservative measures may improve the reduction of type B and C fractures but cannot assure the maintenance of reduction. Most patient suffering from distal radius fractures of Type B and C treated conservatively fall into malunion.

Restoration of anatomy is the hall mark of this surgery. The peculiar characteristics of variable angle volar plate provide the best alternative to the traditional techniques of distal radius fixation which is strong enough to allow for early postoperative motion and the functional outcome is credible.

References

1. Wigg AE, Hearn TC, McCaul KA, Anderton SM, Wells VM, et al. (2003) Projections of distal forearm fractures admitted to hospital in Australia. *J Trauma* 55: 87-93.
2. Handoll HH, Huntley JS, Madhok R (2007) External fixation versus conservative treatment for distal radial fractures in adults. *J Bone joint Surg Am* 90: 451-454.
3. McQueen MM, Hajducka C, Court-Brown CM (1996) Re-displaced unstable fractures of the distal radius: a prospective randomized comparison of four methods of treatment. *J Bone Joint Surg Br* 78: 404-409.
4. Short WH, Palmer AK, Werner FW, Murphy DJ (1987) A biomechanical study of distal radial fractures. *J Hand Surg Am* 12: 529-534.

5. Ejaz AM (2012) Closed reduction and POP immobilization for Colles' fracture under haematoma block and sedation as day care. *Pak Armed Forces Med J* 62: 328-332.
6. Fiq IM, Weninger P, Liska M, Hofbauer M, Leixnering M (2009) Volar fixed angle plate osteosynthesis of unstable distal radius fractures: 12 months results. *Arch Orthop trauma Surg* 129: 661-669.
7. Adams BD (1993) Effects of radial deformity on distal radio-ulnar joint mechanics. *J Hand Surg Am* 18: 492-498.
8. Aro HT, Koivunen T (1991) Minor axial shortening of the radius affects outcome of Colles' fracture treatment. *J Hand Surg Am* 16: 392-398.
9. Fernandez DL, Geissler WB (1991) Treatment of displaced articular fractures of the radius. *J Hand Surg Am* 16: 375-384.
10. Kreder HJ, Agel J, McKee MD, Schemitsch EH, Stephen D, et al. (2006) A randomized, controlled trial of distal radius fractures with metaphyseal displacement but without joint incongruity: closed reduction and casting versus closed reduction, spanning external fixation, and optional percutaneous K-wires. *J Orthop Trauma* 20: 115-121.
11. Clayton RAE, Gaston MS, Ralston SH, Court-Brown CM, McQueen (2009) Association between decreased bone density and severity of distal radial fractures. *J Bone Joint Surg AM* 91: 613-619.
12. Xu GG, Chan SP, Puhaindran ME, Chew WY (2009) Prospective Randomized Study of Intra-Articular Fractures of Distal Radius: Comparison between External and Plate fixation. *Annals Academy of Medicine* 7: 600-605.
13. Rajan S, Jain S, Ray A, Bhargava P (2008) Radiological and functional outcome in extra-articular fractures of lower end radius treated conservatively with respect to its position of immobilization. *Indian J Orthop* 42: 201-207.
14. Arora R, Gabl M, Gschwentner M, Deml C, Krappinger D et al. (2009) A comparative study of clinical and radiologic outcomes of unstable colles type distal radius fractures in patients older than 70 years: non operative treatment versus volar locking plating. *J Orthop Trauma* 23: 237-242.
15. Champman DR, Bennett JB, Bryan WJ, Tullos HS (1982) Complications of distal radial fractures: pins and plaster treatment. *J Hand Surg Am* 7: 509-512.
16. Sun JS, Chang CH, Wu CC, Hou SM, Hang YS (2001) Extra-articular deformity in distal radial fractures treated by external fixation. *Canadian journal of Surgery* 44: 289-294.
17. Rozental TD, Blazer PE, Franko OI, Chacko AT, Earp AT et al. (2009) Functional outcomes for unstable distal radial fractures treated with open reduction and internal fixation or closed reduction and percutaneous fixation: a prospective randomized trial. *J Bone Joint Surg AM*; 91: 1837-1846.
18. Rauis A, Ledoux A, Thiebaut H, Van der Ghinst M (1979) Bipolar fixation of fractures of the distal end of the radius. *Int Orthop* 3: 89-96.
19. Sun JS, Chang CH, Wu CC, Hou SM, Hang YS (2001) Extra-articular deformity in distal radial fractures treated by external fixation. *Canadian Journal of Surgery* 4: 289-294.
20. Bartosh RA, Saldana MJ (1990) Intraarticular fractures of the distal radius: a cadaveric study to determine if ligamentotaxis restores radiopalmar tilt. *J Hand Surg Am* 15: 18-21.
21. Luscombe KL, Chaudhry S, Dwyer JS, Shanmugam C, Maffulli N (2010) Selective Kirschner wiring for displaced distal radial fractures in children. *Acta Orthop Traumatol Turc* 44: 117-123.
22. Masood K, Jamil M, Pasha FI, Qureshi KZ, Malik NI (2013) Is casting an acceptable treatment approach for distal radius fracture that has undergone a satisfactory closed reduction? *JUMDC* 4: 1-6.
23. Wright TW, Horodyski M, Smith DW (2005) Functional outcome of unstable distal radius fractures: ORIF with a volar fixed angle titanium plate versus external fixation. *J Hand Surg AM* 30: 289-299.
24. Smith DW, Henry MH (2005) Volar fixed-angle plating of distal radius. *J AM Acad Orthop Surg* 13: 28-36.
25. Rozental TD, Blazer PE (2006) Functional outcome and complications after volar plating for dorsally displaced, unstable fractures of distal radius. *J Hand Surg AM* 31: 359-365.
26. Blakeney WG (2010) Stabilization and treatment of Colles' fractures in elderly patients. *Clin Interv Aging* 5: 337-344.