

Case Report

Open Access

Radial Nerve Palsy after Humeral Fracture: To Explore or Not to Explore? - A Case Report

Ana Costa Pinheiro*

Unidade Local de Saúde do Alto Minho, Viana Castelo, Portugal

*Corresponding author: Ana Costa Pinheiro, Unidade Local de Saúde do Alto Minho, Viana Castelo, Portugal, Tel: 914335860; E-mail: ana.alexandra.pinheiro@gmail.com

Received date: December 04, 2015; Accepted date: February 03, 2016; Published date: February 05, 2016

Copyright: ©2016 Pinheiro AC. This is an open-access article distributed under the terms of the Creative Commons Attribution License, which permits unrestricted use, distribution, and reproduction in any medium, provided the original author and source are credited.

Abstract

The incidence of radial nerve injuries varies from 2-17% and humeral fracture is the most common cause in young adults. The treatment of radial nerve damage, especially in cases of fracture, remains a challenge.

The authors report a case of radial nerve palsy related to humeral shaft fracture and shall revise the literature about their treatment. Whether fracture or associated radial nerve injury, were treated conservatively, and the patient referred, of course, to Physiatry, to start intensive functional recovery of the affected upper limb. At 5-6 months after fracture, patient maintains radial sensory and motor deficits, and it was proposed surgical exploration of the radial nerve, which was scheduled, because a week before the alleged scheduled surgery, he demonstrated a recovery, and has fully function of the radial nerve after 2 weeks.

Humeral shaft fractures are treated mostly conservatively, the radial nerve usually suffers neuropraxia and their function returns spontaneously after fracture healing, as happened in this case.

The nerve exploration is reserved for cases in which there is no recovery of nerve function 3-4 months or a little more, after the fracture consolidation. Thus, nerve routine operation would subject many patients to unnecessary complications of surgery.

Keywords: Palsy; Radial nerve injury; Humeral fractures; Radial neuropathy/etiology; Radial neuropathy/therapy; Treatment outcome

Introduction

The incidence of radial nerve injuries varies from 2-17%, and humeral fracture is the most common cause in young adults [1]. The treatment of radial nerve damage, especially in cases related to fracture, still remains a challenge [1,2]. Neuropraxia is the most common injury in closed humeral fractures while neurotmesis is more associated with open fractures [3,4]. It is known that 85-90% of radial nerve lesions express spontaneous recovery within 3 months, on average, after seven week [5]. So if nerve function does not return within three to four months, nerve surgical exploration should be performed [3].

The authors report a case of radial nerve palsy associated with humeral shaft fracture where both lesions were treated conservatively, taking the patient initiated the recovery of radial nerve function after 6 months of the initial injury. It is also reviewed the literature on the treatment of these lesions.

Case Report

Male patient, 16 years old, without pathological antecedents. He appealed to the Emergency Service (ES) after falling from heights (about a meter), which resulted in fracture of the right humerus (Figure 1). It was made pending plaster cast immobilization (Figure 2) and he was discharged to continue treatment on an outpatient basis. It

has not been registered neurological status or reduction maneuvers in the ES. Three days after fracture he appealed to the ES for very severe edema of the right forearm and hand, verifying radial nerve palsy, with no other signs of compartment syndrome. In the absence of knowledge of neurological injury installation time, it was placed neuropraxia hypothesis. Nuclear Magnetic Resonance held (NMR) of the right arm on suspicion of radial nerve injury and entrapment whose report confirmed extensive hematic infiltration of muscle and surrounding structures groups. The radial nerve passing along the distal end of the top, lying surrounded by edematous/haematic changes and was not sure what path to your present conditions to be compressed. It would also not positioned between the tops of the fracture and thus did not show signs of entrapment, in the study position. So it was not possible to make a concrete assessment, if there was or not separation/nerve section, apparently not, but the assessment was inconclusive, marked by infiltration around the same, there diffuse swelling of the muscle groups. After reviewing the literature it appears that most of these injuries are neuropraxic and spontaneous recovery is the rule, and it was decided by the conservative treatment. The patient was oriented to physiatry for functional recovery and kept the cast immobilization until fracture healing (Figure 3).

At four months, despite intensive therapy, and for maintaining radial paresis, repeated X-ray and NMR (Figures 4 and 5) and nerve nervous holding determined. Inexplicably after about six months of the traumatic episode it was found complete and spontaneous reversal of the radial paresis in two weeks (the week before the alleged planned surgery).

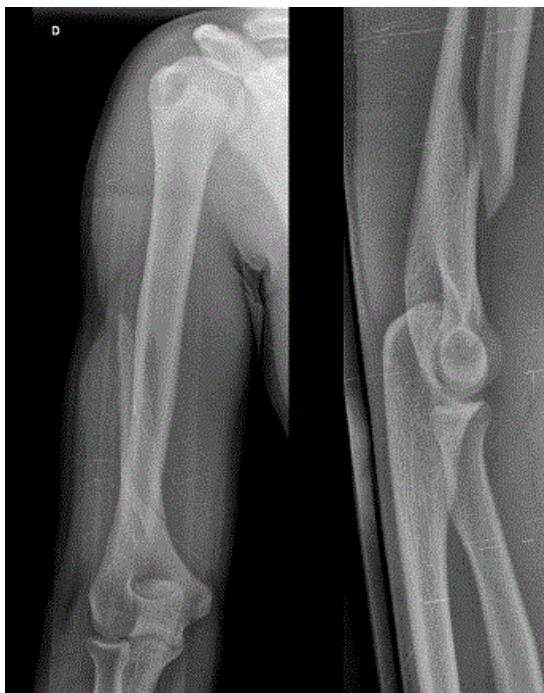


Figure 1: Right humeral shaft fracture at the entrance to the ER, AP and perfil.

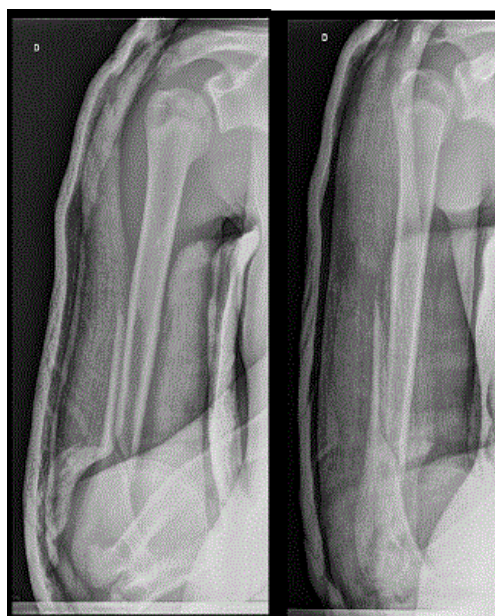


Figure 2: It was performed closed reduction and upper limb cast immobilization.

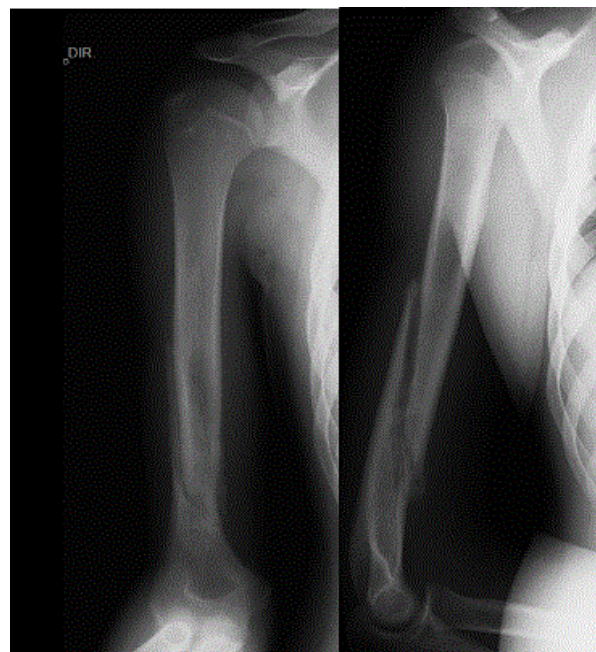


Figure 3: X-ray performed after 6 weeks of cast immobilization, during follow-up.

Today, 14 months after the trauma, the patient presents with mobilization and range of motion for daily living activities, professional and recreational (keeper in federated football team).

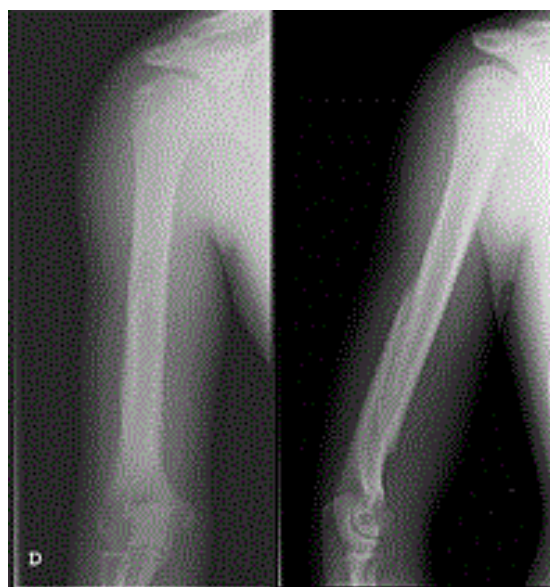


Figure 4: Radiography performed after four months of injury, during follow-up, showing fracture healing.

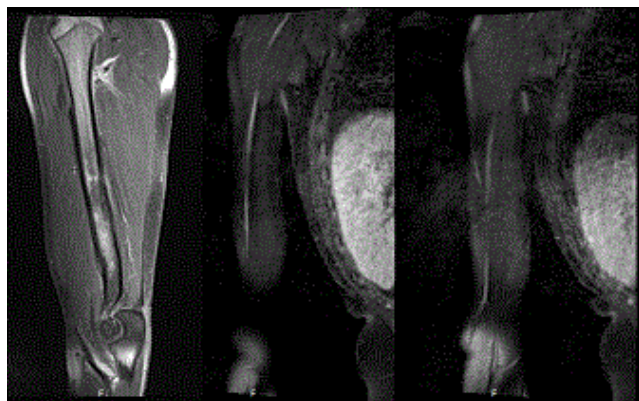


Figure 5: Nuclear Magnetic Resonance Images, performed after four months of injury, during follow-up: Bone hypertrophic changes in the fracture region determine stretch in the radial nerve pathway in the middle third of the posterior lateral aspect of the arm, at the crossroads with the humeral shaft, showing thinning and diffuse hyperintense, asymmetric relative to the proximal and distal nerve course. In study after contrast is observed discrete hyper signal of this segment for possible post-traumatic inflammation. The proximal and distal nerve segment has characteristics maintained.

Discussion

Humeral shaft fractures even coexist with radial neurological injury are treated mostly conservatively, supporting the wrist and fingers in a dynamic splint because the nerve usually suffers neuropraxia and function usually returns spontaneously after the consolidation of fracture [6]. Ogawa and Yoshida [7] reported 100% recovery of the radial palsy studied in a large series, while Pollock [8] described a lower recovery rate of 90% in closed fractures. In turn, Sarmiento [9] reported 100% recovery rate in 85 patients with fracture of the distal humerus associated with radial nerve injury [4]. However, it is noted that there is evidence that the prognosis is worse in open fractures and in injuries resulting from high energy mechanism [4,10]. The surgery of the radial nerve is thus reserved for cases in which there was no recovery of nerve function after three to four months (or even after 6 months, as noted in this case), after consolidating fracture. Routine operation of the radial nerve would subject many patients to unnecessary surgery, and their associated complications [11-14]. Moreover, it is not proven that the exploration and early repair of the radial nerve promote a better result when faced with a repair posteriorly [15]. The literature supports the conservative treatment of most closed fractures of the humerus associated with the radial nerve palsy, including Holstein-Lewis fractures [15]. The surgery of the radial nerve should be performed when the bone fixation is indicated and open fractures [11-16]. To point out that the treatment of a "secondary palsy" is controversial and is valid both options, nerve exploration or conservative treatment [16]. This case show the difficulty of interpreting the diagnostic images, including NMR, and warn that a discouraging report of NMR indicating the probable nerve section, not always guides the surgeon towards the best therapeutic practice, for this patient would be submitted to unnecessary surgery if not expected by 6 months follow-up after fracture.

Table 1 presents a treatment algorithm for humeral shaft fractures associated with paresis of the radial nerve, based on the literature review performed.

Humeral shaft fracture	
Open reduction and internal fixation	Explore the nerve
Radial nerve palsy associated with open fracture	Explore the nerve
Radial nerve palsy associated with closed fracture	Observe
Palsy after fracture reduction	Observe? Explore?

Table 1: Algorithm of treatment for humeral shaft fractures associated with paresis of the radial nerve, based on the literature review performed.

The objective of this study is to alert the medical community that following the guidelines does not always lead to the expected results in the expected time period, because in this case the functional recovery of the member occurred only six months after the initial trauma. It excels even the importance of a thorough physical examination of the patient in the ES, so that we can make the diagnosis and assess the degree of initial nerve damage to accompany the further development of radial injury and processed thus the most appropriate treatment.

It also alert highlights the importance of making the neurological examination all humeral fractures, since, for example, the differentiation between previous paresis or subsequent radial nerve fracture reduction may be relevant in the direction of the most appropriate treatment, which today is controversial.

References

1. Niver GE, Ilyas AM (2013) Management of radial nerve palsy following fractures of the humerus. *Orthop Clin North Am* 44: 419-424.
2. Shao YC, Harwood P, Grotz MR, Limb D, Giannoudis PV (2005) Radial nerve palsy associated with fractures of the shaft of the humerus: a systematic review. *J Bone Joint Surg Br* 87: 1647-1652.
3. Clifford R (2014) Radial Nerve Palsy following Frx of the Humerus. *Wheels text book of orthopaedics*.
4. McKnee M, Larsson S (1996) Humeral-shaft-fractures. (4th edn), Lippincott-Raven Publishers, Philadelphia, USA, 1043-1045.
5. Li Y, Ning G, Wu Q, Wu Q, Li Y, et al. (2013) Review of literature of radial nerve injuries associated with humeral fractures-an integrated management strategy. *PLoS One* 8: e78576.
6. Ogawa K, Yoshida A (1998) Throwing fracture of the humeral shaft. An analysis of 90 patients. *Am J Sports Med* 26: 242-246.
7. Pollock FH, Drake D, Bovill EG, Day L, Trafton PG (1981) Treatment of radial neuropathy associated with fractures of the humerus. *J Bone Joint Surg Am* 63: 239-243.
8. Sarmiento A, Horowitz A, Aboulaia A, Vangsness CT (1990) Functional bracing for comminuted extra-articular fractures of the distal third of the humerus. *J Bone Joint Surg Br* 72: 283-287.
9. Ring D, Chin K, Jupiter JB (2004) Radial nerve palsy associated with high-energy humeral shaft fractures. *J Hand Surg Am* 29: 144-147.
10. Dolenc V (1976) Radial nerve lesions and their treatment. *Acta Neurochir (Wien)* 34: 235-240.
11. Duncan DM, Johnson KA, Monkman GR (1974) Fracture of the humerus and radial nerve palsy. *Minn Med* 57: 659-662.

-
12. Böstman O, Bakalim G, Vainionpää S, Wilppula E, Päätiälä H, et al. (1986) Radial palsy in shaft fracture of the humerus. Acta Orthop Scand 57: 316-319.
 13. Mast JW, Spiegel PG, Harvey JP, Harrison C (1975) Fractures of the humeral shaft: a retrospective study of 240 adult fractures. Clin Orthop Relat Res : 254-262.
 14. Postacchini F, Morace GB (1988) Fractures of the humerus associated with paralysis of the radial nerve. Ital J Orthop Traumatol 14: 455-464.
 15. Heckler MW, Bamberger HB (2008) Humeral shaft fractures and radial nerve palsy: to explore or not to explore...That is the question. Am J Orthop (Belle Mead NJ) 37:415-419.
 16. Crenshaw A (2013) Fracture of humeral shaft with radial nerve palsy. (8th edn), Mosby Year Book, St. Louis, USA, 1016.