

# Radial Artery Cannulation and Transradial Access for Percutaneous Coronary Angiography and Interventions: From Experience to Expertise of A Single Cardiac Centre

Dangoisse Vincent<sup>1\*</sup> and Guédès Antoine<sup>1</sup>

<sup>1</sup>Departement Cardiovasculaire Cliniques Universitaires, U.C.L. de Mont-Godinne, Yvoir, Belgium

## Historical Background

The radial artery is one of the most useful allies of modern medicine. Since decades, it has been punctured for direct blood gas analysis and used by anesthesiologists and intensive care providers for continuous and sometimes prolonged hemodynamic monitoring. The dual blood supply of the hand also allows removal of this wonderful vessel for use as an arterial graft [1] and arteriovenous shunts are created at its proximal level for permanent dialysis. The anatomical features of the radial artery explain its advantages. At the level of cannulation, about 1 to 2 cm proximal to the radial bone styloid, the artery lies in front of the radius bone: this hard background makes the compression easy and very efficient. Secondly, at the puncture level, there is no nerve-sensitive or motor- so no nerve injury can occur even after several puncture attempts or even compression. Thirdly, the artery is fully connected through palmar arches with the ulnar artery, thus saving hand from ischemia in case of radial artery occlusion. Finally, the compression site is "joint-free", thus, hand, forearm and the patient himself are free to move. At the puncture level, the artery lies very superficial and the skin is not too sensitive: good anesthesia requires only 1 subcutaneous cc of lidocaine.

Campeau [2] pioneered the transradial access (TRA) for coronary angiography in 1989, followed a few years later by Kiemeny for coronary interventions [3]. TRA for percutaneous coronary angiography and intervention is actually increasing in many countries [4], but not in the U.S. [5]. A few reasons related to its anatomical properties explain the move from the classical transfemoral access (TFA). Safety of this route is the first and main argument: TRA inexpensively reduces bleeding and access site complications associated with percutaneous coronary interventions [6].

Furthermore, due to the possibility of immediate ambulation, TRA enhances patient comfort and reduces nursing staff workload. Hospital stay and cost are both minimized, again due to quicker recovery and reduction of vascular problems. The move from TFA to TRA for cardiac catheterization requires at the individual level investment in the new task of radial artery puncture and cannulation. At the institutional level, the move is most of the time initiated by a «believer» [7] as happened in our cath lab, when a newly recruited operator started TRA in November 2003. With the help of a second operator one year later, they started in 2005 a nation-wide TRA teaching program and speeded up the conversion for the country, as depicted in Figure 1: in 2010, TRA accounted for 24% of Belgian PCI, with more than 20000 cardiac catheterizations via TRA (~ 30%).

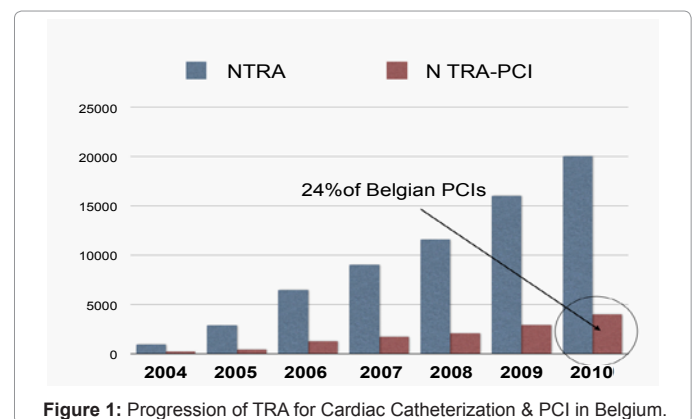
In January 2005, both operators started to prospectively study the success rate of transradial access (TRA) when proposed as a by default artery access for coronary angiography and percutaneous coronary interventions. The protocol required to attempt both radial arteries before crossing over to TFA. The study was also designed to provide information about ease of cannulation, ease of catheter manipulation and causes of failed radial attempt. Results were published in

September 2010 [8]: after 1826 cardiac procedures, they conclude that any percutaneous coronary diagnostic or interventional procedure can be performed via the radial route with a high success rate (98.8% in the study) and an extremely low complication rate with regard to vascular or local bleeding problems. They also conclude that there is no specific population of patients that is unlikely to take advantage of the technique in terms of feasibility or safety. In the study population, best predictors of radial attempt failure, by multivariate analysis, were firstly, year of the study (proof of a prolonged learning curve, operator performance better in 2007 than in 2005) with an odds ratio of 0.6, 95% c.i.0.4-0.8,  $p < 0.001$ ; secondly, presence of peripheral arterial disease (generalized arteritis, involving also the radial artery, odd ratio of 1.8, 95% c.i. 1.1-2.8,  $p = 0.016$ ), thirdly difficult access as judged by pre cath clinical evaluation (odds ratio 2.5, 95% c.i. 1.3-4.9,  $p = 0.006$ ) and finally small vessel size as assessed by pre cath clinical evaluation (odds ratio 2.6, 95% c.i. 1.4-5.0,  $p = 0.003$ ). It is interesting to note that all predictors are available at the bedside.

We provide here some of the data gained during this study and which has not been previously published. We will also update some of the information with new results from this ongoing study.

## Radial Artery Cannulation

The Seldinger technique for artery cannulation is the by default



\*Corresponding author: Dangoisse Vincent, C H U Mont Godinne, U C L, Yvoir, Belgium, E-mail: [vincent.dangoisse@uclouvain.be](mailto:vincent.dangoisse@uclouvain.be)

Received December 02, 2011; Accepted February 10, 2012; Published February 13, 2012

Citation: Vincent D, Antoine G (2012) Radial Artery Cannulation and Transradial Access for Percutaneous Coronary Angiography and Interventions: From Experience to Expertise of A Single Cardiac Centre. J Anesth Clin Res 4:322. doi:10.4172/2155-6148.1000322

Copyright: © 2012 Vincent D et al. This is an open-access article distributed under the terms of the Creative Commons Attribution License, which permits unrestricted use, distribution, and reproduction in any medium, provided the original author and source are credited.

technique for operators moving from TFA: artery is first punctured with a bore metal needle and the vessel is thereafter wired through the needle. While the metallic wire lays in the vessel, the needle is removed and a sheath (dilator within an introducer) is introduced over the metallic wire. This technique is safe and very efficient for large vessel like the femoral artery. Presence of an arterial sheath allows quick exchange of multiple catheters, as needed according to the cardiac procedure. The Seldinger technique does not require transfixion of the vessel: the wire can be forwarded once the tip of the needle has reached the arterial lumen through puncture of the anterior wall. For vessels of the size of the femoral artery, there is some risk when the posterior artery wall is injured by a large needle. Usual access needles for femoral artery puncture are 18 Gauge.

Most of the manufacturers of radial introducers still propose in their standard kit a 21 G access needle with a short metallic 0021” straight or J wire. Many kits dedicated for intensive care or anesthesiologist use are derived from the Seldinger technique.

When addressing small vessels like the radial artery, puncturing and particularly wiring the vessel with this technique is challenging, in part due to the tiny effective lumen and to the adrenergic-rich innervation of the artery, making the vessel very prone to spasm. Very often, wiring fails at the needle’s entry in the artery.

There exists another technique for radial artery cannulation, which comes from the nursing world: the over-the-needle cannula system. The technique consists of direct «intubation» of the vessel by a plastic cannula overlying the needle: the cannula is pushed in the vessel over the needle as soon as the lumen is reached by the tip of the needle. Once the cannula is properly inserted in a vein, it allows direct use for i.v. infusion or blood sampling. Once in an artery, the cannula can be used directly for short term hemodynamic monitoring, but for cardiac catheterization, the cannula greatly facilitate the vessel’s wiring. Thereafter, the cannula is replaced by a sheath over the wire just in place.

Initially, we used the Seldinger technique, quickly realizing that the kind of needle and the kind of wire matter. It is better to use a short needle: we use a 2.5 cm thinwall 21 G needle with a 0.018” 60 cm Nitinol floppy J wire.

We rapidly evolved to the over-the-needle cannula system with a double wall through-and-through puncture technique: We now

routinely use a 22 G “surflow i.v. catheter”. We want to emphasize one point: the operator must not fear transfixing the artery with this tiny needle (Figure 2): once arterial blood emerges at the needle hub, the needle is further advanced, puncturing the posterior wall. The needle is then removed and the plastic cannula is gently pulled back until appearance of blood back-flow. The puncture of the posterior wall of this small vessel will not translate into local bleeding: the sheath does the hemostasis during the cath, and after cath, usual compression will obviously achieve the same level of effectiveness for both the anterior cannula entry site and the small posterior puncture hole.

It is better not to puncture the radial artery too distally [9]: wiring is more difficult (diminutive caliber for more distal vessel, distal bifurcation) and we have to keep in mind that a compression device has to be placed at the end of the procedure.

When inserting the sheath, care must be taken concerning the transition between wire and the sheath’s dilator: matching the size of the wire to the size of the dilator tip will reduce the injury at the entry level.

Re-analyzing our causes of failed radial attempt with exclusion of coronary artery bypass grafted patients (we address this particular population in a submitted abstract to the next ACC -i2 summit) our most recent data (Figure 3) shows that experience allows us to overcome obstacles found on the way to the coronary ostia: the main cause of failure still is the act of puncturing the artery and more importantly wiring the needle or the cannula once blood emerges from the needle : this last cause stands actually as the primary reason (10 out of 14 failures (71%) for the last 410 radial attempts of one operator).

Regarding ease of cannulation, figure 4 depicts contemporary TRA values compared to ones dating a few years back. The proportion of anticipated difficult cannulation (approximately 14 %) or of perceived small radial arteries (~20 %) is similar but cannulation stays easier to perform than expected. Yet, with time, and despite addressing more delicate radial arteries (sometimes a Doppler signal is the only indication of the radial artery’s presence) we improve our global success rate: compared to the published results of the study, we observe a decline in the crossover to the other radial artery (actually 4, 8%) and to transfemoral access (less than 1%).

Our data showing that cannulation often goes smoother than anticipated should reassure the beginner. Furthermore, even if we

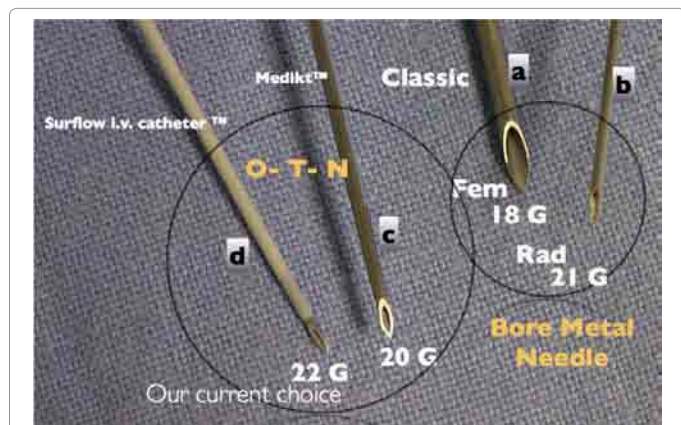

Figure 2: Comparison between classic bore metal needle-18G for femoral puncture(a), 21G for radial access(b) and Over-the-needle cannula system, from Medikit TM (transparent cannula, c) and Terumo (surflow i.v. catheter TM,d). Vessel wall injury is directly linked to the material used.

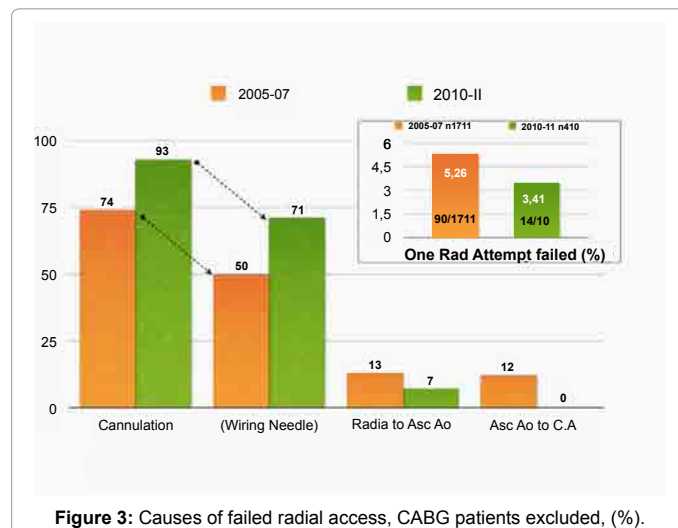


Figure 3: Causes of failed radial access, CABG patients excluded, (%).

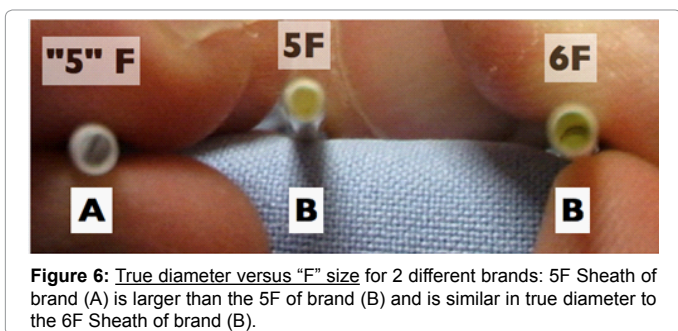
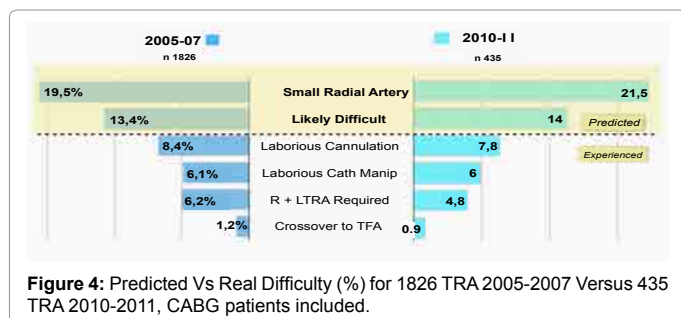


Figure 6: True diameter versus "F" size for 2 different brands: 5F Sheath of brand (A) is larger than the 5F of brand (B) and is similar in true diameter to the 6F Sheath of brand (B).

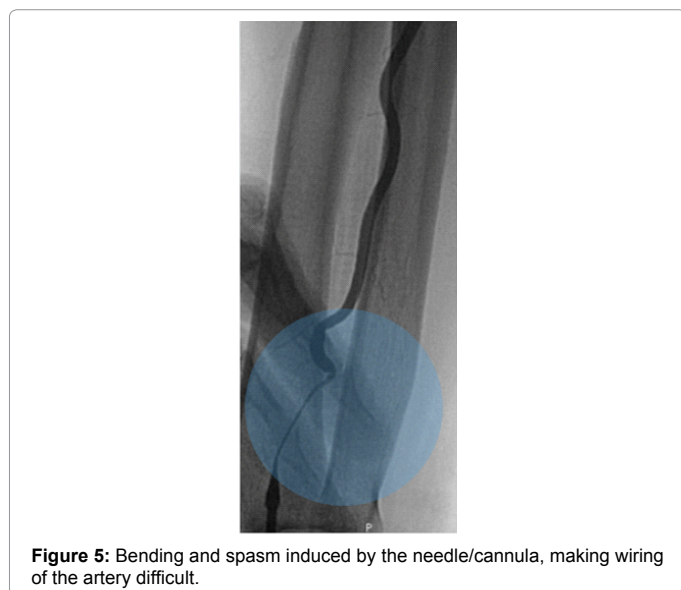


Figure 5: Bending and spasm induced by the needle/cannula, making wiring of the artery difficult.

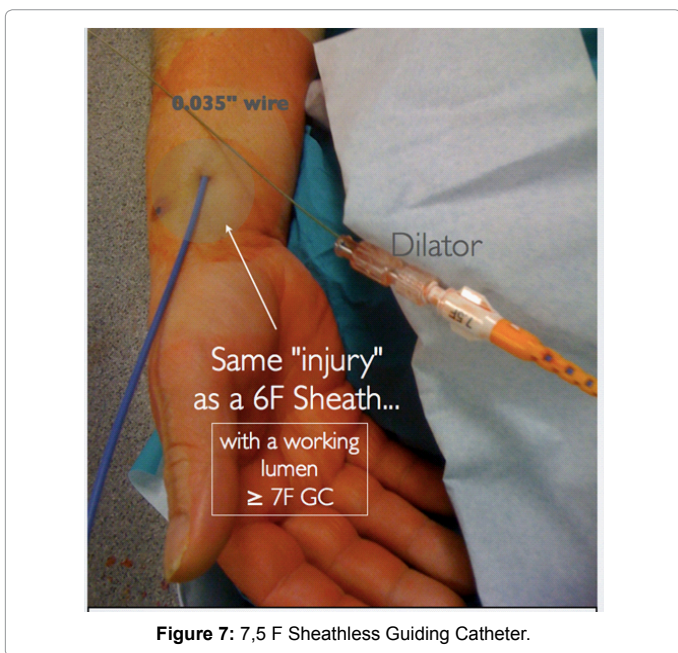


Figure 7: 7.5 F Sheathless Guiding Catheter.

also had confirmed presence of a learning curve [8], success rate of TRA coronary angiography, at the beginning, is expected to be at least around 90%, similar to that of the father of TRA [2]. Also, it has to be said that a failed radial puncture has no clinical consequence.

### Recent Advances in the Radial Artery Catheterization Equipment

Quick progression of TRA in term of market share has prompted development of dedicated equipments, like introducers (sheath), wires, coronary diagnostic catheters and guiding catheters for coronary interventions. Careful selection of the material helps to succeed and to minimize the radial artery injury.

As said before, use of the over-the-needle cannula system enhances the success rate of inserting a sheath in the radial artery: once the cannula is inserted, a large variety of wires can easily be exchanged. New hydrophilic wires and wires used for coronary angioplasty allow cannulation of very diseased and tortuous arteries. These useful wires are not recommended with bare metal needles (the coating can be "peeled"). Moreover, the plastic cannula is less prone to displace the artery at its entry site than the bare metal needle: such displacement bends the vessel at the tip of the needle and explains why the wiring frequently fails at the needle tip (Figure 5).

Dedicated and hydrophilic coated sheaths minimize vessel injury at the time of artery entry and during catheter manipulation [10]. Be aware that from one manufacturer to the other, "5F" sheaths in fact size up between 5.5 to 6F (Figure 6): the latter will of course increase

the vascular burden at the artery entry level and all the way along the sheath.

Dedicated catheters for coronary angiography [11] allow faster diagnostic procedures and lessen the need for catheter exchange. Size of guiding catheters for PCI has been reduced without compromising nor the effective inner diameter, nor the required back-up support, thanks to specific shapes and enhanced body construction [12]. Profile of balloons and stent delivery catheters have been reduced: actual 6F guiding catheters allow kissing balloon technique, atherectomy with Rotablator or thrombectomy. Recently, sheathless guiding catheters have reached the market: for people relying on large lumen guiding catheters, sheathless material offers an effective solution withdrawing any residual restriction related to patient's radial artery size [13].

6F sheaths accounted for 49% of our initial 731 PCI (2005-2007) versus for only 30% nowadays. We are now starting to use sheathless guiding catheters, available in 6.5 (equivalent to a 5F introducer for the radial artery) and 7.5F sizes, equivalent to a 6F sheath (Figure 7). A 5F sheathless guiding catheter (same arterial injury as a 4F sheath) will soon reach our market.

Let us put some emphasis on the potential this technology offers: with adequate shapes, we could in theory further reduce the injury to the radial artery for the 70% of PCIs we now perform using 5F guiding catheters: 4F sized material will fit any patent radial artery. It should

also be reassuring for new radial operators that success rate of TRA-PCI is now largely reported as being similar to TFA-PCI [5,14,15] including for PCI of the most complex anatomies like chronic total occluded vessels [16] and left main disease [17].

## Complications

TRA mainly exposes the patient to access failure, secondly to a vascular perforation which could occur all the way to the aorta and in the upper extremity, the local bleeding ultimately leads to a compartment syndrome, and thirdly to arterial occlusion.

We already addressed the problem of radial attempt failure [8]: this problem is a quite trivial complication with no clinical consequence.

When recognized during catheter or wire manipulation, vascular perforation is easily managed with immediate pressure bandage dressing and provided that the true vessel lumen is engaged by a wire, a catheter may be gently forwarded, with completion of the ongoing procedure: presence of the catheter at the site of the vascular leak acts as a sealer [18]. In a few cases and applying both techniques (external pressure bandage dressing plus catheter sealing) we successfully finished the planned procedure without subsequent local harm [Figure 8].

The most dramatic but hopefully very rare complication of TRA is occurrence of a compartment syndrome [19]. This dramatic complication is the result of inadequate attention to a continuing arterial bleeding arising from perforation of the radial or the brachial artery (the main vessel or branches): the leak is often at the mid forearm level (tip of the introducer); it is rarely seen at the puncture level. Arterial bleeding occurring in a soft tissue ultimately leads to vascular and nerve compression with subsequent severe ischemia and loss of sensitivity.

Since the beginning of TRA in our Hospital, more than 10.000

TRA have been completed and compartment syndrome occurred on 4 occasions. The first two were managed surgically with fasciotomy, resulting in extensive skin opening and subsequent scarring. We successfully addressed the last two cases with conservative medical techniques, with good and prompt results. The medical management we used was based on the two evident principles the surgeon usually applies. First of all, the arterial bleeding must be actively stopped and secondly, accumulated blood has to be removed as quickly as possible. The best way to prevent occurrence of the compartment syndrome is to dress a vigorous pressure bandage as soon as possible for any new localized pain or bump or evident hematoma occurring after a TRA. For many years, our nursing staff had the instruction to apply such a bandage dressing quickly and before calling the doctor. This technic of pressure bandage dressing [19,20] works also in cases of compartment syndrome. The initial site of the pain or of the hematoma can localize the bleeding site (where the pressure bandage dressing must be applied) but in one of the two cases, we localized the origin of bleeding by echography. At the same time as the compression is applied, a very easy and efficient drainage is obtained if you maintain the arm and the forearm elevated. Of course, strong pain relief medications have to be prescribed and return of blood flow to the hand must be carefully monitored.

The most frequent complication of TRA is radial artery occlusion. Even if clinically benign and silent most of the time, it prevents re-use of the same artery and therefore this complication has to be reduced as much as possible. The risk of occlusion is directly linked to the degree of vessel injury. The best way to avoid occlusion is through techniques, materials and medications which minimize vessel aggression.

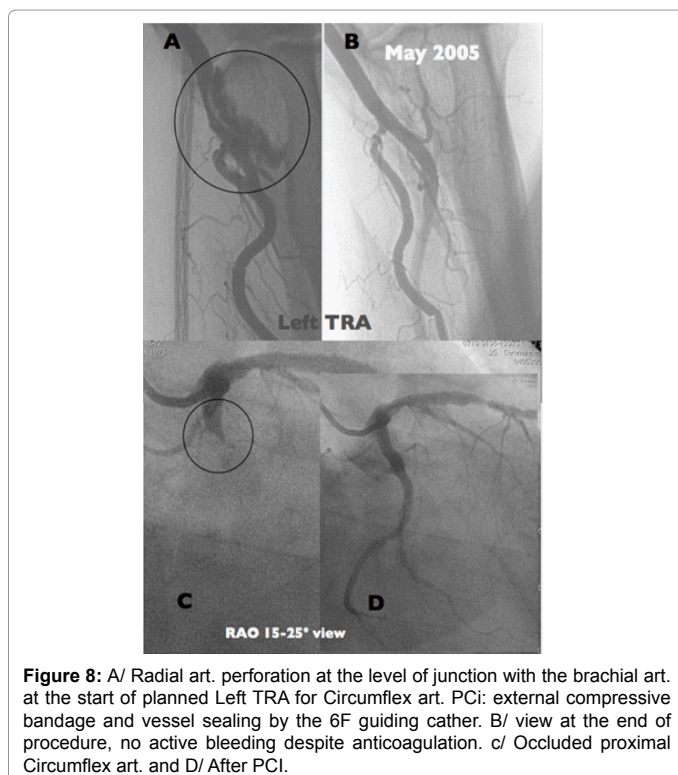
Heparin, given IV or directly in the arterial sheath, is mandatory for every TRA, even for limited diagnostic investigations [21]. Avoidance of this step leads to rapid artery occlusion. Given the ease of effective compression and the rarity of major vascular problem, 4 to 5.000 Units of Heparin are given for each TRA in our practice. Most laboratories use calcium channel blockers to prevent spasm and we routinely use intra arterial verapamil (2.5 mg).

As pointed out above, careful selection of the material and reducing size of diagnostic as well as guiding catheters are obviously excellent ways to minimize vessel aggression. In the authors's experience, the required support for difficult angioplasty can frequently be found through other ways than using very large catheters: more dedicated catheter shapes and additional tips like the buddy wire technic are adequate solutions. As previously said, for people relying on large lumen guiding catheters, sheathless material already offers an effective solution.

Sheaths without hydrophilic coating are to be avoided: these introducers induce more spasm and injure the vessel's wall: their poor performance is easily quantified with the traction operators have to apply when removing the tube. Such materials also induce more artery occlusions.

At the removal of catheter, the necessary compression for hemostasis is part of the injury to the radial artery: reducing intensity and duration of the compression can minimize this last aggression.

In order to simplify the "patent hemostasis" technique [22] - which has been proven effective in radial artery occlusion prevention- we started in 2009 a prospective study of low versus ultra low inflation volume for the TR-Band™ compression device used immediately after TRA. The results of 2107 randomized compressions are also being submitted for the coming ACC-i2 summit to be held in 2012.



On account of the way we are performing TRA actually, our rate of confirmed radial artery occlusion at 1 month is less than 1%.

## Conclusion

Ability to effortlessly perform radial artery cannulation should be a must for many clinicians as for interventional cardiology operators. In the field of interventional cardiology, reasons for deferring conversion from TFA are disappearing progressively with more and more evidence about safety and feasibility of TRA concurrent to the availability of improved materials. Teachers and dedicated optimal material are available: they provide solutions for all current problems encountered in a normal PCI practice. Today, it seems less important to be a rebel or a believer [7], but still mandatory to keep being a gentleman, at least with the radial artery.

## References

1. Carpentier A, Guermonprez JL, Deloche A, Frechette C, DuBost C (1973) The aorta-to-coronary radial artery bypass graft: a technique avoiding pathological changes in grafts. *Ann Thorac Surg* 16: 111-121.
2. Campeau L (1989) Percutaneous radial artery approach for coronary angiography. *Cathet Cardiovasc Diagn* 16: 3-7.
3. Kiemeneij F, Laarman GJ (1993) Percutaneous transradial artery approach for coronary stent implantation. *Cathet Cardiovasc Diagn* 30: 173-178.
4. Olivier F Bertrand, Sunil V Rao, Samir Panchoy, Sanjit S Jolly, Josep Rodés-Cabau, et al. (2010) Transradial approach for coronary angiography and interventions: results of the first international transradial practice survey. *JACC Cardiovasc Interv* 3: 1022-1031.
5. Rao SV, Ou FS, Wang TY, Roe MT, Brindis R, et al. (2008) Trends in the prevalence and outcomes of radial and femoral approaches to percutaneous coronary intervention: a report from the National Cardiovascular Data Registry. *JACC Intv* 1: 379-386.
6. Dauerman HL, Rao SV, Resnic FS, Applegate RJ (2011) Bleeding avoidance strategies. *J Am Coll Cardiol* 8: 1-10.
7. Dangoisse V (2010) Gentleman, rebel and believer: the radial way. *Indian Heart J* 62: 202-225.
8. Guédès A, Dangoisse V, Gabriel L, Jamart J, Chenu P, et al. (2010) Low rate of conversion to transfemoral approach when attempting both radial arteries for coronary angiography and percutaneous coronary intervention: a study of 1,826 consecutive procedures. *J Invasive Cardiol* 22: 391-397.
9. Fujii T, Masuda N, Toda E, Shima M, Tamiya S, et al. (2010) Analysis of right radial artery for transradial catheterization by quantitative angiography-anatomical consideration of optimal radial puncture point. *J Invasive Cardiol* 22: 372-376.
10. Dery JP, Simard S, Barbeau GR (2001) Reduction of discomfort at sheath removal during transradial coronary procedures with the use of hydrophilic-coated sheath. *Catheter Cardiovasc Interv* 54: 289-294.
11. Kim SM, Kim DK, Kim DS, Joo SJ, Lee JW, et al. (2006) Novel diagnostic catheter specifically designed for both coronary arteries via the right transradial approach. A prospective, randomized trial of Tiger II vs. Judkins catheters. *Int J Cardiovasc Imaging* 22: 295-303.
12. Ikari Y, Nakajima H, Iijima R, Aoki J, Tanabe K, et al. (2004) Initial Characterization of Ikari Guiding Catheter for Transradial Coronary Intervention. *J Invasive Cardiol* 16: 65-68.
13. Sciahbasi A, Mancone M, Cortese B, Pendenza G, Romagnoli E, et al. (2011) Transradial percutaneous coronary interventions using sheathless guiding catheters: a multicenter registry. *J Interv Cardiol* 24: 407-412.
14. Jolly SS, Amlani S, Hamon M, Yusuf S, Mehta SR (2009) Radial versus femoral access for coronary angiography or intervention and the impact on major bleeding and ischemic events: a systematic review and meta-analysis of randomized trials. *Am Heart J* 157: 132-140.
15. Jolly SS, Yusuf S, Cairns J, Niemelä K, Xavier D, et al. (2011) for the RIVAL Trial Group. Radial versus femoral access for coronary angiography and intervention in patients with acute coronary syndrome (RIVAL): a randomized, parallel group, multicentre trial. *Lancet* 377: 1409-1420.
16. Rathore S, Hakeem A, Pauriah M, Roberts E, Beaumont A, et al. (2009) A comparison of the transradial and the transfemoral approach in chronic total occlusion percutaneous coronary intervention. *Catheter Cardiovasc Interv* 73: 883-887.
17. Yang YJ, Kandzari DE, Gao Z, Xu B, Chen JL, et al. (2010) Transradial versus transfemoral method of percutaneous coronary revascularization for unprotected left main coronary artery disease: comparison of procedural and late-term outcomes. *JACC Cardiovascular Interv* 3: 1035-1042.
18. Sallam MM, Ali M, Al-Sekaiti R (2011) Management of radial artery perforation complicating coronary intervention: a stepwise approach. *J Interv Cardiol* 24: 401-406.
19. Tizon-Marcos H, Barbeau GR (2008) Incidence of compartment syndrome of the arm in a large series of transradial approach for coronary procedures. *J Interv Cardiol* 21: 380-384.
20. Yumiko Kanei, Tak Kwan, Navin C, Nakra, Michael Liou, Yili Huang, et al. (2011) Transradial cardiac catheterization: A Review of Access Site complications. *Catheter Cardiovasc Interv* 78: 840-846.
21. Stella PR, Kiemeneij F, Laarman GJ, Odekerken D, Slagboom T, et al. (1997) Incidence and outcome of radial artery occlusion following transradial artery coronary angioplasty. *Cathet Cardiovasc Diagn* 40: 156-158.
22. Panchoy S, Coppola J, Patel T, Roke-Thomas M (2008) Prevention of radial artery occlusion-patent hemostasis evaluation trial (PROPHET study): a randomized comparison of traditional versus patency documented hemostasis after transradial catheterization. *Catheter Cardiovasc Interv* 72: 335-340.

This article was originally published in a special issue, **Radial artery cannulation** handled by Editor(s). Dr. Singh A, State University of Missouri, USA.