Pediatrics & Therapeutics
ISSN: 2161-0665

Burkholder and Balaguru, Pediat Therapeut 2012, S5
DOI: 10.4172/2161-0665.S5-007

Review Article Open Access

Pulmonary Atresia with Intact Ventricular Septum: Management Options and Decision-making

Henry Burkholder* and Duraisamy Balaguru

Division of Pediatric Cardiology, University of Texas Houston Medical School, Houston, TX 77030, USA

Abstract

Pulmonary atresia with intact ventricular septum (PA-IVS) is a complex congenital heart malformation with a diverse set of anatomical and clinical findings. The incidence is 4.1 per 100,000 live births and is less than 1% of all congenital heart disease. During embryogenesis, PA-IVS is postulated to occur after development of ventricular septum which is later than the development of PA with ventricular septal defect. Every case of PA-IVS poses a considerable challenge to the pediatric cardiologist and cardiovascular surgeon. Although echocardiography is often the first line tool in cardiac imaging, cardiac catheterization is the gold standard for diagnosing PA-IVS and describing the important anatomical features that determine the plan of treatment. This article will focus on the management options and decision making from the interventional cardiologists point of view.

Keywords: Interventricular septum; Pulmonary atresia

Pathologic Anatomy

PA-IVS is defined by a membranous or muscular atresia of the right ventricular outflow tract and an intact ventricular septum. Varying degrees of right ventricle (RV) hypoplasia is an important characteristic of PA-IVS. RV cavity is considered to consist of 3 portions namely inlet, trabecular and infundibular portions. RV morphology can be categorized into three major types based on the presence of number of portions of RV cavity (Figure 1) [1-3]. (i) In the tripartite RV, consisting of inlet, trabecular and infundibular portions of the RV are nearly normal in size. (ii) In the bipartite RV, the inlet and infundibular portions are present and the trabecular portion is obliterated. Among the cases reviewed this study [3], if the trabecular portion was present, the infundibular portion was always present. There is moderately severe hypoplasia of the RV in this type. (iii) In the unipartite RV, only the inlet portion is present. The RV is severely hypoplastic with high pressure.

Dilated coronary sinusoids connecting to right or left coronary arteries usually have continuity with RV cavity from embryonic period. Coronary arteries that communicate with coronary sinusoids may be associated with either stenosis or atresia of their origins from the aortic root. This arrangement creates the so-called RV-dependent coronary circulation (RV-DCC), in which coronary circulation depends on the perfusion from the right ventricle and is driven by RV pressure. RV-DCC precludes decompression of the RV by opening the atretic pulmonary valve because this may lead to myocardial ischemia from reduction in RV pressure. The definition of RV-DCC is discussed below, under the evaluation and diagnosis section. Other associated features include tricuspid valve hypoplasia, tricuspid regurgitation with or without Ebstein's malformation, and rarely, aortopulmonary collateral vessels [4,5]. The morphological heterogeneity with its hemodynamic implications provides a great challenge in evaluation and clinical decision-making for the cardiologists, interventional cardiologists and surgeons.

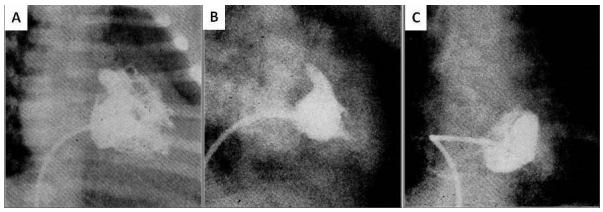

Panel A: Tripartite RV with presence of inlet, trabecular and infundibular portions.
Panel B–Bipartite RV with absent or severely Hypoplastic RV.
Panel C–Monopartite RV with only inlet portion. (Permission for reproduction granted by circulation)

Figure 1: Classification of RV in PA-IVS based on presence or absence of inlet, trabecular and infundibular portions. Angiography in RAO projection is used.

Evaluation and Diagnosis

At birth, cyanosis is the usual presenting symptom. The obstructed right ventricular outflow tract (RVOT) leads to obligatory right to left shunting at the atrial level causing marked cyanosis. Pulmonary blood flow is provided solely by the patent ductus arteriosus (PDA). A single S2 is heard on cardiac auscultation due to absent P2. Although a low intensity, continuous PDA murmur may be heard at the left upper sternal border or a tricuspid regurgitation murmur at the left lower sternal border, there is often no murmur detected on first exam. Electrocardiogram shows normal QRS axis, right atrial enlargement, left ventricular hypertrophy with monopartite type and possible right ventricular hypertrophy with tripartite type. Cyanotic newborns with tricuspid atresia will have a "superior" QRS axis-this may be clinically useful in distinguishing PA-IVS from tricuspid atresia. Abnormalities of the ST–T segments may be seen secondary to subendocardial ischemia. The chest X-ray may show a normal sized heart or possible cardiomegaly if there is significant right atrial enlargement. The main pulmonary artery segment will be concave with diminished pulmonary vascular markings.

Echocardiogram is the essential step in the diagnosis of this

***Corresponding author:** Henry Burkholder, Division of Pediatric Cardiology, University of Texas Houston Medical School, 6410 Fannin Street, UTPB–425, Houston, TX 77030, USA, Tel: 713-500 5738; Fax: 713-500 5751; E-mail: henry.burkholder@uth.tmc.edu

Received February 21, 2012; **Accepted** December 17, 2012; **Published** December 19, 2012

Citation: Burkholder H, Balaguru D (2012) Pulmonary Atresia with Intact Ventricular Septum: Management Options and Decision-making. Pediat Therapeut S5:007. doi:10.4172/2161-0665.S5-007

Copyright: © 2012 Burkholder H, et al. This is an open-access article distributed under the terms of the Creative Commons Attribution License, which permits unrestricted use, distribution, and reproduction in any medium, provided the original author and source are credited.

complex disease. The study should be complete, but focus on the following aspects to help develop the management plan:

1) Adequacy of PDA to sustain adequate pulmonary blood flow and adequacy of atrial septal defect to allow adequate decompression of the systemic venous return to the left atrium. These are essential to stabilize the baby's clinical status before any intervention.

2) Size of the right ventricle paying attention to the presence or absence of inlet, trabecular and/or infundibular portions of RV.

3) Evaluation of RVOT includes demonstration of an infundibular lumen, anatomic nature of pulmonary valve (muscular, membranous).

4) Demonstration of any evidence of an opening in the membranous pulmonary valve. This can be difficult due to interference from ductal flow towards the pulmonary valve. Presence of a jet of pulmonary regurgitation is taken as a reliable sign of presence of an opening in pulmonary valve.

5) Evaluation of tricuspid valve annulus diameter, nature of leaflets, specifically for any sign of Ebstein's anomaly and related chordal attachment abnormalities. Doppler interrogation of tricuspid regurgitation will help to assess RV systolic pressure. Furthermore, some researchers have proposed using the ratio of tricuspid valve annulus to mitral valve annulus diameters as a predictor of late outcome.

A subcostal approach with 2D imaging and Doppler investigation is preferred for this task. 2D measurements and Doppler interrogation of the tricuspid valve from multiple views must be obtained to determine the extent of stenosis and regurgitation. The TV diameter z-score by 2D imaging correlates well to the RV size and has long been a standard in helping to determine whether a patient is a candidate for single versus biventricular repair. A TV z-score worse than -3 correlates with the presence of coronary sinusoids. However, presence of RV-DCC has to be determined based on angiography as described below. This data supports the clinical observation by surgeons that the smallest right ventricles, which are the most likely to have RV dependent circulation, also tend to have the smallest tricuspid valves. A TV z-score of greater than -3 has been associated with successful biventricular repair [6]. The ratio of tricuspid to mitral valve diameters is also helpful with determining RV hypoplasia and therefore is also helpful in determining single versus biventricular repair. A tricuspid/mitral ratio >0.5 has been shown to be an excellent predictor of successful biventricular repair in PA-IVS patients [7]. It is important to remember that RV hypoplasia may involve all components of the right ventricle, emphasizing the need for thorough RV evaluation. Although the RVOT and pulmonary valve atresia are usually easily recognized in the parasternal and apical views, determining isolated valve atresia versus extremely severe stenosis may be difficult and is best demonstrated by cardiac catheterization. The echocardiographer should look for presence of coronary sinusoids in the myocardium using color Doppler mapping and any possible communications to RV cavity [6].

Cardiac catheterization is necessary for all patients with PA-IVS to complete the evaluation. Defining the coronary circulation and establishing whether RV-DCC exists is an important step in the management plan. RV angiogram provides definition of its three portions (Figure 2). Aortic root angiogram in conjunction with RV angiogram enables evaluation of coronary circulation. A selective angiogram in RVOT (Figure 3) helps to delineate anatomy of infundibulum and pulmonary valve. It is not uncommon to find a previously-unrecognized tiny opening in the pulmonary valve that was thought to be complete atresia. Pulmonary angiogram using a catheter across PDA will delineate main and branch pulmonary arteries. Aorto-pulmonary collateral arteries are rare in PA-IVS [8].

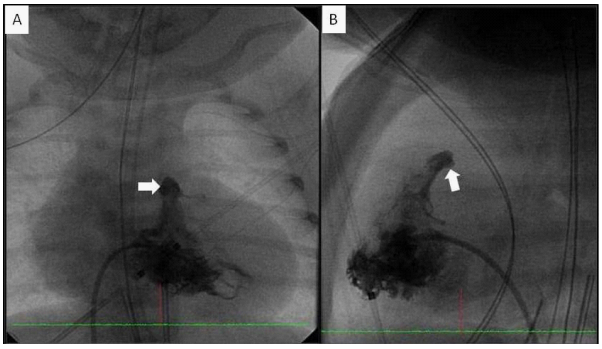

Figure 2: Right ventricular angiogram in PA and Lateral views. A) PA view has 20 degree cranial angulation. Contrast injection is made via Berman angiographic catheter. B) Tripartite RV with inlet, hypertrophied small trabecular and infundibular portions. Arrows indicate the RV outflow tract ending in membranous atresia of pulmonary valve.

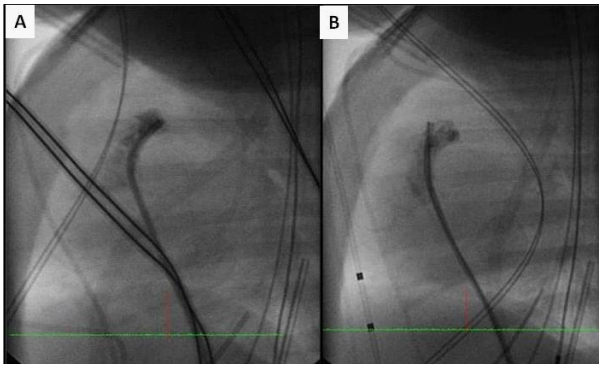

Panel A: shows an acceptable catheter-position with catheter-tip against the valve.
Panel B: shows an unacceptable catheter orientation, tip facing anterior wall of RV outflow tract. This catheter should be removed and replaced with a catheter with more curvature.

Figure 3: Lateral view angiogram of RV outflow tract, by hand injection, to check catheter position in RV outflow is crucial.

By angiography, RV dependent coronary artery circulation is defined by 1) ventriculo-coronary artery fistulae with severe obstruction of at least two major coronary arteries; 2) Complete atresia of the aortic coronary ostia or 3) A significant portion of the LV myocardium appears to be supplied by the RV and is judged to be at risk if RV decompression was performed [9]. Right ventricular dependence for myocardial flow has been predicted by an evaluation of the normalized size of the tricuspid valve with a Z-score of less than - 2.5. A Z-score of less than 2.5 also predicts poor clinical outcomes [4].

Decision making at this stage involves evaluation of echocardiographic and angiographic findings and determination of suitability for decompression of the RV by transcatheter technique. When found suitable, the catheterization procedure will continue into the interventional catheter therapy part.

Clinical decision making

Challenge for the interventional cardiologist in PA-IVS lies in choosing the best initial treatment plan for the patient. The patient is likely to require a combination of surgical and transcatheter treatments. Ultimately, the most important decision for the cardiologist is whether a biventricular, 1½ ventricular or univentricular palliative repair will be pursued. Biventricular repair is desirable, although repeat interventions or surgical procedure may still be required in the future [10]. Answering several questions will help make the clinical-decision. First, does the patient have RV dependent coronary artery circulation? Decompressing the ventricle via transcatheter or surgical technique in a case with RV-DCC can cause fatal myocardial ischemia. Patients with RV-DCC often have severe RV hypoplasia and small tricuspid valves [7]. A combination of echocardiographic, hemodynamic and angiographic data is used to make the determination. Tricuspid valve Z-score worse than (-3) is associated with risk of coronary sinusoids [6]. Other investigators have reported the high association of RV-DCC with TV z-score worse than (-4.5).

Secondly, is the RV adequate in size to support two-ventricle repair? Assessment of RV size in a newborn with PA-IVS is difficult in that the RV appears hypoplastic to a variable degree in all newborns with this condition. Therefore, several parameters have been proposed. (i) Presence of three portions of the RV i.e. tripartite, bipartite vs. unipartite. (ii) TV annulus diameter and its z-score as described above under the echocardiographic section and (iii) TV-MV ratio has also been useful as a predicting factor regarding possibility of two-ventricle repair [7]. TV/MV diameter ratio >0.5 along with TV z-score better than (-3) was associated with 2-ventricle repair.

Third, is there an infundibulum and is the main pulmonary trunk in continuity with the imperforate pulmonary valve? The ability to establish pulmonary blood flow via transcatheter RF valvotomy or RVOT transannular patch is important in stimulating growth of the hypoplastic RV. Stenting the PDA or surgically-placed modified BT shunt will allow for adequate pulmonary blood flow while RV is allowed to grow. Once the RV is properly developed, the shunts may be closed via transcatheter occlusion. This will result in a biventricular repair. If the RV does not adequately grow, the patient will be a candidate for a bidirectional Glenn operation. Bidirectional Glenn operation leaves the IVC flowing into the heart, via small tricuspid valve and moderately hypoplastic RV and pulmonary valve flowing into the pulmonary circulation and the SVC flowing directly into the RPA via bidirectional Glenn operation. This is referred to as the 1½ ventricle repair. If pulmonary blood flow cannot be established through the RVOT and pulmonary artery, a univentricular approach of bidirectional Glenn and Fontan operations will be required [11].

Finally, is the left ventricular function adequate? The left ventricular function must be analyzed closely, especially if a univentricular approach is required. Poor left ventricular function is a contraindication for the Glenn and Fontan operation in these patients. Primary cardiac transplantation should be strongly considered in these patients [9].

After the diagnosis is made via the methods described above, the cardiologist must decide on which transcatheter or surgical approach is appropriate for their patient. Ideally, a biventricular solution is best for these patients. Although there are many algorithms for treating PA-IVS, Alwi [12] describes an elegant, catheterization-based approach where the patients are divided into three groups. Depending on their group, an initial management and long term management strategy is prescribed.

Group A is considered to be the best anatomical group. They have TV Z-scores >-2.5, have membranous atresia and are usually the tripartite RV type. They have no major sinusoids and variable TR. The initial treatment is RF valvotomy and balloon dilation. The long term prognosis is usually good. Balloon dilation of restenosis, RVOT reconstruction or TV repair may occasionally be required.

Group B is an intermediate anatomical group. They have TV Z-scores -2.5 to -4.5 and have a bipartite RV type with a patent infundibulum. Major sinusoids may be present and minor sinusoids are common. There may be a small PV annulus and subvalvular stenosis with a variable degree of TV regurgitation. The initial treatment is RF valvotomy and balloon dilation, PDA stenting and possible balloon atrial septostomy. In patients where transcatheter intervention is not feasible, an RVOT transannular patch with modified BT shunt will be a surgical solution. If the RV grows well in these patients, the shunts may be closed via transcatheter occlusion. If the patient develops cyanosis from atrial level mixing, a transcatheter ASD device closure may be performed. If the RV fails to fully develop, a 1½ ventricle approach may be chosen. This entails a bidirectional Glenn with any RVOT reconstruction or TV repair required.

Group C are patients with severe RV hypoplasia. They have TV Z-scores less than -4.5 and have a unipartite RV type with hypoplastic, although usually competent TV. There are many major sinusoids with or without interruptions or stenoses. The initial treatment is an atrial balloon septostomy if needed with PDA stenting or modified BT shunt. Due to the RV-DCC, the RV cannot be decompressed. A bidirectional Glenn and eventually Fontan operation will be required. Cardiac transplantation may be considered in Group C patients. Patients with extreme Ebstein's anomaly or severely dysplastic tricuspid valve will require a conversion to tricuspid atresia with a modified BT shunt and eventually a Fontan. Primary cardiac transplantation should also be considered [12].

Management of Newborn with PA-IVS

Pre-catheterization management

A suspected diagnosis of PA-IVS should prompt initiation of intravenous infusion of prostaglandin E1 (PGE-1) to maintain adequate pulmonary blood flow via the PDA. Adequacy of atrial septal defect (ASD) to adequately decompress the right atrium should be ascertained at the time echocardiography. If ASD is inadequate, atrial septostomy may be indicated to stabilize the baby. However, such procedure may be combined with rest of the transcatheter intervention should it be necessary as described under decision-making section above. However, ASD or PFO shunt usually is adequate and the baby usually is stabilized. Metabolic derangements must be corrected prior to going to cardiac catheterization laboratory. The clinician should work to maintain a stable airway, correct metabolic as well as respiratory acidosis, treat any suspected infections and maintain a hematocrit above 40 to insure adequate tissue oxygenation. Imaging of the abdomen and brain are required to rule associated birth defects. A genetics consultation is often warranted if there is a family history of congenital anomalies and a chromosomal microarray panel may be obtained.

Transcatheter management and technique

Neonates with PA-IVS should remain on PGE1 infusion until clinically stable to undergo transcatheter or surgical therapy.

Vascular access: Femoral venous access is preferred over umbilical

venous access in order to make the catheter manipulations necessary to enter a hypoplastic RV with tricuspid regurgitation. Arterial access is also necessary which can be either via umbilical artery or femoral artery. Femoral arterial access provides slightly more flexibility and manipulating capacity should there be a need for more than the aortography was needed such as establishing veno-arterial loop of guidewire at a later stage in the procedure to facilitate advancing balloon catheter through the perforated atretic pulmonary valve. Heparin is administered to maintain ACTs greater than 200 sec, usually 50-100 units/kg.

Diagnostic part of the catheterization procedure: The objectives of the diagnostic part of the catheterization procedure include measurement RV systolic pressure–usually suprasystemic if the tricuspid valve is reasonably competent, RV angiography–to demonstrate RV cavity and RVOT and evaluation for RV-DCC. Care must be taken while crossing the tricuspid valve–especially with severe forms of RV hypoplasia when a possibility of RV-DCC exists. If the catheter were to stent-open the tricuspid valve, RV pressure may decrease the coronary perfusion pressure, leading to coronary insufficiency and ventricular fibrillation. If a Berman angiographic catheter were to be used for RV angiogram, care must be taken to ensure that all side-holes of the catheter are in the right ventricular side of the tricuspid valve (Figure 2). Alternatively, another catheter such as a Multi-purpose catheter with side-holes close to catheter tip is preferable. In such small RVs, a hand injection of small amount of contrast may suffice to get an adequate RV angiogram. It is preferable to perform all angiograms in Postero-anterior (PA) and lateral views. Some level of cranial angulation (20 degrees) in PA view will facilitate profiling the RVOT better for the planned intervention. Hand injection angiography of RVOT should be performed for adequate definition of infundibulum and pulmonary valve. This image will be useful as a road-map for guiding the perforation of the pulmonary valve should a decision is made to proceed with transcatheter therapy. An aortogram may be obtained to define the coronary artery origins from the aorta and their adequacy from aortic origin.

At this point, evaluation of these angiograms and hemodynamic data should be reviewed and decision regarding proceeding with possible perforation and balloon valvuloplasty of the pulmonary valve by transcatheter technique or not should be made. If the anatomy is considered suitable for transcatheter therapy, the procedure continues [4].

Transcatheter perforation of atretic pulmonary valve: Four French Judkin's Right coronary artery catheter with a 2 to 4 cm secondary curve (JR2 to JR4) is used to obtain a suitable angle of orientation along the long-axis of RVOT and perpendicular to the pulmonary valve annulus. Small hand injections of contrast should be used in AP and lateral projections to insure proper placement. The tip should be close to the valve and perpendicular to the valve plane that is suitable for perforation (Figure 4). The operator should be aware that the natural tendency of the catheter is to "face" the anterior free wall of the infundibulum (Figure 4B) rather than facing the pulmonary valve (Figure 4A). This should be recognized and corrected. Use of biplane fluoroscopy is useful in such instances. Otherwise, unintended perforation of RVOT will occur.

Perforation of the atretic pulmonary valve has been accomplished using a variety of equipments (stiff end of a regular guide wire, RF ablation catheters, CTO guide wires, Laser and Bayliss RF perforation wire). Bayliss RF perforation wire (Bayliss Medical Company. Toronto, Canada) is custom-made for this purpose. The RF perforating wire is different from RF ablation wire in the nature of energy applied and its effect on the tissue. The Bayliss RF perforating wire system consists of (i) RF perforation guide wire (0.024" thickness), (ii) co-axial microcatheter (available in 2 outer diameters 0.035" and 0.038", internal diameters of 0.024" and 0.027" respectively×145 cm long) and (iii) RF generator and cable. Whatever device is used for perforation, the interventionalist should have a plan for the next step i.e. advancing a catheter over across the perforated pulmonary valve – over the wire. This is one of the crucial steps. When RF perforating wire is not used, considerable distortion of the anatomy may occur in comparison to the roadmap obtained from angiograms. A 5 mm Gooseneck snare (Microvena Incorporated. White Bear Lake, MN) may be placed retrogradely via the arterial catheter advanced across PDA into MPA. This facilitates recognition of distortions in anatomy during the perforation should a stiff-end of the guide wire be used. However, the operator should be aware of the pitfalls of using only one method to ensure correct orientation. Figure 5 demonstrates how the snare catheter target may be misleading in some patients. In figure 5, the snare appears to be appropriate in PA view, whereas it is completely off-the-mark in lateral view underscoring the importance of biplane fluoroscopy in increasing the safety of this procedure.

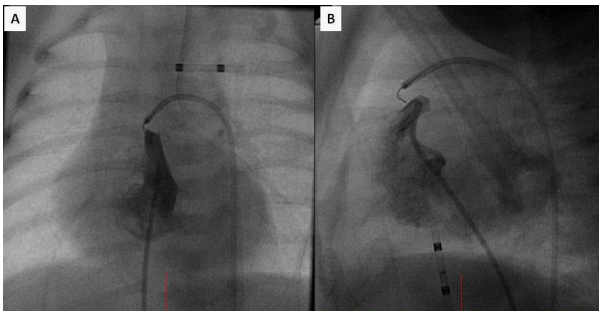

Figure 4: Word of caution regarding the use of goose-neck snare to mark the position of pulmonary valve. Figure shows simultaneous PA (Panel A) and Lateral (Panel B) views angiograms of RVOT. The goose neck snare catheter was positioned at the pulmonary valve via the arterial catheter passed through the PDA. While the position of the snare loop appears appropriate in PA view, it is off-the-mark in the lateral view. In this case, the snare loop is nestled between the bulging valve leaflets and the wall of the sinuses. This image underscores additional safety from biplane imaging and the need for confirmation of pulmonary valve location by more than one method prior to perforation.

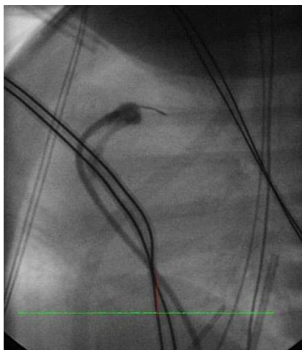

Figure 5: Lateral view angiogram of RV outflow tract, by hand injection. Angiogram shows the radio-frequency perforation wire that has crossed the atretic pulmonary valve. The wire should be advanced further either a branch pulmonary artery or into descending aorta via ductus arteriosus.

After ensuring proper orientation of the guide catheter (usually, 4 or 5 French JR 2.5 catheter, occasionally JR 3 or 4 catheters may provide the appropriate orientation), a radiofrequency catheter guide wire that is 0.024", 145 cm length and 1.5 mm long "active" metal tip is introduced (www.bvmmedical.com). The guidewire catheter is then connected to the RF generator and 5-10 W continuous-wave energy is applied for 3-5 seconds with fluoroscopic guidance. Firm forward "push" is maintained on the RF wire to keep tissue contact of the wire with valve tissue. Application of RF energy is stopped (usually in 3-5 seconds) when the RF wire tip moves across the valve-plane on lateral view fluoroscopy (Figure 5). Then, the RF wire position is secured by advancing via PDA into aorta or to a branch pulmonary artery. The co-axial microcatheter is then advanced over the RF wire. The atretic valve tissue may be thick in some patients and advancing a catheter over the RF wire may be difficult. However, one must use the microcatheter over the RF wire. Then, exchanging the RF guide wire to a stronger 0.014" or 0.018" coronary guide wires (e.g. V-18 Controlwire, Boston Scientific, Natick, MA) may help to support placement of the balloon catheter of choice for the next step.

Difficulty in advancing the balloon catheter of choice over the guide wire is a significant step. This can be accomplished in multiple methods such as a combination of guide wires of various thickness and strength, establishment of a veno-arterial loop by snaring the guide wire in the MPA or aorta via PDA via the arterial access. Tip of this guide wire is exteriorized via the femoral artery or the umbilical artery. Such an A-V loop will support advancing the balloon catheter of choice. This technique decreases the number of balloon valvuloplasties that need to be performed [13].

Serial balloon valvuloplasty of the pulmonary valve is performed starting from 3 mm coronary angioplasty balloons to 6-8 mm balloons (Figure 6). Several technical aspects of this procedure are demanding. First, one must maintain appropriate position of the right coronary artery guiding catheter while the stiff end of a guidewire is passed through the catheter. Second, one must apply the appropriate pressure on the guidewire in order to perforate the valve, yet not damage the RVOT or main pulmonary artery. Although this is a technically-demanding procedure, it is highly effective when the interventionalist is experienced [4,14].

Hybrid approach: One of the important steps in the procedure is placing a catheter in the RVOT in correct orientation to the RVOT and pulmonary valve (Figure 3). Traditionally, such patients will undergo surgical placement of RVOT patch that requires cardiopulmonary bypass with its attendant morbidity and mortality. For these patients, a hybrid approach has evolved in the recent years [15]. Hybrid approach consists of a sternotomy followed by placement of a purse string suture in RV free wall, at a suitable location aiming at the RVOT/Pulmonary valve. A needle is advanced via the purse-string suture, directed towards the pulmonary valve. Using TEE, the pulmonary valve is perforated. A guidewire is advanced and the needle removed. Guide wire position is confirmed by fluoroscopy. Over this guidewire, a 4 French sheath is placed and secured by the surgeon. Serial balloon dilatation of the pulmonary valve is performed just as in a percutaneous access. Imaging guidance will be a combination of TEE and fluoroscopy for this procedure. Experience with this technique is limited and requires the suitable institutional set-up such as collaboration with cardiovascular surgery and appropriate imaging equipment. Important advantage of hybrid procedure is that the need for cardiopulmonary bypass is eliminated by this method. This procedure is reviewed in detail elsewhere in this issue.

Post-procedure care: Care of the babies after a successful pulmonary valve perforation and balloon pulmonary valvuloplasty is crucial. Knowledge of the pathophysiologic changes occurring in the RV will help to determine the best course of management in this period. First, dynamic obstruction of the RVOT secondary to strong contraction of the hypertrophic RV infundibulum is noted immediately after successful balloon pulmonary valvuloplasty (Figure 7). This starts to resolve in a few days as the hypertrophy of RV starts to resolve. Continuation of prostaglandin infusion will help until strong contractility of the infundibulum occurs. Intervenous esmolol or oral propranolol may be used while prostaglandin is continued and supplemental oxygen used if systemic saturation cannot be maintained about 70% in room air. In the surgical valvotomy, dynamic infundibular stenosis in the immediately postoperative period is not an issue because surgical technique usually involves placement of a transannular patch. However, dynamic infundibular stenosis is a factor after hybrid approach to the management. Second, RV volume decreases compared to pre-intervention volume by a factor of approx. 40-50% before increasing back to pre-intervention volume by approximately 3 weeks (Figure 8) [10]. This provides a time-frame for the duration through which pulmonary circulation may need support from continued prostaglandin infusion.

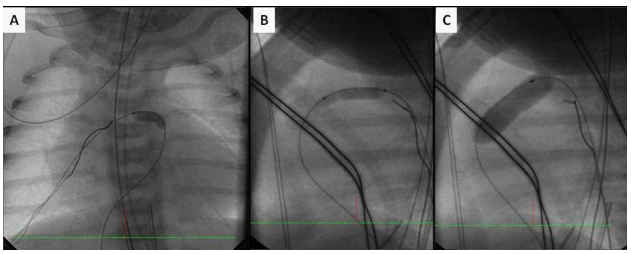

Figure 6: Panel A: PA angiogram of balloon pulmonary valvuloplasty using a small coronary artery balloon. The guide wire is stabilized in the right pulmonary artery. Note: Floppy portion of the guide wire is folded so that the stiffer portion will support the balloon.
Panel B: Lateral view angiogram of the small coronary artery balloon. A small waist is noted at the level of pulmonary valve.
Panel C: Lateral view angiogram. Last of the balloons (6 mm × 2 cm) Mini-Tyshak balloon was used to complete the series of balloon pulmonary valvuloplasty.

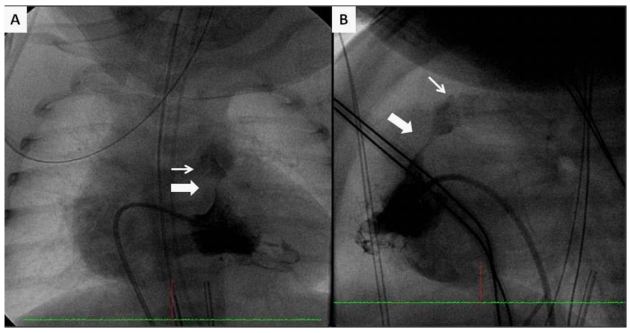

Figure 7: Freeze frames of PA and Lateral view of RV angiogram in systole, after successful balloon pulmonary valvuloplasty.
A) Thick arrow points to the severely-hypertrophied RV outflow tract that obliterates the infundibular lumen during systole causing dynamic obstruction.
B) Thin arrows point to the level of pulmonary valve leaflets which is at a higher level. This phenomenon leads to desaturation if prostaglandin infusion were discontinued immediately. Prostaglandin infusion should be continued for several days until this phenomenon starts to resolve.

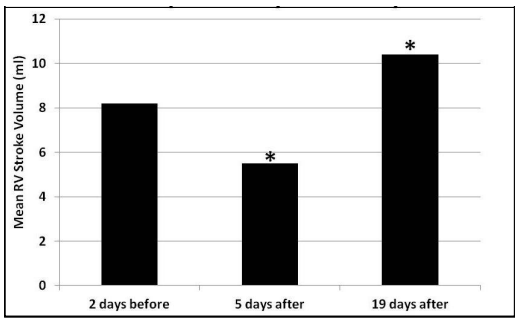

Figure 8: Changes in RV stroke volume in newborn who had pulmonary valvotomy.

Mean RV stroke volume changes immediately after successful balloon or surgical pulmonary valvotomy in newborn with either PA-IVS or critical pulmonary stenosis. At 5-days after intervention, RV stroke volume decreases by approx. 40-50%. At 19 days after the intervention, RV stroke volume increases to approximately 125% from pre-intervention value (* indicates significant change–p<0.05–from prior value). (Permission for reproduction granted by JACC).

If prostaglandin infusion cannot be discontinued in approximately 1-2 weeks, several experts advise BT shunt or stenting of patent ductus arteriosus if pulmonary valve annulus or the valve orifice is inadequate. However, in the authors' experience, the baby may be observed as long as 4-6 weeks for the oxygen saturation to improve back to satisfactory levels. In the mean time, baby may stay in the hospital or discharged home with oxygen via nasal cannula–if effective.

Low systemic saturation, even after 4-6 weeks, will warrant a re-evaluation of adequacy of pulmonary blood flow. The options for increasing pulmonary blood flow include re-catheterization to re-dilate the pulmonary valve if the valve anatomy appears to be technically amenable for further balloon dilatation, stent placement in the PDA if it is still patent or surgical Blalock-Taussig shunt.

If perforation of the pulmonary valve by catheter technique were unsuccessful, surgical alternative for transcatheter therapy consists of pulmonary valvotomy with or without BT shunt. The hybrid option has already been outlined above and elsewhere in this issue. In the presence of RV-dependent coronary circulation, RV decompression is contraindicated. Primary BT shunt or listing for heart transplant are options.

Outcomes

Prior to the successful use of transcatheter RF valvotomy with balloon valvuloplasty, the surgical treatment of choice was surgical valvotomy with BT shunt. Alwi et al. [16] investigated these two approaches in a set of 33 patients from 1990 to 1998. The study showed that RF valvotomy and balloon valvuloplasty is not only the safer initial approach, but also more effective compared to surgical valvotomy and BT shunt [16].

In one of the largest single center studies of PA-IVS, Marasini et al. [17] described outcomes of catheter based treatment. Forty seven cases of PA-IVS over 14 years were examined. Forty of the patients underwent attempted radiofrequency perforation and dilation of pulmonary valve as the first stage approach. Catheter-based pulmonary valvotomy was successful in all patients but one (97%), in whom the procedure was complicated by infundibular perforation that required surgical repair on an emergency basis by means of RVOT reconstruction and modified BT shunt procedure. Two other significant complications were observed including a post-procedural cardiac tamponade due to RVOT tear which was immediately sutured and one iliac artery dissection that required Safena patch angioplasty [17].

After hospital discharge, at a median follow-up of 82 months (range 14–159 months), 23 surviving patients achieved a biventricular circulation without any later intervention. In 19 of them (47.5%), neonatal radiofrequency perforation of the pulmonary artery was the only intervention performed. The other 15 surviving patients needed further surgical or catheter based intervention. One of these 15 patients died of postoperative complications after surgical RVOT reconstruction when he was 7 months old, four underwent bidirectional Glenn procedure and 10 achieved a two-ventricle circulation. The overall mortality reported in this study was 7.5%.

A retrospective review of 67 patients from 1981 to 1998 was conducted by Rychik et al. [18] to describe operative outcomes in PA-IVS. The patients were categorized on the basis of initial surgical strategy: "A" was aorto-pulmonary shunt alone (n=31), "B" was right ventricular recruitment, and "C" was heart transplantation. RV-dependent coronary circulation was noted in 8 patients. Overall survival at 1, 5, and 8 years was 82%, 76%, and 76% respectively. Mortality was highest during infancy (10 of 16 deaths). Most importantly, the outcome was equivalent in all three strategies. No difference in survival was noted between survivors and non-survivors concerning tricuspid valve size or severity of coronary artery abnormality. The tricuspid valve was considerably larger in patients who underwent biventricular repair versus Fontan (mean Z-score -.053 (1.6), range -3.5 to 2, versus mean Z-score -3.03 (2.7), range -5.5 to 0, p=0.002). The strategies of biventricular repair, single ventricle repair or primary transplant all provide good survival.

Conclusion

In conclusion, PA-IVS is a complex congenital heart malformation characterized by heterogeneous morphologies of RV cavity and outflow tract, coronary sinusoids and RV-DCC. Management of newborns with PA-IVS requires careful evaluation and decision making. An optimal combination of transcatheter, surgical and hybrid procedures will provide the best possible outcome for each individual patient. Transcatheter perforation of pulmonary valve followed by serial balloon dilatations in the newborn periods in appropriately selected patients provides good outcomes. Surgical and hybrid options may be suitable for patients who have RVOT unsuitable for transcatheter therapy. Post-procedure care after initial pulmonary valve perforation and balloon pulmonary valvuloplasty is important. Expectant management with symptomatic therapy, stenting of the patent ductus arteriosus or modified BT shunt are options if there is inadequate pulmonary blood flow. Achieving biventricular, 1.5 ventricular or univentricular repair is dependent on long-term growth of the RV.

References

1. Ferencz C, Rubin JD, McCarter RJ, Brenner JI, Neill CA, et al. (1985) Congenital heart disease: Prevalence at livebirth. The Baltimore-Washington Infant Study. Am J Epidemiol 121: 31-36.
2. Kutsche LM, Van Mierop LH (1983) Pulmonary atresia with and without ventricular septal defect: A different etiology and pathogenesis for the atresia in the 2 types? Am J Cardiol 51: 932-935.
3. Bull C, de Leval MR, Mercanti C, Macartney FJ, Anderson RH (1982) Pulmonary atresia and intact ventricular septum: A revised classification. Circulation 66: 266-272.
4. Cheatham JP (1998) The transcatheter management of the neonate and infant

with pulmonary atresia and intact ventricular septum. J Interv Cardiol 11: 363-387.

5. Daubeney PE, Delany DJ, Anderson RH, Sandor GG, Slavik Z, et al (2002) Pulmonary atresia with intact ventricular septum: Range of morphology in a population-based study. J Am Coll Cardiol 39: 1670-1679.
6. Satou GM, Perry SB, Gauvreau K, Geva T (2000) Echocardiographic predictors of coronary artery pathology in pulmonary atresia with intact ventricular septum. Am J Cardiol 85: 1319-1324.
7. Minich LL, Tani LY, Ritter S, Williams RV, Shaddy RE (2000) Usefulness of the preoperative tricuspid/mitral valve ratio for predicting outcome in pulmonary atresia with intact ventricular septum. Am J Cardiol 85: 1325-1328.
8. Walsh KP, Abdulhamed JM, Tometzki JP (1997) Importance of right ventricular outflow tract angiography in distinguishing critical pulmonary stenosis from pulmonary atresia. Heart 77: 456-460.
9. Verma A (2009) Congenital Heart Diseasel: The Catheterization Manual. Congenit Heart Dis 4: 301.
10. Schmidt KG, Cloez J, Silverman NH (1992) Changes of right ventricular size and function in neonates after valvotomy for pulmonary atresia or critical pulmonary stenosis and intact ventricular septum. J Am Coll Cardiol. 19: 1032-1037.
11. Alwi M, Choo KK, Radzi NA, Samion H, Pau KK, et al. (2011) Concomitant stenting of the patent ductus arteriosus and radiofrequency valvotomy in pulmonary atresia with intact ventricular septum and intermediate right ventricle: Early in-hospital and medium-term outcomes. J Thorac Cardiovasc Surg 141: 1355-1361.
12. Alwi M (2006) Management algorithm in pulmonary atresia with intact ventricular septum. Catheter Cardiovasc Interv 67: 679-686.
13. Weber HS, Cyran SE, Gleason MM, White MG, Baylen BG (1994) Critical pulmonary valve stenosis in the neonate: A technique to facilitate balloon dilation. Am J Cardiol 73: 310-312.
14. Siblini G, Rao PS, Singh GK, Tinker K, Balfour IC (1997) Transcatheter management of neonates with pulmonary atresia and intact ventricular septum. Cathet Cardiovasc Diagn 42: 395-402.
15. Nathan M, Verma R, Balaguru D, Starr J (2009) A brief review of hybrid procedures for congenital heart disease. HEART VIEWS (Journal of Gulf Heart Association) 10: 156-161.
16. Alwi M, Geetha K, Bilkis AA, Lim MK, Hasri S, et al. (2000) Pulmonary atresia with intact ventricular septum percutaneous radiofrequency-assisted valvotomy and balloon dilation versus surgical valvotomy and blalock taussig shunt. J Am Coll Cardiol 35: 468-476.
17. Marasini M, Gorrieri PF, Tuo G, Zannini L, Guido P, et al. (2009) Long-term results of catheter-based treatment of pulmonary atresia and intact ventricular septum. Heart 95: 1520-1524.
18. Rychik J, Levy H, Gaynor JW, DeCampli WM, Spray TL (1998) Outcome after operations for pulmonary atresia with intact ventricular septum. J Thorac Cardiovasc Surg 116: 924-931.

This article was originally published in a special issue, **Pediatric Interventional Cardiac Catheterization** handled by Editor(s). Dr. Duraisamy Balaguru, UT Houston School of Medicine, USA; Dr. P. Syamasundar Rao, UT Houston School of Medicine, USA