

Prostatic Ductal Adenocarcinoma: Case Report and Literature Review

Sheng-Lung Hsu^{1,5*}, Chien-Feng Li^{2,3}, Kun-Hung Shen⁴, Chiu-Lan Chen⁵ and Mei-Li Chen³

¹Division of Urology, Chiali Chi Mei Hospital, Tainan City, Taiwan

²Department of Pathology, Chiali Chi Mei Hospital, Tainan City, Taiwan

³Department of Medical Research, Chiali Chi Mei Hospital, Tainan City, Taiwan

⁴Division of Urology, Chi Mei Medical Center, Tainan City, Taiwan

⁵Department of Pharmacy, Chia Nan University, Tainan City, Taiwan

Abstract

Prostatic Duct Adenocarcinoma (PDA), not a unique disease but with nearly 5% of the prostate carcinoma, clinically deviated from common Prostatic Acinar Adenocarcinoma (PAA) in recent years and was deemed the exact existence even with its long-standing origin debates. Addedly, it was usually more aggressive than PAA in most studies. As for our daily urologic practice, the 2 PDA cases (with obstruction symptoms; with gross hematuria) progressed to imaging-indicated bone metastases and were probably historically in the large primary periurethral prostatic ducts or the peripheral prostatic ducts and extending exophytically into the urethra and most commonly in and around the verumontanum before retrospective chart reviews. Convincingly, though the early diagnosis and aggressive treatment failed, long term follow-up for disease outcomes stayed serious. Indeed, the rate of the gene fusion in the pure PDA was significantly lower genetically and biologically than that in the PAA and will be likewise examined.

Keywords: Prostate; Ductal adenocarcinoma

Abbreviations:

PDA: Prostatic Ductal Adenocarcinoma; PAA: Prostatic Acinar Adenocarcinoma; AJCC: American Joint Committee on Cancer; TRUS: Transrectal Ultrasound; PSA: Prostate Specific Antigen; RT: Radiotherapy; CK: Cytokeratin; HT: Hormone Therapy; TURP: Transurethral Resection of Prostate; CEA: Carcinoembryonic Antigen; TUR: Transurethral Resection; CT: Computed Tomography; PIN: Prostatic Intraepithelial Neoplasia

Background

PDA, not a unique disease but with approximately 5% of the prostate carcinoma prevalence, diverged clinically from common PAA in recent years and was considered the exact existence despite its longtime origin debates [1-3]. However, it usually progressed more aggressively than PAA in most studies [4]. Supplementarily, it drew increasing attention in recent years, attributed to its diverse clinical characteristics which were accordingly inspected herein.

Case Presentation

Case 1

In May 2013, an 80-year-old male with weak urine stream medicated for years after antecedently-achieved colon cancer surgery was admitted due to recent acute urinary retention. Consecutively, the findings were: the smooth surface, rubbery consistency and marked enlargement without hard palpable nodule of the prostate in the digital examination; the detrusor nor-moreflexia without detrusor sphincter dysynergia in the urodynamic study. Complementarily, the PSA was 33.23 ng/ml; The CEA (carcinoembryonic antigen), 3.8 ng/ml; the pathologists-assessed TRUS biopsy specimens, benign prostatic tissues. Thus, the TURP was attempted. Anyhow, a large round polyp-like tumor beyond the verumontanum was averred (Figure 1a and 1b) along with multiple papillary growths of the prostatic urethra near the apex (Figure 1c and 1d). Consequently, the schemes were:

(1) The Transurethral Resection (TUR) of urethral tumors and

transurethral incision of the prostate were plied instead.

(2) In the final pathological specimens, the PDA (Gleason grade 4+4=8) was attested with the 90% of tumor volume.

(3) In the microscopic sections, adenocarcinomas in papillary and cribriform growth patterns were composed of tall columnar cells displaying nuclear pseudostratification, and prominent nucleoli (Figure 2).

(4) Regarding the immunohistochemical stains, they were positive for PSA (Figure 3) and p504s (Figures 3 and 4) but not for cytokeratin (CK) 7 and CK20, supporting the diagnosis before the imaging-staged bone metastases.

(5) The Computed Tomography (CT) proved nodular sclerotic bone metastases to the left pubis and right iliac wing. The clinical TNM staging was T₃N₁M_{1b} by imaging.

Resultantly, the Hormone Therapy (HT) with leuprorelin acetate and antiandrogen (Cyproterone) were delivered with palliative radiotherapy (RT) for bone pain. Up to Feb 2015, The PSA dropped to 0.56 ng/ml.

Case 2

In March 2014, an 89-year-old male at our clinic was chiefly complained of: about 1-year discontinuous painless gross hematuria; bony pain; being nearly bedridden recently. The PSA was 366.68 ng/ml.

***Corresponding author:** Sheng-Lung Hsu, Division of Urology, Chiali Chi Mei Hospital, No.606, Jialixing., Jiali District, Tainan City 722, Taiwan, Tel: 886067263333; E-mail: 900249@mail.chimei.org.tw

Received July 17, 2015; **Accepted** August 03, 2015; **Published** August 24, 2015

Citation: Hsu SL, Li CF, Shen KH, Chen CL, Chen ML (2015) Prostatic Ductal Adenocarcinoma: Case Report and Literature Review. *Andrology* 4:139. doi:10.4172/2167-0250.1000139

Copyright: © 2015 Hsu SL, et al. This is an open-access article distributed under the terms of the Creative Commons Attribution License, which permits unrestricted use, distribution, and reproduction in any medium, provided the original author and source are credited.

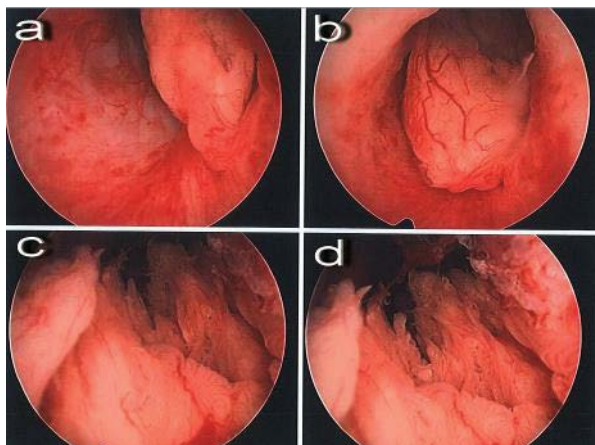


Figure 1: A large round polyp-like tumor ("a" and "b") beyond the verumontanum was averred along with multiple papillary growths ("c" and "d") of the prostatic urethra near the apex cystoscopically.

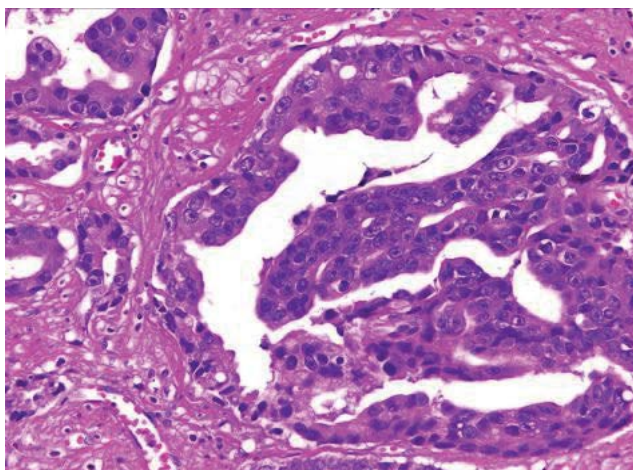


Figure 2: The prostate glandular cells showed cribriform arrangements composed of tall columnar cells displaying nuclear pseudostratification, and prominent nucleoli (hematoxylin and eosin x400).

ml. Four sets of urine cytology all reported as negative for malignancy. The strategies were:

(1) The cystoscopy certified several papillary tumors over almost the apex of the prostatic urethra and the lateral kissing lobes of the enlarged prostate (Figure 5); the cystoscopic tumor biopsies, the PDA.

(2) Immunohistochemically, the tumor cells were positive for PSA and p504s, but not CK7, confirming the diagnosis of a ductal adenocarcinoma (Gleason's score 4+4=8) of prostatic origin.

(3) The CT proved the prostate cancer with invaded capsular and bilateral seminal vesicles; the bone scan, multiple bone metastases. The clinical TNM staging was $T_{3b}N_xM_{1b}$ by imaging.

Up to Feb 2015, the multiple bony pains always bothered him because of the RT refusal. Although HT was with leuprorelin acetate and antiandrogen (Cyproterone), the PSA was still 96.02 ng/ml predicative of the hormone-refractory prostate cancer. Nonetheless,

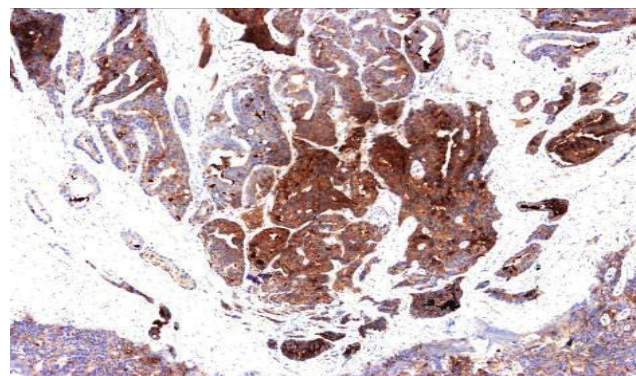


Figure 3: The PSA stain was positive (x100).

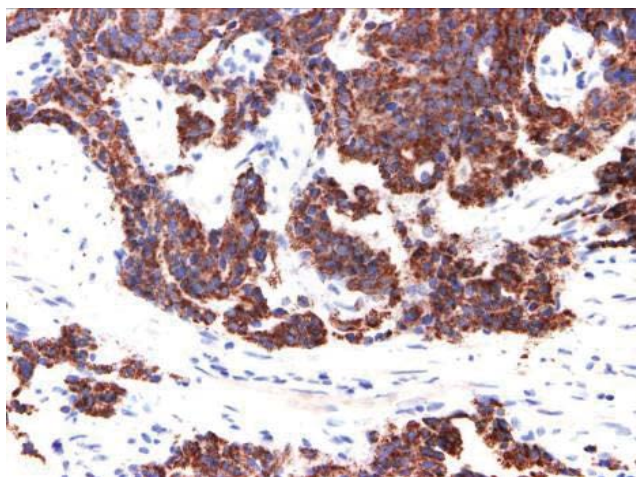


Figure 4: The p504s stain was positive (x400).

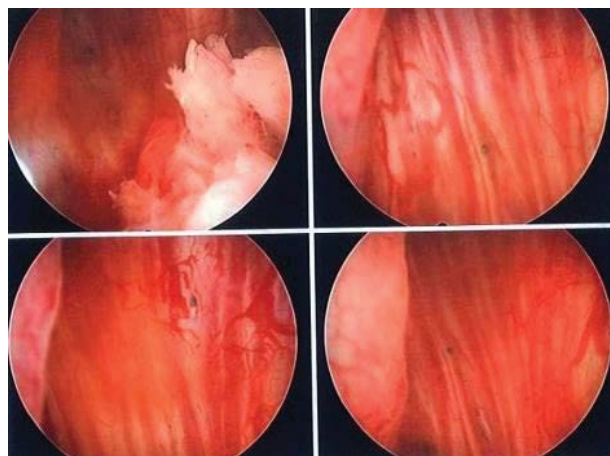


Figure 5: The cystoscopy certified several papillary tumors over almost the apex of the prostatic urethra and the lateral kissing lobes of the enlarged prostate.

the abiraterone, an androgen synthesis inhibitor was contraindicated in him in view of severe cardiovascular disease (the abdominal aortic aneurysm; hypertension).

Discussion

Historically PDA, distinct acinar, was accentuated by:

- (1) Growing into the proximal prostatic duct tissue [5]
- (2) Deriving from the müllerian remnant tissue.
- (3) Being probably in the large primary periurethral prostatic ducts or the peripheral prostatic ducts
- (4) Extending exophytically into the urethra and most commonly in and around the verumontanum [6]

Respecting our first PDA case, it often had no prostate biopsies-detected tumor cell and dramatically differed from the PAA pertinent to its typical periurethral location which often resulted in hematuria or obstruction [7]. Thence, the approaches were:

- (1) Pathologically distinguishing large prostatic lesions with ductal morphology was mandatory, over and above attentively ruling out a lot of mimicking diseases.
- (2) Microscopically, the 2 most common ones were papillary and cribriform. The former mimicked papillary urothelial carcinomas closely.
- (3) With PSA and p504s, the papillary urethral tumors from the urothelium or colonic epithelium were excluded [8-10]; so were the prostatic intraepithelial neoplasia (PIN) by the normal duct structure microscopically and the colonic lesion by positive CK 20 in our case 1 [11].
- (4) Immunohistochemically for PSA, PAP, CK 7, CK 20, alpha-methylacyl-CoA racemase, p63, and CK 34BE12, atypical prostatic lesions could be effectively differentially diagnosed.

Accompanying, it was distinctive about the PDA that:

- (1) It was more aggressive than PAA in most studies [4,12] and often diagnosed as an advanced disease with early metastases.
- (2) Pure PDA increased local recurrence risk but was prone clinically weird; therefore, if the surgery patients were of pure ductal prostate cancer, they survived longer than those of mixed ductal prostate cancer and had the longer time metastasis than the latter and might improve clinically with local control.
- (3) The first case received only en bloc resection of the urethral tumor whose volume occupied 90% of the specimen. Moreover, the PDA cases diagnosed from transurethral biopsy or TURP might be eradicated by the above surgery only and by no further operation [13].
- (4) Its progress was not always hazardous.
- (5) Regrettably, our long term survivals could not be properly predicted owing to no complete specimen of radical prostatectomy which most Taiwan urologists did not recommend. The life expectancy (exceeding 65 years) in our patients was expectedly 10 years less than that the averagely in Taiwan [14].

In spite of the vicious cycle of PDA, the current consensus in treatment (RT; HT) also worked well as for PAA [15]. Unfortunately, our two patients were with high risk prostate cancer according to the

National Comprehensive Cancer Network classification. Inevitably, long term follow-up is needed notwithstanding the serious outcome.

Overall, the patients with PDA had worse prostate cancer-specific survival and prognosis than those with PAA [16]. The PDA metastasis (25%-40%) was evident during diagnosis which affirmed a 2.2-fold increase in cancer-specific mortality [17]. Concomitantly, the gene fusion might progress the PAA or develop the PDA [18]; the rate in pure PDA cases was significantly lower genetically and biologically than that in PAA cases and incidentally was important for future therapy [19] and appealing in recent years [20,21].

Conclusion

PDA was peculiar in prostate adenocarcinoma. Hence, arresting in our limited cases of high histological grades and advanced stages, long-term follow-up for disease outcomes remained requisite regardless of the failure of early diagnosis and aggressive treatment. Unavoidably, the rate of the gene fusion in the pure PDA was significantly lower genetically and biologically than that in the PAA and will be furthermore investigated.

Consent

The Chi Mei Medical Center Institutional Review Board-approved waiver of documentation of consent is for this journal; so is a copy of the clinical trials-required certificate.\

References

1. Morgan TM, Welty CJ, Vakar-Lopez F, Lin DW, Wright JL (2010) Ductal adenocarcinoma of the prostate: increased mortality risk and decreased serum prostate specific antigen. *J Urol* 184: 2303-2307.
2. Bock BJ, Bostwick DG (1999) Does prostatic ductal adenocarcinoma exist? *Am J Surg Pathol* 23: 781-785.
3. Ro JY, Ayala AG, Wishnow KI, Ordonez NG (1988) Prostatic duct adenocarcinoma with endometrioid features: immunohistochemical and electron microscopic study. *Semin Diagn Pathol* 5: 301-311.
4. Seipel AH, Wiklund F, Wiklund NP, Egevad L (2013) Histopathological features of ductal adenocarcinoma of the prostate in 1,051 radical prostatectomy specimens. *Virchows Arch* 462: 429-436.
5. Shazer RL, Luthringer D, Agus DB, Gross ME (2004) Ductal adenocarcinoma of the prostate. *Clin Adv Hematol Oncol* 2: 393-395.
6. Epstein JI (2010) Prostatic ductal adenocarcinoma: a mini review. *Med Princ Pract* 19: 82-85.
7. Oyasu R, Yang XJ, Yoshida O (2008) Questions in Daily Urologic Practice. New York: Springer 49-54.
8. Hameed O, Humphrey PA (2005) Immunohistochemistry in diagnostic surgical pathology of the prostate. *Semin Diagn Pathol* 22: 88-104.
9. Humphrey PA (2012) Histological variants of prostatic carcinoma and their significance. *Histopathology* 60: 59-74.
10. Beach R, Gown AM, De Peralta-Venturina MN, Folpe AL, Yaziji H, et al. (2002) P504S immunohistochemical detection in 405 prostatic specimens including 376 18-gauge needle biopsies. *Am J Surg Pathol* 26: 1588-1596.
11. Bonkhoff H, Wheeler TM, van der Kwast TH, Magi-Galluzzi C, Montironi R, et al. (2013) Intraductal carcinoma of the prostate: precursor or aggressive phenotype of prostate cancer? *Prostate* 73: 442-448.
12. Tu SM, Lopez A, Leibovici D, Bilen MA, Evliyaoglu F, et al. (2009) Ductal adenocarcinoma of the prostate: clinical features and implications after local therapy. *Cancer* 115: 2872-2880.
13. Aydin H, Zhang J, Samaratinga H, Tan N, Magi-Galluzzi C, et al. (2010) Ductal adenocarcinoma of the prostate diagnosed on transurethral biopsy or resection is not always indicative of aggressive disease: implications for clinical

- management. *BJU Int* 105: 476-480.
14. Lee WC, Hsieh RL (1996) Estimating life expectancy using an age-cohort model in Taiwan. *J Epidemiol Community Health* 50: 214-217.
 15. Orihuela E, Green JM (2008) Ductal prostate cancer: contemporary management and outcomes. *Urol Oncol* 26: 368-371.
 16. Meeks JJ, Zhao LC, Cashy J, Kundu S (2012) Incidence and outcomes of ductal carcinoma of the prostate in the USA: analysis of data from the Surveillance, Epidemiology, and End Results program. *BJU Int* 109: 831-834.
 17. Hertel JD, Humphrey PA (2011) Ductal adenocarcinoma of the prostate. *J Urol* 186: 277-278.
 18. Carter BS, Epstein JI, Isaacs WB (1990) ras gene mutations in human prostate cancer. *Cancer Res* 50: 6830-6832.
 19. Lotan TL, Toubaji A, Albadine R, Latour M, Herawi M, et al. (2009) TMPRSS2-ERG gene fusions are infrequent in prostatic ductal adenocarcinomas. *Mod Pathol* 22: 359-365.
 20. Cheng WS, Kraaij R, Nilsson B, van der Weel L, de Ridder CM, et al. (2004) A novel TARP-promoter-based adenovirus against hormone-dependent and hormone-refractory prostate cancer. *Mol Ther* 10: 355-364.
 21. Freytag SO, Stricker H, Movsas B, Kim JH (2007) Prostate cancer gene therapy clinical trials. *Mol Ther* 15: 1042-1052.