

Proposal to Develop A Clinical Index for Classification of Skull Fractures (CISFRAC): Proposal for Personalized Management Score

Luis Rafael Moscote-Salazar^{1*}, Andres M. Rubiano¹ and Amit Agrawal²

¹Neurosurgeon-Critical Care, RED LATINO Organización latinoamericana de Trauma y Cuidado neurointensivo, Chile

²Narayana Medical College Hospital, Andhra Pradesh, India

*Corresponding author: Luis Rafael Moscote-Salazar, Neurosurgeon-Critical Care, RED LATINO Organización latinoamericana de Trauma y Cuidado neurointensivo, Chile, Tel: +57301283538; E-mail: mineurocirujano@aol.com

Received date: July 10, 2016; Accepted date: July 11, 2016; Published date: July 18, 2016

Copyright: © 2016 Moscote-Salazar LR, et al. This is an open-access article distributed under the terms of the Creative Commons Attribution License, which permits unrestricted use, distribution and reproduction in any medium, provided the original author and source are credited.

Abstract

Traumatic brain injury is a public health problem. There are several clinical classification systems for traumatic brain lesion. Skull fractures are a type of primary lesion of the cranial vault, whose classification system is simple but is not homogeneous. We propose an innovative index of severity of head injuries. This index will be especially important for neurosurgeons and researchers to plan management and compare the results.

Keywords Classification; Brain; Traumatic; Injury; Severity

Introduction

Traumatic brain injury (TBI) is defined as an alteration in brain function or other evidence of brain pathology, caused by external forces [1]. The incidence of TBI continues to increase and, according to predictions, this kind of trauma will continue to represent an increase in the number of deaths worldwide by 2020.

The severity of head trauma is determined according to the scores of the Glasgow Coma Scale (ECG), the mild TBI that with a score of 13-15, 9-12 moderate and severe = < 8. In children, 5-8% of TCE are severe, moderate 7-8% and 80-90% leves 5.

Skull fractures

Cranocerebral injury during primary and secondary injuries occur at the level of the skull fractures occur. Skull fractures can be categorized as a) linear skull fractures, b) depressed skull fractures, c) comminuted skull fractures, d) diastatic skull fractures, e) expressed skull fractures, f) stellate skull fractures, g) multiple fractures, elevated skull fractures and h) combinations of the above [2].

Another classification classifies these as depressed and comminuted. The compound fractures rips on the fracture line. Skull fractures are a potential indicator of serious brain injury and brain CT required. Linear fractures do not require surgery and these resolved spontaneously. This classification may be inconsistent. Management strategies for handling skull fractures are aimed at reducing the risk of infection, treat bone deformities, reduce the risk of epilepsy and when neurological deficit. The presence of skull fractures is related to the presence of other intracranial lesions.

Depressed and open fractures are the type of fracture that will require, in most cases, surgical management. Moreover, linear and closed fractures can be managed conservatively, depressed fractures account for 6% of head injuries. The skull is the bony part of the head, and consists of 22 bones that are in connection with sutures, except in the mandible (lower jaw).

A linear fracture is a fracture of the skull that looks like a line. It is the most common type of skull fracture. A depressed fracture is defined as an inward displacement of part of the skull. In crushed skull fractures, bone fragmentation is observed. This type of fracture occurs when a heavy object with a low speed affects the skull. This creates several fracture lines extending from the impact point and circular fractures at distances from the point of impact.

Diastatic skull fractures skull separations occur. Usually this type of fracture is usually observed in the suture lines, as they can act as a stress concentration area. Combinations of the different types of fractures are often seen [3-5]. Particularly common are combinations of depressed fractures and comminuted fractures or depressed and starry.

After careful analysis of the literature, management guidelines Bullock and colleagues recommend [6]:

1. Lift and surgical debridement of open and depressed than the thickness of the skull or greater than 1 cm or with evidence of dural disruption, associated with bruises, commitment breast, wound contamination or infection or major cosmetic deformity fractures.
2. Patients with open fractures can be treated non-surgically if there are some of the criteria mentioned above.
3. Single or linear depressed fractures can be managed conservatively.

The time of surgical debridement and correction is important, and must be between 24 and 27 hours after the incident. Antibiotics are recommended for the treatment of all open skull fractures. We propose a new index skull fracture (Figure 1 and Table 1).

Our index of fracture can standardize the management and further analysis. Our score is based on the imaging characteristics and extent in different regions of the skull. Score using specific criteria, clinicians may assign a clinical index for skull fracture (CISFRAC) varying from 0 to 32.

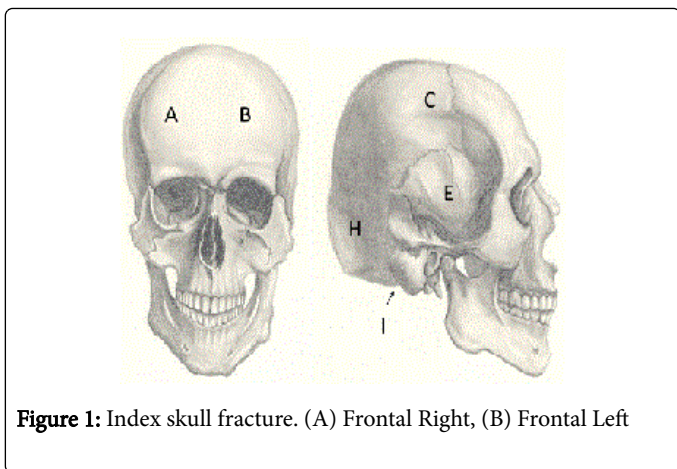


Figure 1: Index skull fracture. (A) Frontal Right, (B) Frontal Left

H		
I		

Table 1: Clinical index for skull fracture: by ascribing to each skull area of fracture related score as indicated, the sum of scores will result in the CISFRAC.

Allowing a precise description of cranial fractures level. This standardized classification helps the quantification of injuries, allowing researchers to integrate the results of various studies to establish a working language in the neuro surgical activity. Neurosurgery in the coming years will depend on basic research, so our index is a contribution to the clinical practice and basic research.

References

1. Gurdjian ES (1975) Impact Head Injury: Mechanistic, Clinical and Preventive Correlations. Charles C Thomas Publisher
2. Gurdjian ES, Webster JE, Lissner HR (1950) The Mechanism of Skull Fracture. Radiology 54: 313-339.
3. Gurdjian ES, Webster JE, Lissner HR (1953) Observations on Prediction of Fracture Site in Head Injury. Radiology 60: 226-235.
4. Seeley RR, Stephens TD, Tate P (2003) Anatomy & Physiology. (6thedtn), McGraw-Hill.
5. Cummins BH, Potter JM (1970) Head injury due to falls from heights. Injury 2: 61-64.
6. Bullock MR, Chesnut R, Ghajar J, Gordon D, Hartl R, et al (2006) Surgical management of depressed cranial fractures. Neurosurgery 58: S56-60.

Region	Grade	Fracture
A	0	No fracture
B	1	Linear Fracture
C	2	Depressed fracture
D	3	Fracture elevated / Sinus
E	4	Avulsion
F		
G		