

## Pre-pubertal Female on Growth Hormone Therapy Diagnosed with Legg Calve Perthes Disease

Arouj Bajwa, Terra Blatnik, Ryan Goodwin, Joseph Lock, Bahareh M. Schweiger\* and Michelle Schweiger DOB

Center for Pediatric Endocrinology, Desk A-120, Cleveland Clinic, 9500 Euclid Avenue, Cleveland, OH 44195, USA

\*Corresponding author: Bahareh M. Schweiger, Center for Pediatric Endocrinology, Desk A-120, Cleveland Clinic, 9500 Euclid Avenue, Cleveland, OH 44195, USA, Tel: 216/445-5158; Fax: 216-636-6761; E-mail: [SCHWEIM@ccf.org](mailto:SCHWEIM@ccf.org)

Rec Date: Mar 06, 2015, Acc Date: Mar 20, 2015, Pub Date: Mar 25, 2015

Copyright: © 2015 Bajwa A, et al. This is an open-access article distributed under the terms of the Creative Commons Attribution License, which permits unrestricted use, distribution, and reproduction in any medium, provided the original author and source are credited.

### Abstract

Legg-Calve-Perthes disease (LCPD) is a childhood disorder of the femoral head most commonly seen amongst boys of 4-8 years of age. It occurs due to inadequate blood supply to the femoral head. We report the case of 7 year 8 month old girl who presented with short stature and was started on growth hormone replacement therapy for growth hormone deficiency. After 2 years and 8 months on growth hormone she developed Legg Calve Perthes. She continued to follow up in endocrinology clinic and was continued on half of her required dose of growth hormone without any further complications. To our knowledge this is the first reported case of LCPD in pre-pubertal girl on Growth hormone (GH).

**Keywords:** Osteonecrosis; LCPD; Trauma; Growth hormone therapy

### Introduction

Legg-Calve-Perthes disease (LCPD) is an idiopathic osteonecrosis of the femoral head epiphysis seen amongst children of 4-8 years of age. Reported incidence is 0.2 to 19.1 per 100,000 with boys diagnosed five times as often as girls with LCPD. Bilateral cases, however, are reported more commonly amongst girls [1]. Children affected by LCPD usually present with complains of limping and mild groin or hip pain. The etiology of LCPD remains unclear, which makes it difficult to identify at risk individuals or to create prevention strategies [2]. One of the most predisposing factors is race, East Asians are affected the least and Caucasian Whites are affected the most. Genetics is also a well-documented factor. Some studies suggest repetitive trauma, blood supply abnormalities and coagulation disorders as causative factors [3]. Furthermore, LCPD associated with delayed bone age and low birth is confounded by factors, such as socioeconomic status, smoking, and steroid use in premature infants [4]. An increased incidence of LCPD has been reported in case of GH deficiency [5,6]. To our knowledge there have only been a handful of reported cases of LCPD in children on treated for growth hormone deficiency using growth hormones. It is noteworthy that these were complicated by renal osteodystrophy and hyperthyroidism [5,6] and occurred most commonly in males [7]. The mechanism by which endocrine abnormalities and the GH therapy cause femoral head avascular necrosis in children remains unknown. In most cases, the affected children recover from Perthes' disease.

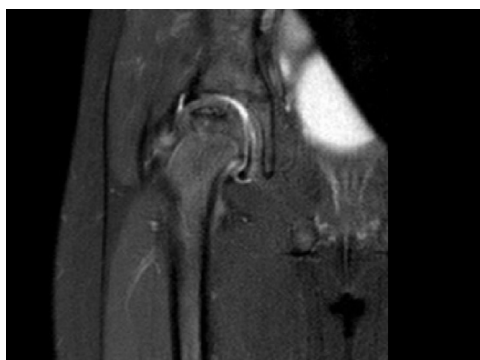In this report, we discuss a 7 year 8 month old girl with growth hormone deficiency being treated with growth hormone since the age of 5. After 2 years 8 months of therapy she complained of right thigh pain and was diagnosed with Legg Calve Perthes' disease. LCPD is a disorder which has been reported in patients with growth hormone deficiency. Our patient continued to receive the growth hormone after undergoing right adductor tenotomy and bilateral petri casts.

### Case Report

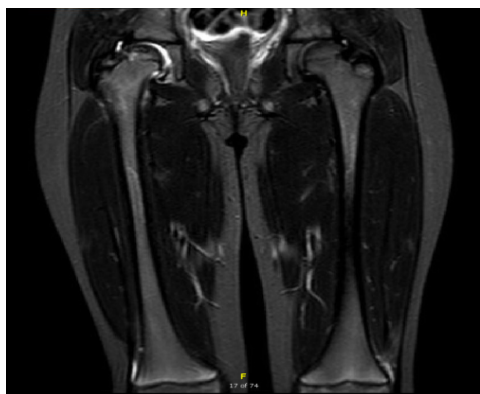
A 4 year old female was presented to the endocrinology clinic for evaluation of short stature. She was born full term with birth weight of 6 lbs. Other than speech delay she had no developmental problems. She had a good appetite and no chronic illnesses. Her mother's height was 4'10" and father's was 5'5" with the calculated mid parental height of 149.7 cm or 4'11". Review of her growth chart revealed linear growth velocity less than 1% since newborn period. On physical examination she was small for her age with no dysmorphic features. Her body weight was 12.8 kg, height was 86.1 cm and BMI was 17.27 kg/m<sup>2</sup>.

She had significantly short stature with height <1%. Her breast and genitalia was consistent with pre pubertal development. Her CBC, renal, liver and thyroid function tests were within normal limits. She had negative celiac titers. Her IGF1 was low normal with a value of 57 (49-327 ng/mL). Her karyotype was 46 XX and bone age reported to be 3 years at a chronological age of 4 years. She had sub-optimal growth velocity of 4.3 cm/year and therefore underwent GH stimulation test using clonidine and glucagon which showed a peak GH level of 6.58 ng/mL. MRI pituitary revealed a mildly diminutive pituitary gland and infundibulum with no mass or abnormal enhancement. Based on the MRI findings and GH stimulation test results she was started on Somatropin 0.27 mg/kg/week (0.7 mg SQ six days per week) in September 2011. On her follow up in January 2012 her growth velocity reached 11.3 cm/year. After complaining of bilateral lower extremity pain in early 2012 her growth hormone dose was held and then restarted after being evaluated by her PCP. Her bilateral X-ray hip being negative for any pathology and her leg pain resolved. In May 2012 she had a linear growth velocity of 6.7 cm/year and her Somatropin was increased to 0.9 SQ six days per week (0.29 mg/kg/week). In January 2013 her dose was further increased to 1 mg SQ six days per week (0.3 mg/kg/week) and she had a linear growth velocity of 7.7 cm/year. In January 2014 to adjust her weight gain the patient's growth hormone dose was increased to 1.1 mg sq six days per week (0.31 mg/kg/week).

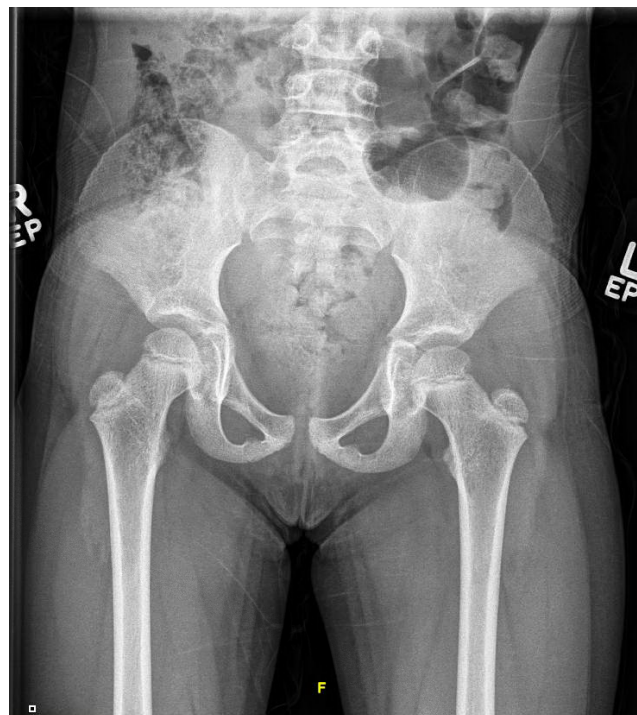In February 2014 at the age of 7 years the patient was seen in the Orthopedics clinic with complaints of right leg pain, limping and painful walking after skiing. At the time of presentation she was on Somatropin dose of 1.1 SQ six days per week. On examination she had a full ROM at the hip joint with decreased strength with knee extension on the right, pain with resisted hip flexion and good internal and external rotation. Bilateral X-ray hip AP view was conducted which was negative for any fracture or dislocations. Patient continued complaining of limited activities secondary to right thigh pain and altered gait. Therefore, an MRI lower extremity was conducted keeping in mind the orthopedic complications of growth hormone therapy (specifically SCFE). MRI revealed avascular necrosis of the right proximal femur epiphysis with subtle collapse of right femoral head. Small right joint effusion was visible. Left hip appeared normal. She was diagnosed with Perthes disease and was treated with naproxin 250 mg twice daily along with stretch exercises. Her condition worsened and she underwent right adductor tenotomy with bilateral Petri casts to contain the femoral head in September 2014. Based on Pediatric Endocrinologist's and the Orthopedic surgeon's clinical judgment since the time of her diagnosis she was continued on growth hormone therapy on a dose of 0.6 mg sq six days per week (0.15 mg/kg/week) which was half of the required dose. This dose was stopped only for 10 days after her surgery (Figures 1-4).



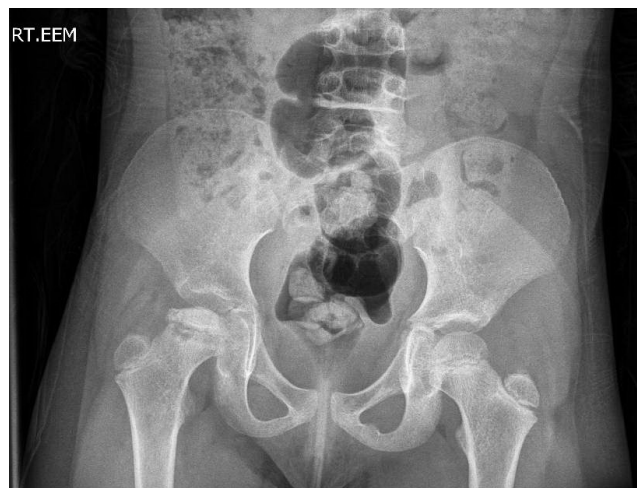**Figure 1:** MRI right hip-right sided joint effusion with collapse of the femoral head indicating avascular necrosis.



**Figure 2:** MRI bilateral—AP-right sided joint effusion with collapse of the femoral head indicating avascular necrosis.



**Figure 3:** Early X-ray—femoral head and neck are normal in appearance. Bilateral acetabula are well formed, no evidence of avascular necrosis.



**Figure 4:** Late X-ray with evidence of perthes on the right, right joint effusion which is likely reactive in nature secondary to avascular necrosis.

## Discussion

There are many reported side effects of the recombinant hGH (rhGH) in children. These include pain and rash at the injection site, idiopathic intracranial hypertension, lymphedema, insulin resistance,

arthralgia and pre pubertal gynecomastia [8,9]. Due to rapid growth and cell multiplication caused by GH therapy in children orthopedic complications such as progression of scoliosis, slipped capital femoral epiphysis and Perthes disease may develop [7]. Therefore, in our patient the concern of developing SCFE led to getting the lower extremity MRI done.

Children with GHD are prone to development of slipped capital femoral epiphysis (SCFE). It is defined as a inferior and posterior displacement of the proximal femoral epiphysis on the femoral neck [9]. It occurs during periods of rapid height gain therefore rhGH replacement therapy may increase the risk by sevenfold. Children on growth hormone therapy complaining of unilateral or bilateral pain in the hips or knees should be evaluated for SCFE. LCPD is suggested to be a manifestation of generalized growth disturbance. The patients are found to be shorter with a retarded bone age and abnormal hormonal status suggesting a disturbance in the pituitary growth hormone axis as a predisposing factor in development of LCPD. Compared to the normal population IGF-1 levels have been found to be lower in Perthes disease patients [8]. However, contradicting this theory is a study conducted in Finland on LCPD. Patients had normal IGF-1 levels showed a variety of growth abnormalities. Some had a normal stature with catch up growth before disease onset. Others had normal stature but abnormal GH values and a few had short stature, retarded bone age and diminished growth velocity. The etiology of short stature among these LCPD patients was thought to be associated with skeletal immaturity [10].

A study conducted in Japan did a retrospective review of 6343 patients with GH deficiency. These patients received 0.5 I/kg/week of recombinant GH. Slipped capital femoral epiphysis (SCFE) developed in 4 cases and Perthes disease developed in 12 boys; 9 cases prior to GH therapy and 3 cases during GH therapy [7]. During the GH therapy neither recurrence nor aggravation of Perthes disease was observed. Scoliosis developed in 18 cases; 12 prior to GH therapy and 6 during GH therapy. Rappaport and Fife reported GH deficient patients receiving GH had an increase in Perthes disease with chronic renal failure further increasing the risk. However, there are no studies available on continuing growth hormone therapy on patients diagnosed with Legg Calve Perthes disease. An article reviewing the orthopedic complications associated with GH therapy reported a case of a boy started on GH therapy at the age of 9 months. At 3 years and 8 months of age he developed left LCPD but his GH therapy was continued and he was treated conservatively. One year later he developed a right sided LCPD. Follow up after 17 years showed asymptomatic mobile hips. The authors suggested once the patient on GH therapy has been diagnosed with LCPD treatment should be stopped to decrease severity of the disease and prevent contralateral disease [11]. Most patients with Perthes disease have unilateral hip involvement. Bilateral involvement occurs in only 8-24% of cases [12].

Even though LCPD is more commonly seen in boys, there has been no difference between genders as far as final radiographic outcome is concerned. The common clinical presentations are a painless limp or knee pain referred from the hip. Radiographs are the best imaging

modality for both initial diagnosis and subsequent follow up. It has been reported that a younger onset has a better prognosis regardless of treatment. To improve joint mechanics older children with more advanced disease need to undergo operative management [13]. Our patient, a girl on growth hormone therapy for 2 years was diagnosed to have right LCPD. Based on clinical judgment and no previous literature it was decided to continue her on GH at a low dose. The patient continued to do well and will be followed in clinic along with radiographs.

This case is notable as it represents the only case in literature of a girl diagnosed with Legg Calve Perthes Disease on growth hormone therapy. With limited data available, she continued to receive growth hormone therapy at a dose of half of what was required.

## References

1. Mazlomi, Seyed Mehdi, Mohammad H. Ebrahimzadeh, Amir Reza Kachooei (2014) "Evolution in Diagnosis and Treatment of Legg-Calve-Perthes Disease." *Arch Bone Jt Surg* 2: 86-92.
2. Hailer YD, Nilsson O (2014) Legg-Calvé-Perthes disease and the risk of ADHD, depression, and mortality. *Acta Orthop* 85: 501-505.
3. Hailer YD, Montgomery S, Ekblom A, Nilsson O, Bahmanyar S (2012) Legg-Calvé-Perthes disease and the risk of injuries requiring hospitalization: a register study involving 2579 patients. *Acta Orthop* 83: 572-576.
4. Bahmanyar S, Montgomery SM, Weiss RJ, Ekblom A (2008) Maternal smoking during pregnancy, other prenatal and perinatal factors, and the risk of Legg-Calvé-Perthes disease. *Pediatrics* 122: e459-464.
5. Mehls O, Ritz E, Krempien B, Gilli G, Link K, et al. (1975) Slipped epiphyses in renal osteodystrophy. *Arch Dis Child* 50: 545-554.
6. Mehls O, Broyer M (1994) Growth response to recombinant human growth hormone in short prepubertal children with chronic renal failure with or without dialysis. The European/Australian Study Group. *Acta Paediatr Suppl* 399: 81-87.
7. Nishi, Yoshikazu, Toshiaki Tanaka, Kenji Fujieda, Kunihiko Hanew, Takeki Hirano, et al. (1998) "Slipped Capital Femoral Epiphysis Perthes' Disease and Scoliosis in Children with Growth Hormone Deficiency." *Endocrine Journal* 45: S167-S169.
8. Bas Veysal, Salih Uytun, Umit Urkan Vurdem, Yasemin Altuner Torun () "Hypopituitarism and Legg-Calve-Perthes Disease Related to Difficult Delivery: A Case Report." *Korean J Pediatr*.
9. Souza Flavio Moutinho, Paulo Ferrez Collett-Solberg (2011) "Adverse Effects of Growth Hormone Replacement Therapy in Children." *Arquivos Brasileiros De Endocrinologia & Metabologia* 55: 559-565.
10. Lahdes-Vasama TT, Sipilä IS, Lamminranta S, Pihko SH, Merikanto EO, et al. (1997) "Psychosocial Development and Premorbid Skeletal Growth in Legg-Calvé-Perthes Disease: A Study of Nineteen Patients." *Journal of Orthopedic Pediatrics Part B* 6: 133-137.
11. Docquier PL, Mousny M, Joret M, Bastin C, Rombouts JJ (2004) Orthopaedic concerns in children with growth hormone therapy. *Acta Orthop Belg* 70: 299-305.
12. Grzegorzewski A, Synder M, Szymczak W, Kozłowski P, Sibiński M (2004) Bilateral Perthes' disease. *Ortop Traumatol Rehabil* 6: 567-574.
13. Chaudhry S, Phillips D, Feldman D (2014) Legg-Calvé-Perthes disease: an overview with recent literature. *Bull Hosp Jt Dis* (2013) 72: 18-27.