

Case Report

Open Access

Post-operative Rehabilitation of a Bilateral Uncemented Total Hip Replacement Rheumatoid Arthritis Patient. A Case Study

Hitesh Arora* and Rakhi Ratnam

Department of Physiotherapy, Cygnus Orthocare Hospital, New Delhi, India

*Corresponding author: Hitesh Arora, Department of Physiotherapy, Cygnus Orthocare Hospital, New Delhi, India, Tel: 9958899366; E-mail: hitesh2arora@gmail.com

Received date: October 10, 2016; Accepted date: November 28, 2016; Published date: December 05, 2016

Copyright: © 2016 Arora H, et al. This is an open-access article distributed under the terms of the Creative Commons Attribution License, which permits unrestricted use, distribution, and reproduction in any medium, provided the original author and source are credited.

Abstract

Background and Purpose: Total hip replacement (THR) is one of the most frequently performed orthopedic surgery in India and worldwide. Thousands of people undergo THR every year in hopes of improving their functional abilities and reducing their disability levels. The purpose of this case report is to document acute care outcome measures in Rheumatoid arthritis patient who had undergone bilateral THR and to assess the possible implications that a short staging period might have on the patient's ability to recover.

Case Presentation: A 44 years old rheumatoid arthritis patient with severe restriction in mobility had undergone bilateral Uncemented total hip replacement following which patient was rehabilitated for strength, gait and functional abilities.

Outcomes: Modified Harris Hip Score was taken preoperatively, Post-operative day 6, 3 weeks, 6 weeks for both the hips.

Discussion: Many studies support an early and intensive Physiotherapy following THR but there are limited literature on rehabilitation in case of rheumatic arthritis patient who had undergone bilateral THR. This study includes an early acute care Physiotherapy from day 1 up to 6 weeks which helped the patient in resuming his daily activities early.

Keywords: Uncemented THR, Rheumatoid arthritis, Modified Harris Hip Score

Background

Rheumatoid arthritis (RA), a systemic autoimmune inflammatory disease, affects 1.3 million adults in the United States annually, as reported in 2003. Rheumatoid arthritis is characterized by destructive erosion of bone and loss of joint integrity and frequently leads to disability. Individuals with RA are 8 times more likely to have functional disability compared with adults in the general population from the same community and when untreated; 20% to 30% of patients have permanent work disability within the first 3 years of diagnosis [1].

It is the most frequent inflammatory joint disorder with a prevalence of nearly 1% in adults [2]. RA occurs worldwide, in all climates, and affects all ethnic groups to varying degrees. Recent studies of rheumatoid arthritis worldwide suggest that prevalence of arthritis is higher in Europe and North America than in developing countries [3].

There are no disease characteristics with 100% sensitivity and specificity. That is why the diagnosis of RA is made on the basis of medical history, physical examination, clinical chemistry and immunology examinations, and radiology findings. The American College of Rheumatology (ACR) defined seven criteria to classify RA [4]: (1) morning stiffness in involved joints for at least one hour. (2) Arthritis for at least 6 weeks in three or more defined joints. (3)

Arthritis in the joints of the hand. (4) Symmetrical arthritis. (5) Rheumatoid nodules. (6) Positive rheumatoid factor test. (7) Radiological changes typical for RA with periarticular decalcification, cartilage reduction or erosion. A clinical profile including at least four of the seven criteria is considered consistent with the diagnosis of RA.

The hip joint is affected in 15% to 30% of all RA patients [5]. In the end 10 to 25% of all RA patients undergo THA [6]. Total hip replacement (THR) is one of the most successful and cost-effective of surgical procedures with the primary goals of pain relief and restoration of function [7]. It has been one of the most successful operations in orthopedic surgery. By alleviating pain and disability, it has helped patients to return to active life. Several hundreds of thousands hip replacements are conducted every year, worldwide. Technical challenges of performing THR in patients with RA are mainly due to bone loss, osteopenia and protrusio acetabuli. These patients are not suitable for hip resurfacing because of the risk of secondary osteoporosis [8]. Protrusio acetabuli is a common occurrence in the rheumatoid hip and technical difficulties can be encountered due to medial wall deficiency. Two grading systems are used; that of Charnley [9], relative to the ilio-pectineal line, and more commonly Hirst et al. [10], relative to the ilio-ischial line. More extensive acetabular destruction in Grade III protrusio may require a cage and additional bone grafting to prevent early failure.

Grading of protrusio acetabuli according to the distance between the acetabular line (medial wall of acetabulum) and the ilio-ischial line (Table 1) [11].

Grade	Men	Women
I	3-8 mm	6-11 mm
II	8-13 mm	12-17 mm
III	>13 mm with fragmentation	>17 mm with fragmentation

Table 1: Grading of protrusio acetabula.

The purpose of this case report was to describe an early postoperative intervention and plan of care for rheumatoid arthritis patient who had undergone bilateral uncemented THR. Unique to this case was the fact that the patient is a young adult with almost 10 years of rheumatism and on steroids, who stopped going to the work because of severity of pain and disability associated, if we achieve to find out the positive effect of early physiotherapy after post-operative THR then it will be a help to the population to achieve functional goals early. There are researches on long term rehabilitation after total hip replacements but there are limited evidences on immediate post-operative care and rehabilitation in rheumatic arthritis patients post THR [12].

Case Description

The patient signed an informed consent to allow use of his personal medical information for this case report. Patient was apparently alright when in year 2005 he had low grade persistent fever and started developing pain in his left hip, he consulted an Orthopedician in his residential area who advised an X-ray of left hip and other blood investigations. X-ray showed a reduction in joint space and patient's tuberculin test was positive. Patient was started with antitubercular drugs which further deteriorated his condition and it became difficult for him to do his household chores. Then patient's attendant took him to the RML hospital where again investigations were done and Patient was diagnosed with rheumatic factor +ve. He was advised with DMARD (Disease modifying anti rheumatic drugs) which included methotrexate; Patient recovered well with the treatment and resumed his work. Now, in year 2016 January, he again started getting pain in his both the hips (left>right). The patient reported that he needed assistance to perform his daily routine activities; he started avoiding going to the work place because of ambulatory difficulties.

Patient was brought to the Cygnus Orthocare Hospital and was admitted after detailed evaluation and planned out for the bilateral uncemented hip replacements which were performed with a gap of 3 days. Modified Harris Hip Scoring was used as an outcome measure to evaluate and compare Preoperative, Day 6th, 3 weeks and 6 weeks level of pain, function, and gait. Pre-operative Harris Hip Score for left hip was 16 and right hip was 33 out of 100 (Figures 1-3).

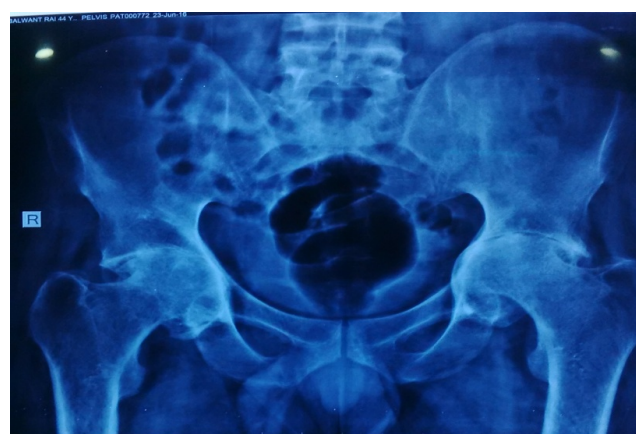

Figure 1: Pre-operative X-ray of pelvis.

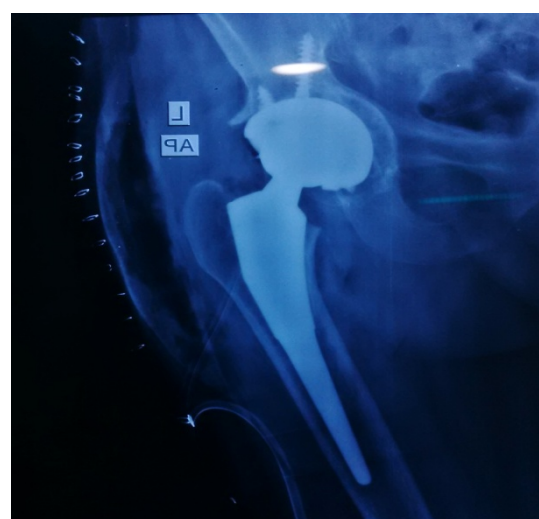


Figure 2: Post-operative X-ray of pelvis.

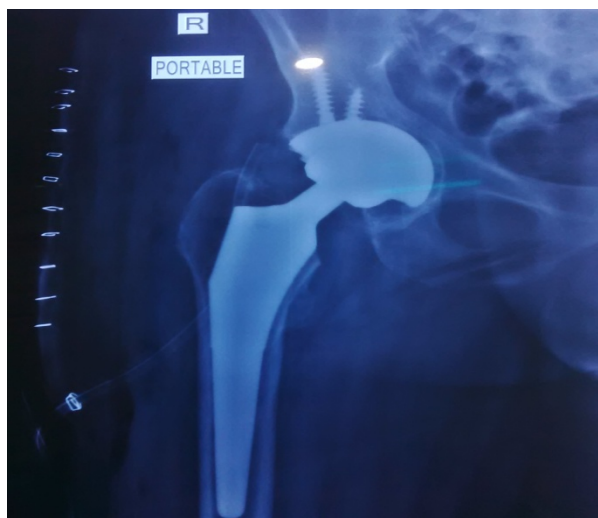

Figure 3: Post-operative X-ray of pelvis.

Day 1-3 Weeks

1. Ankle toe movements to prevent DVT and improve the blood circulation.
2. Isometric strengthening of quadriceps, hamstring, glutei, abductors.
3. High sitting dynamic quadriceps.
4. Ambulation with the Walker with right side full weight bearing and left side weight bearing was restricted to toe touch for 6 weeks, waiting for early graft incorporation and consolidation of the cup-graft-bed construct.

3 Weeks-6 Weeks

1. Along with above exercises active assisted range of movement of abductors.
2. In prone lying: Hip extensors.
3. Partial weight bearing on left side and full weight bearing on right side ambulation with the walker.

6 Weeks onwards

1. Strengthening exercises with 0.5 kg weight cuff tied at ankle.
2. Ambulation with stick (Table 2).

Modified Hip Score(0-100)	Left	Right
Pre-Operative	16	33
Post-operative Day 6 th	38	28
Post-operative 3 rd week	58	58
Post-operative 6 th week	63	67

Table 2: Modified Harris Hip scoring was done postoperatively on 6th day, 3rd week and 6th week with the following scores.

Discussion

Compromised biomechanical properties of rheumatic bone, caused by inflammatory diseases and medication, are potential risk factors for a positive end result of THR in RA patients. With acute intervention of physiotherapy from post-operative day 1 till 6 weeks has improved the outcome measure. These exercises fastened the recovery as well as post-operative pain. All the exercises were done thrice a day with each 10 sets; ice packs were given around the hips of the patient to reduce the exercise induced pain after the therapy session. There are literatures suggestive of implications of rehabilitation after hip replacements in rheumatoid arthritis patients but there is a dearth of studies on acute care and routinely interventions.

In India rheumatic diseases are major cause of morbidity, health care providers and patients face an enormous challenge of providing services to the patients. The cost of medical treatment and hospital stay has to be minimized to reduce the economic burden. To make the post recovery optimal physiotherapy was started in the intensive care unit (ICU) on day 1; patient was made to walk on 3rd day with the help of walker. On day 8th patient was discharged from the hospital with all precautions explained to him in his vernacular language. Home exercise program was explained to the patient and exercise chart was provided to him.

Precautions explained were: Avoid sitting on low floor chairs; avoid cross legs sitting; keep both the legs separated to avoid any dislocation to the hips; avoid stair climbing.

Patient was called on completion of 3rd and 6th weeks consecutively; all the parameters were evaluated and there was an improved Modified Harris Hip Scores on each interval.

Despite such complexities often encountered in RA patients, a well-timed, well executed post-operative rehabilitation of THR patient has been proven to improve overall function and quality of life of patients with disabling RA of the hip. Most challenging part was to make him ambulated with partial weight bearing on left leg due to bone graft and full weight bearing on right leg on 3rd post-operative day it's probably the fixation of the implants with surgeon's skills.

Hence, with these exercise protocols patients can have improved functional outcomes and quality of life in shorter duration.

Further research is needed to determine the most beneficial exercises, frequency, intensity, and duration in order to produce the best functional outcomes. More studies are needed to address the long term prognosis of hip arthroplasties in younger adults. Considering the age of this patient, periodic follow-ups with an orthopedic specialist are essential in helping monitor the integrity of the surgical procedure.

Future scope

1. Large sample size with Randomized clinical and controlled trials
2. More outcome measures mainly SF6, QOL Questionnaire
3. Long term follow-up

Acknowledgement

Authors wish to thank Dr. Pankaj Bajaj for the surgical intervention and explanation, staffs of physiotherapy department and the patient for willingness to participate in the study.

References

1. Iversen MD, Chhabriya RK, Shadick N (2011) Predictors of the use of physical therapy services among patients with rheumatoid arthritis. *Phys Ther* 91: 65-76.
2. Nelissen RG (2003) The impact of total joint replacement in rheumatoid arthritis. *Best Pract Res Clin Rheumatol* 17: 831-846.
3. Akhter E, Bilal S, Kiani A, Haque U (2011) Prevalence of arthritis in India and Pakistan: a review. *Rheumatol Int* 31: 849-855.
4. Arnett FC, Edworthy SM, Bloch DA, McShane DJ, Fries JF, et al. (1988) The American Rheumatism Association 1987 revised criteria for the classification of rheumatoid arthritis. *Arthritis Rheum* 31: 315-324.
5. Eberhardt K, Fex E, Johnsson K, Geborek P (1995) Hip involvement in early rheumatoid arthritis. *Ann Rheum Dis* 54: 45-48.
6. Weiss RJ, Stark A, Wick MC, Ehlin A, Palmblad K, et al. (2006) Orthopaedic surgery of the lower limbs in 49,802 rheumatoid arthritis patients: results from the Swedish National Inpatient Registry during 1987 to 2001. *Ann Rheum Dis* 65: 335-341.
7. Rothman RH, Cohn JC (1990) Cemented versus cementless total hip arthroplasty. A critical review. *Clin Orthop Relat Res* 254: 153-169.
8. Guidance on the use of metal on metal hip resurfacing arthroplasty (2002).
9. Sotelo-Garza A, Charnley J (1978) The results of Charnley arthroplasty of hip performed for protrusio acetabuli. *Clin Orthop Relat Res* 132: 12-8.
10. Hirst P, Esser M, Murphy JC, Hardinge K (1987) Bone grafting for protrusio acetabuli during total hip replacement. A review of the Wrightington method in 61 hips. *J Bone Joint Surg Br* 69: 229-233.
11. Goldberg VM, Figgie MP, Figgie HE, Heiple KG, Sobel M (1988) Use of total condylar knee prosthesis for treatment of osteoarthritis and rheumatoid arthritis. Long-term results. *J Bone Joint Surg Am* 70: 802-811.
12. Nilsson A, Bremander A (2011) Measures of hip function and symptoms: Harris Hip Score (HHS), Hip Disability and Osteoarthritis Outcome Score (HOOS), Oxford Hip Score (OHS), Lequesne Index of Severity for Osteoarthritis of the Hip (LISOH), and American Academy of Orthopedic Surgeons (AAOS) Hip and Knee Questionnaire. *Arthritis Care Res (Hoboken)* 63 Suppl 11: S200-207.