

# Post-frenotomy Methemoglobinemia Associated with Mepivacaine Use in a 3 Day Old

Jahn T Avarello<sup>1\*</sup>, Amit Gupta<sup>2</sup> and Robert A Silverman<sup>3</sup>

<sup>1</sup>Department of Pediatrics, Division of Pediatric Emergency Medicine, Cohen Children's Medical Center of New York, USA

<sup>2</sup>Department of Emergency Medicine, North Shore University Hospital, 300 Community Dr, Manhasset, NY 11030, USA

<sup>3</sup>Department of Emergency Medicine, Long Island Jewish Medical Center, NY 11040, USA

## Abstract

**Background:** With the increased numbers of babies breast-feeding over the last 10 years, there has been a higher incidence of frenotomies performed to increase the success of breast feeding. Frenotomies are often performed after administering topical or local injections of anesthetic agents.

**Objective:** To report a case of methemoglobinemia after a procedure that has become more prevalent in the neonatal age group.

**Case report:** We report a 3 day old male who presented with methemoglobinemia shortly after the amide anesthetic mepivacaine was used in performing a frenotomy. The infant had classic signs of methemoglobinemia and treatment was successfully administered with favourable outcomes.

**Summary:** Neonates have lower amounts and activity of NADH-cytochrome b5 reductase (methemoglobin reductase) therefore putting them at more risk for methemoglobinemia when exposed to oxidizing chemicals such as topical or injectable anesthetics. After the use of local anesthetics for a minor procedure, clinicians should be aware of the risks for developing methemoglobinemia in this age group.

**Keywords:** Methemoglobinemia; Neonatal methemoglobinemia; Frenotomy; Methemoglobin reductase; Cyanosis

## Introduction

Although neonatal frenotomy is not a new procedure, there seems to be an increased incidence over the past decade. Even with some controversy over the utility of the procedure and its benefits to the breast-feeding child, more neonates are being referred for ankyloglossia related frenulum repairs as breast-feeding has gained popularity. The frenulum is poorly innervated and does not necessarily need an anesthetic for a frenotomy but some practitioners still use a combination of both topical and injectable anesthetics. These anesthetics put the patient at risk for complications such as methemoglobinemia [1].

## Case Report

A 3 day old Caucasian male presented in the Emergency Department (ED) with the parents stating that he was blue. He was a home birth born via normal spontaneous vaginal delivery to a healthy mother with a midwife present. He was seen on day 2 of life by the pediatrician for an impetiginous like rash and prescribed mupirocin and nystatin creams. He was also noticed to have trouble latching on to the mother's breast and diagnosed with ankyloglossia (commonly known as tongue tie). The parents were encouraged to have a frenotomy to improve the success of breast-feeding. The frenotomy was done on the day of presentation to the ED. On the way home from the procedure the parents noticed that the child had a blue color to him. He did not have any difficulty breathing or appear to be in any distress so they brought him to their pediatrician for evaluation. The pediatrician found his pulse oximetry to be approximately 88% and he was subsequently sent to the ED for further evaluation.

His past medical history was only significant for the impetiginous rash and the frenotomy earlier in the day. His medications consisted of mupirocin and nystatin creams. He did not have any known allergies and his review of systems was only relevant for the difficulty breast feeding and rash on his face.

On physical presentation the Vital signs were as follows: BP-69/45

(with similar values on all limbs), P-141, RR-44 and a Pulse oximetry reading of 86% with a good wave form in the right upper and lower extremity. The baby appeared cyanotic but comfortable and in no distress. Head was normocephalic and atraumatic, anterior fontanelles open soft and flat. Extraocular movements were intact, sclera non-icteric. Mouth had moist mucous membranes. A white lesion was noted at the tongue frenulum without any bleeding. There was an impetiginous appearing rash on both cheeks without any discharge. The neck was supple and without nuchal rigidity. The chest was clear to auscultation bilaterally without retractions. The heart had a regular rate and rhythm with a normal sounding S1 and S2 and no murmurs, rubs or clicks. Strong femoral pulses were felt bilaterally and the capillary refill was less than 2 seconds in the upper and lower extremities. Abdomen was soft and non-distended without hepatosplenomegaly. There was no cry or grimace to palpation of the abdomen. The umbilical cord was attached, clean and dry. Penis was uncircumcised and the testes were descended bilaterally. The extremities had full range of motion at all joints and no obvious deformities. The skin was cyanotic and had a normal turgor. Neurologically he was moving all extremities spontaneously, had a positive rooting and more response and was acting appropriate for age.

The patient was immediately put on 100% oxygen non-rebreather and placed in a warmer. The oxygen saturation by pulse oximetry on

**\*Corresponding author:** Jahn T Avarello, Department of Pediatrics, Division of Pediatric Emergency Medicine, Cohen Children's Medical Center of New York, 270-05 76th Ave, New Hyde Park, NY 11040, USA, Tel: (718)470-7501; E-mail: javarello@nshs.edu

**Received** January 17, 2013; **Accepted** January 18, 2013; **Published** January 25, 2013

**Citation:** Avarello JT, Gupta A, Silverman RA (2013) Post-frenotomy Methemoglobinemia Associated with Mepivacaine Use in a 3 Day Old. Emergency Med 3: 131. doi:10.4172/2165-7548.1000131

**Copyright:** © 2013 Avarello JT, et al. This is an open-access article distributed under the terms of the Creative Commons Attribution License, which permits unrestricted use, distribution, and reproduction in any medium, provided the original author and source are credited.

the right arm and lower limb increased to 91%. ECG showed a normal sinus rhythm with a normal t-wave pattern for age (upright in V1- V6) and the chest X-ray did not show any abnormalities. An intravenous catheter was placed and the bedside glucose was 107 mg/dl, with other laboratory results shown in table 1. An arterial blood gas was performed (Table 2) while the infant was on 100% oxygen by way of a non- rebreather. When the arterial blood gas was drawn the blood that dripped onto the sheets was a dark brownish color and did not become brighter in color when exposed to the air. Of note the ABG revealed a Methemoglobin level of 37.5%, the PaO<sub>2</sub> was 322 and the O<sub>2</sub> sat was 96%.

Methylene blue was given at a dose of 1 mg/kg and within 5 minutes the child was acyanotic and back to his normal coloration as per the parents. After the child was stabilized we received information that the oral surgeon who performed the procedure used both topical and injectable mepivacaine as an anesthetic for the frenotomy. He was subsequently admitted overnight to the pediatric floor for observation where he did well without any further episodes of cyanosis.

## Discussion

Methemoglobin occurs when the iron atom in hemoglobin loses one electron to an oxidant, and the ferrous (Fe<sup>2+</sup>) state of iron is transformed into the ferric (Fe<sup>3+</sup>) state. Under normal circumstances, methemoglobin is reduced to functional hemoglobin by NADH cytochrome-b5 reductase (major pathway) and NADPH methemoglobin reductase (minor pathway) to maintain methemoglobin at levels less than 1% in healthy individuals [2]. This is important since hemoglobin only transports oxygen in the reduced ferrous state and when oxidized, this abnormal hemoglobin is unable to carry oxygen causing a functional anemia. Further hypoxia occurs since ferric heme groups impair the release of oxygen from nearby ferrous heme groups on the same hemoglobin tetramer and causing a shift of the oxygen-dissociation curve to the left.

Topical anesthetics have been implicated in toxic methemoglobinemia cases by way of their oxidative effects. Topical ester anesthetics such as Cetacaine spray<sup>®</sup> (14% benzocaine, 2% tetracaine, 2% butyl aminobenzoate) and Hurricane spray<sup>®</sup> (20% benzocaine) are agents that are often implicated [3]. In a publication that evaluated adverse events reported to the FDA over a 5 year span, that there were 132 cases of benzocaine induced methemoglobinemia [4]. Although multiple other ester and amide anesthetics have been implicated in acquired methemoglobinemia, the authors have not found any medical literature implicating mepivacaine specifically as a cause of methemoglobinemia.

Methemoglobinemia most commonly results from exposures to an oxidizing chemical (Table 2) but may also arise from dietary, environmental, genetic or idiopathic etiologies. In rural areas well water may contain high levels of nitrates, from fertilizer runoff, and can cause methemoglobinemia especially in young infants [5]. Nitric oxide used to treat persistent pulmonary hypertension of the newborn

is a potent oxidant may develop methemoglobinemia [6]. There are several hundred cases reported in the literature of hereditary methemoglobinemia and although rare, may occur due to NADH-cytochrome b5 reductase deficiency or haemoglobin M disorders [7,8]. This condition is different from inherited or acquired methemoglobin reductase deficiency and will therefore not respond to reducing agents such as methylene blue [9]. Recessive Congenital Methemoglobinemia (RCM) is an autosomal recessive disorder caused by a deficiency of the NADH cytochrome b5 reductase and is found in two clinical forms, type 1 and type 2 [10].

Infants less than 3 months of age are particularly susceptible to methemoglobinemia for several reasons [2,11]: they have lower amounts and activity of NADH-cytochrome b5 reductase; their lower gastric pH results in the proliferation of intestinal flora that reduces ingested nitrates to nitrites [12]; and fetal hemoglobin is more easily oxidized to methemoglobin than adult hemoglobin.

In our 3 day old infant we strongly suspected methemoglobinemia because of the chocolate brown colored blood (which is known characteristic of methemoglobinemia), the oxygen saturation levels of 86% which only minimally increased after administration of supplemental oxygen, as well as the lack of respiratory distress. Observing the discoloration is often referred to as the bedside test for methemoglobinemia as deoxyhemoglobin should theoretically brighten after exposure to the air while methemoglobin tends to stay the dark chocolate brown color [11,13].

Patients with methemoglobinemia typically have abnormal pulse oximetry readings within a very narrow range, with oxygen saturation values typically in the mid 80's [2,11,14]. The reason for the low saturation is that traditional pulse oximeters function by transilluminating tissue at two wavelengths of light with oxyhemoglobin absorbing strongly at the spectrophotometer at 940 nm, whereas deoxyhemoglobin absorbs at 660 nm. Methemoglobin absorbs strongly at both 660 and 940 nm and therefore the ratio of light absorbance at the two wavelengths become unified, and as the methemoglobin level reaches and exceeds approximately 30-35%, the derived value on traditional pulse oximeters reads at approximately 85% [14]. Reporting lower measured oxygen saturation relative to the calculated oxygen saturation yielded from the arterial blood gas is known as the oxygen saturation gap. Standard blood gas analyzers calculate oxygen saturation from a relationship between the partial pressure of oxygen the pH and the hemoglobin level that is then plotted on a nomogram. If the partial pressure of oxygen is normal (which is typical for methemoglobinemia) and the other variables are normal, the blood gas analyzer calculates normal oxygen saturation. The difference between this and the pulse oximetry reading is known as the oxygen saturation gap and methemoglobinemia should highly be considered. Newer bedside oximeters that utilize multi- wavelength technology to identify other forms of hemoglobin (methemoglobin, carboxyhemoglobin) are available and have been shown to be a valuable bedside tool [15]. Sulfhemoglobinemia is another hemoglobinopathy similar to methemoglobinemia but in contrast is irreversible and

<b>ABG</b>	pH 7.36	pCO <sub>2</sub> 32.6	pO <sub>2</sub> 322	SO <sub>2</sub> 96	BE 5.4	COHb 1.7%	MetHb 37.4%
<b>CBC</b>	WBC 11.9	HGB 17.3	HCT 51.9	PLT 434			
<b>BMP</b>	Na 140	K 3.9	Cl 107	CO <sub>2</sub> 20	BUN 14	Glu 82	

Table 1: Arterial blood gas, complete blood count and basic metabolic panel results.

<b>Medications</b>	<b>Other Xenobiotics</b>
Amyl nitrite, Benzocaine, Dapsone, Lidocaine, Nitric Oxide, Nitroglycerin, Nitroprusside, Phenazopyridine, Prilocaine, Quinones, Sulfonamides	Aniline dye derivatives, chlorobenzene, Isobutyl nitrite, Naphthalene, Nitrates (i.e. well water), Nitrites, Nitrous gases

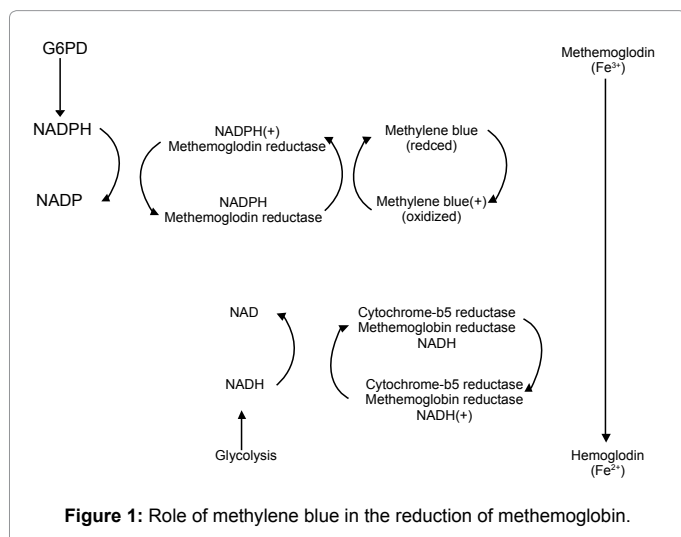
Table 2: Common oxidizing chemicals that may result in methemoglobinemia.

does not have any known antidote. Although extremely rare in the pediatric patient population, it can present nearly identically to methemoglobinemia. Patients may appear cyanotic with an oxygen saturation gap, a pulse oximetry reading in the mid 80's, and a normal measured PaO<sub>2</sub>. If patients with suspected methemoglobinemia are given methylene blue but do not improve, sulfhemoglobinemia should be considered [16].

Although typically not life threatening methemoglobinemia may produce symptoms of cellular hypoxia and lead to death if not treated properly. The diagnosis should be considered in the differential diagnosis in any cyanotic patient. Cyanosis can occur when just 10% of methemoglobin is present (1.5 g/dL with baseline hemoglobin of 15 g/dL) [11]. Concurrent diseases such as anemia, congestive heart failure, chronic lung disease, and pneumonia may greatly increase the clinical effects of methemoglobinemia with clinical signs of hypoxia occurring at even lower methemoglobin blood levels.

Methylene blue is a highly effective antidote for treating acquired methemoglobinemia. Methylene blue therapy is indicated if levels exceed 25% or if the patient has clinical signs of hypoxia. In neonates, the dose is 0.3-1 mg/kg as a 1% solution slow IV over 3-5 minutes and beneficial effects usually occur within 30 minutes; typically the dose does not need to be repeated [17]. Methylene blue is an oxidizing agent, which, in the presence of NADPH methemoglobin reductase, is reduced to leukomethylene blue. Leukomethylene blue then becomes available to reduce methemoglobin to hemoglobin [18]. In the presence of methylene blue, the role of the NADPH pathway is dramatically increased and becomes the most efficient means of methemoglobin reduction (Figure 1). Because of its oxidizing properties, methylene blue is contraindicated in diseases such as G6PD deficiency where oxidizing agents can be lethal. Methylene blue is a dye and will also alter pulse oximetry readings secondary to the interference with light absorption, further decreasing the pulse oximetry readings. To avoid frightening parents and patients, it is important to inform treatment may impart a bluish-green discoloration to the urine [19].

In the case of this infant, the anesthetic mepivacaine appeared to cause the methemoglobinemia. While the diagnosis was made in the ED and treatment was initiated and the infant did well, hospitalization for further observation was required. In reference to performing a frenotomy, there have been suggestions that local anesthesia is not needed since the frenulum is almost devoid of sensory innervation [20].



## Conclusion

Since infants have lower levels and activity of NADH-cytochrome b5 reductase, methemoglobinemia can occur after exposure to oxidizing chemicals like that of local anesthetics. For this reason, caution should be taken when using these substances in any infant. Methemoglobinemia is a well-known reaction and should, at the very least, be understood as a possible side-effect prior to the administration of an oxidizing anesthetic.

## References

- Messner AH, Lalakea ML, Aby J, Macmahon J, Bair E (2000) Ankyloglossia: Incidence and Associated Feeding Difficulties. *Arch Otolaryngol Head Neck Surg* 126: 36-39.
- Wright RO, Lewander WJ, Woolf AD (1999) Methemoglobinemia: Etiology, Pharmacology, and Clinical Management. *Ann Emerg Med* 34: 646-656.
- Aepfelbacher FC, Breen P, Manning WJ (2003) Methemoglobinemia and topical pharyngeal anesthesia. *N Engl J Med* 348: 85-86.
- Moore TJ, Walsh CS, Cohen MR (2004) Reported adverse event cases of methemoglobinemia associated with benzocaine products. *Arch Intern Med* 164: 1192-1196.
- Kross BC, Ayebo AD, Fuortes LJ (1992) Methemoglobinemia: nitrate toxicity in rural America. *Am Fam Physician* 46: 183-188.
- Weinberger B, Laskin DL, Heck DE, Laskin JD (2001) The toxicology of inhaled nitric oxide. *Toxicol Sci* 59: 5-16.
- Ash-Bernal R, Wise R, Wright SM (2004) Acquired Methemoglobinemia: A Retrospective Series of 138 cases at 2 Teaching Hospitals. *Medicine* 83: 265-273.
- Horst J, Schäfer R, Kleihauer E, Kohne E (1983) Analysis of the Hb M Milwaukee mutation at the DNA level. *Br J Haematol* 54: 643-648.
- Spears F, Banerjee A (2008) Hemoglobin M variant and congenital methemoglobinemia: methylene blue will not be effective in the presence of hemoglobin M. *Can J Anaesth* 55: 391-392.
- Hegesh E, Hegesh J, Kaffory A (1986) Congenital methemoglobinemia with a deficiency of cytochrome b5. *N Engl J Med* 314: 757-761.
- Lee DC, Tarabar A (2011) Methemoglobinemia in Emergency Medicine.
- Hanukoglu A, Danon PN (1996) Endogenous Methemoglobinemia Associated with Diarrheal Disease in Infancy. *J Pediatr Gastroenterol Nutr* 23: 1-7.
- Henretig FM, Gribetz B, Kearney T, Lacouture P, Lovejoy FH (1988) Interpretation of color change in blood with varying degree of methemoglobinemia. *J Toxicol Clin Toxicol* 26: 293-301.
- Barker SJ, Tremper KK, Hyatt J (1989) Effects of methemoglobinemia on pulse oximetry and mixed venous oximetry. *Anesthesiology* 70: 112-117.
- Barker SJ, Curry J, Redford D, Morgan S (2006) Measurement of carboxyhemoglobin and methemoglobin by pulse oximetry: a human volunteer study. *Anesthesiology* 105: 892-897.
- Gharahbaghian L, Massoudian B, Dimassa G (2009) Methemoglobinemia and sulfhemoglobinemia in two pediatric patients after ingestion of hydroxylamine sulphate. *West J Emerg Med* 10: 197-201.
- Howland MA (2006) Methylene Blue: Antidotes in Depth. Goldfrank LR, Flomenbaum N In: *Goldfrank's Toxicologic Emergencies*. (8th edn), McGraw-Hill, New York.
- Goodman LS, Gilman A (1975) *The Pharmacologic Basis of Therapeutics*. (5th edn), Macmillan, New York.
- Coleman MD, Coleman NA (1996) Drug-Induced Methaemoglobinaemia Treatment Issues. *Drug Safety* 14: 394-405.
- Academy of Breastfeeding Medicine (2004) Protocol # 11: Guidelines for the evaluation and management of neonatal ankyloglossia and its complications in the breastfeeding dyad.