

# Post-Blebitis Cystoid Macular Oedema Treated with Subconjunctival Triamcinalone

Moneesh Patel\*, Fayyaz Musa and Stephen Vernon

Department Ophthalmology, Queens Medical Centre, Derby Road, Nottingham, UK

## Introduction

We describe a case of post-blebitis related cystoid macular oedema (CMO) successfully treated with subconjunctival triamcinolone (SCTA).

## Case Report

A 73 year old lady presented with a left blebitis, mild anterior chamber activity and a best corrected visual acuity of 6/12. Ten years previously she had a left trabeculectomy augmented with mitomycin-C and left uncomplicated cataract surgery six years following that. Her postoperative period had been uneventful and a visual acuity of 6/7.5 was achieved. Her blebitis was treated successfully with topical antibiotics and steroids. However, her visual acuity gradually deteriorated to 6/36 after two months. OCT and fluorescein angiography confirmed gross CMO. This did not resolve despite four weeks of treatment with topical steroids and NSAIDs. 40 mg of SCTA was injected infero-temporally at the slit lamp. 6 weeks later her visual acuity recovered to 6/7.5 with her OCT returning to normal (Figure 1 and Figure 2). Six months following SCTA her visual acuity remained at 6/7.5 with a normal OCT. None of the known side effects of the treatment were observed and her intraocular pressure remained stable at 10 mmHg throughout her treatment.

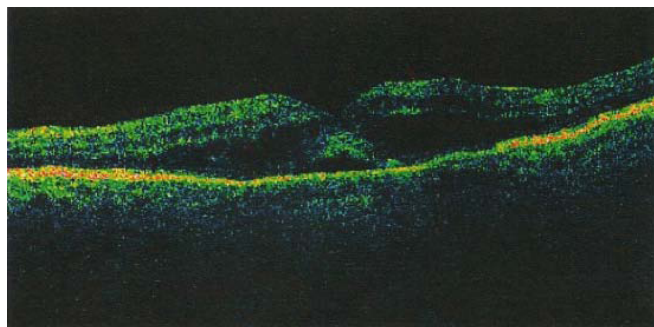


Figure 1: pre-SCTA injection; VA 6/36.

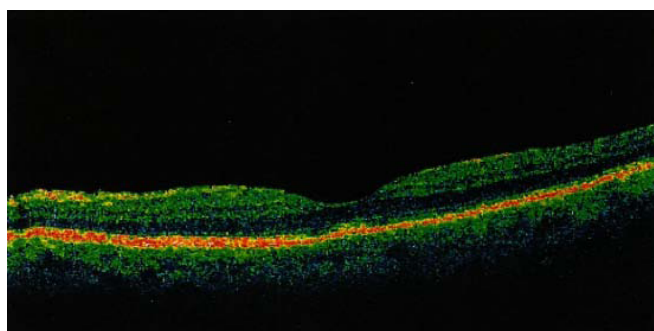


Figure 2: Six months post-SCTA injection; VA 6/7.5.

## Comment

Chronic inflammation leads to increased production of inflammatory mediators which disrupt the inner blood-retinal barrier located at the endothelium of the retinal vessels, with subsequent leakage of fluid. Therefore, control of inflammation is always necessary for successful treatment of CMO. Subconjunctival/subtenons steroids are thought to achieve intraocular penetration mainly through scleral and local vessel absorptions [1].

SCTA/subtenons triamcinalone (STA) have been used previously for a variety of conditions including anterior scleritis [2], diabetic macular oedema [3] and following cataract surgery [4]. However, to our knowledge, its use for treating post-blebitis CMO has not been previously described. SCTA/STA side-effects such as scleral necrosis, scleral perforation, conjunctival ulceration, raised intraocular pressure (IOP) and cataract formation are rare [2]. Injecting triamcinolone subconjunctivally has significant advantages compared with intravitreal administration. It is safer than an intraocular injection, it is cost-effective as theatre or clean room time is not required and if the IOP begins to rise the SCTA can be excised [5].

## References

1. McGhee CN (1992) Pharmacokinetics of ophthalmic corticosteroids. *Br J Ophthalmol* 76: 681-684.
2. Roufas A, Jalaludin B, Gaskin C, McCluskey P (2010) Subconjunctival triamcinolone treatment for non-necrotising anterior scleritis. *Br J Ophthalmol* 94: 743-747.
3. Toda J, Fukushima H, Kato S (2007) Injection of triamcinolone acetate into the posterior sub-tenon capsule for treatment of diabetic macular edema. *Retina* 27: 764-769.
4. Negi AK, Browning AC, Vernon SA (2006) Single perioperative triamcinolone injection versus standard postoperative steroid drops after uneventful phacoemulsification surgery: Randomized controlled trial. *J Cataract Refract Surg* 32: 468-474.
5. Albini TA, Zamir E, Read RW, Smith RE, See RF, et al. (2005) Evaluation of subconjunctival triamcinolone for nonnecrotizing anterior scleritis. *Ophthalmology* 112: 1814-1820.

\*Corresponding author: Moneesh Patel, Department Ophthalmology, Queens Medical Centre, Derby Road, Nottingham, UK, Tel: +0115 9249924; E-mail: [moneeshpatel@hotmail.com](mailto:moneeshpatel@hotmail.com)

Received November 22, 2011; Accepted August 22, 2012; Published August 28, 2012

Citation: Patel M, Musa F, Vernon S (2012) Post-Blebitis Cystoid Macular Oedema Treated with Subconjunctival Triamcinalone. *J Clin Exp Ophthalmol* 3:244. doi:10.4172/2155-9570.1000244

Copyright: © 2012 Patel M, et al. This is an open-access article distributed under the terms of the Creative Commons Attribution License, which permits unrestricted use, distribution, and reproduction in any medium, provided the original author and source are credited.