

Poroid Hidradenoma in a 62-Year-Old Male: A Case Report

Keiji Sugiura* and Mariko Sugiura

Department of Environmental Dermatology & Allergology, Daiichi Clinic, Nakaku, Nagoya, Japan

*Corresponding author: Keiji Sugiura, Department of Environmental Dermatology & Allergology, Daiichi Clinic, Nakaku, Nagoya, Japan, Tel: + 81522040834; E-mail: ksugiura@daiichiclinic.jp

Received date: July 31, 2017; Accepted date: August 31, 2017; Published date: September 04, 2017

Copyright: © 2017 Sugiura K, et al. This is an open-access article distributed under the terms of the Creative Commons Attribution License, which permits unrestricted use, distribution, and reproduction in any medium, provided the original author and source are credited.

Summary

We present a case of poroid hidradenoma on the right chest in a 62-year-old male with diabetes mellitus and chronic renal failure. Poroid hidradenoma is usually solitary and shows eccrine differentiation. There have been a small number of reports describing poroid hidradenoma, and the present case is a rare instance. Because the relations between clear cell neoplasms and diabetes mellitus are known, although it needs to further study of more cases of poroid hidradenoma with diabetes mellitus. Our hypotheses are that poroid hidradenoma may arise in diabetes mellitus patients with sufficient phosphorylase activity, and it may show solid and cystic components without a clear cell appearance.

Keywords: Poroid; Clear cell; Hidradenoma; Eccrine; Apocrine; Diabetes mellitus

Introduction

Ninety-five percent of all hidradenomas show apocrine differentiation, and 5% are characterized by eccrine differentiation [1]. Nodular hidradenoma is divided into poroid hidradenoma and clear cell hidradenoma [2,3]. Clear cell hidradenoma originates from the eccrine glands and is a benign cutaneous tumor [4]. Poroid hidradenoma is usually solitary and shows eccrine differentiation [5], and in rare cases develops malignant changes. Poroid hidradenoma is classified into 4 subtypes based on morphological findings: poroid hidradenoma, hidroacanthoma simplex, eccrine poroma, and dermal duct tumor [5]. We present a rare case of poroid hidradenoma on the right chest in a 62-year-old male with diabetes mellitus.

Case

A 62-year-old-male with a 19-year history of type 2 diabetes mellitus and a 26-year history of chronic renal failure developed a pale-red-swelling on his right chest (Figure 1) a few years ago. His medical condition of diabetes mellitus and chronic renal failure are stable under using some medicines and dialysis. Based on clinical findings, our first diagnosis was epidermal cyst with inflammation, eccrine poroma, keratoacanthoma or fibroma, however, histopathological results after removing the all swelling under local anesthesia indicated poroid hidradenoma (Figure 2). There were no atypical or malignant findings. Now, this patient doesn't have any recurrence.

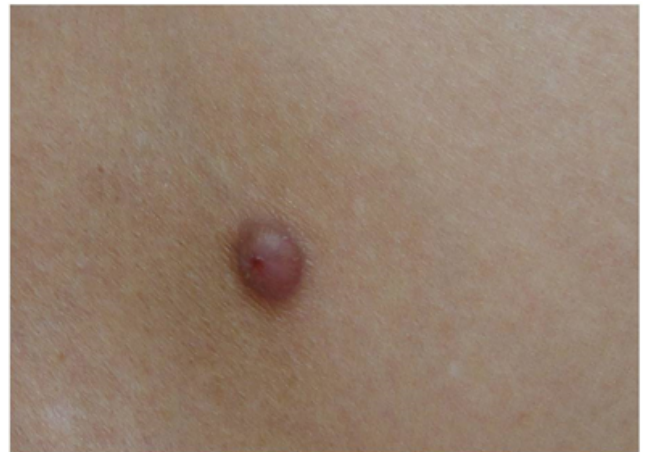

Figure 1: Clinical findings.

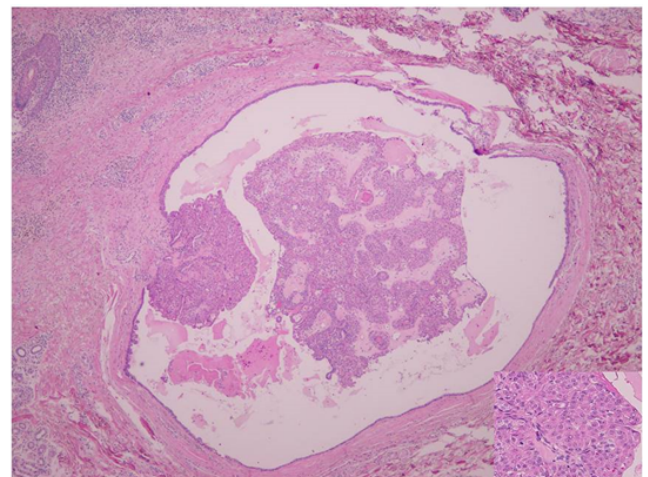


Figure 2: Histopathological findings $\times 40$ (insert $\times 200$).

Discussion

Poroid hidradenoma is located in the dermis without connection to the epidermis, and its components are solid and cystic [6]. Poroid hidradenoma with eccrine differentiation shows lobulated neoplasms within the dermis [1,6]. Based on the present histopathological findings, there were very few clear cells, and our case was therefore

identified as poroid hidradenoma. There have been a small number of reports describing poroid hidradenoma [1,7,8], and the present case is a rare instance. Requena [9] reports the relationship between diabetes mellitus and clear cell neoplasms; the deficiency of phosphorylase activity in patients with diabetes mellitus may be responsible for glycogen accumulation in the clear cell appearance of these neoplasms and the clear cell appearance may be a cutaneous marker of diabetes mellitus. Poroid hidradenoma is a kind of nodular hidradenoma. The present case is not clear cell hidradenoma, but should be differentiated based on eccrine characteristics. Our hypotheses are that poroid hidradenoma may arise in diabetes mellitus patients with sufficient phosphorylase activity, and it may show solid and cystic components without a clear cell appearance in this patient. Further study of more cases of poroid hidradenoma with diabetes mellitus is required, because the relations between poroid hidradenoma and diabetes mellitus are unclear.

References

1. Sergio D, Vito T, Beniamino B, Maria pia di M, Alfonso B, et al. (2007) Poroid Hidradenoma: A Case Report in vivo. 21: 905-908.
2. Nandeesh BN, Rajalakshmi T (2012) A study of histopathologic spectrum of nodular hidradenoma. *Am J Dermatopathol* 34: 461-470.
3. Gianotti R, Alessi E (1997) Clear cell hidradenoma associated with the folliculo-sebaceous-apocrine unit. Histologic study of five cases. *Am J Dermatopathol* 19: 351-357.
4. Abenzoa P, Ackerman B (1990) Poromas. In: *Neoplasms with Eccrine Differentiation*, Vol 1, p113, Lea & Febiger, Philadelphia.
5. Abenzoa P, Ackerman AB (1990) Neoplasms With Eccrine Differentiation. Philadelphia, Lea & Febiger, 113-185.
6. Raquena L, Sanchez M (1992) Poroid hidradenoma: a light microscopic and immunohistochemical study. *Cutis* 50: 43-46.
7. Goksugur N, Yilmaz F (2011) Poroid hidradenoma. *Acta Dermatovenerol Croat* 19: 122-123.
8. Piyush Kumar, Anupam Das, Sushil S Savant (2017) Poroid Hidradenoma: An Uncommon Cutaneous Adnexal Neoplasm. *Indian J Dermatol* 62: 105-107.
9. Requena L, Sarasa JL, Piqué E, Fariña MC, Olivares M, et al. (1997) Clear-cell porocarcinoma: another cutaneous marker of diabetes mellitus. *Am J Dermatopathol* 19: 540-544.