

## Pleura Metastasis from Adrenal Neuroblastoma

Jingyang Guo, Wenzeng Yang<sup>\*</sup>, Haisong Zhang, Yanqiao Zhang, Ruoqing Wei and Song Li

Department of Urology, Affiliated Hospital of Hebei University, Baoding city, Hebei Province, China

<sup>\*</sup>Corresponding author: Wenzeng Yang, Department of Urology, Affiliated Hospital of Hebei University, Baoding city, Hebei Province, China, 071000; E-mail : [hbguojingyang@163.com](mailto:hbguojingyang@163.com)

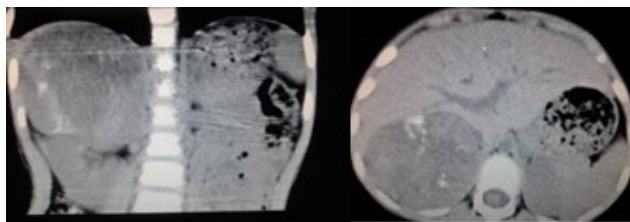
Received Date: June 06, 2016; Accepted date: June 07, 2016; Published date: June 15, 2016

Copyright: © 2016 Guo J, et al. This is an open-access article distributed under the terms of the Creative Commons Attribution License, which permits unrestricted use, distribution, and reproduction in any medium, provided the original author and source are credited.

**Keywords:** Adrenal neuroblastoma; Pleura metastasis; Adults patient

### Case presentation

A 64-year-old man presented with a 15 day history of abdominal distention and anorexia. Physical examination disclosed a solid mass in the upper right abdomen. No fluctuation in blood pressure when pressing the tumor. Enhanced computerized tomographic scan of the upper abdomen showed a huge solid mass on the adrenal area, measuring 9.0 cm × 7.6 cm presumptive diagnosis was a neuroblastoma (Figure 1). The chest CT scan showed a soft tissue density of right pleura which was considered metastatic (Figure 2). No clear abdominal and retroperitoneal lymph nodes were found.



**Figure 1:** A huge mass on the right adrenal area.

### Laboratory examination:

The renin, angiotensin, aldosterone and cortisol, catechol amines were all normal. The urinary VMA (3-methyl, 4-hydroxy mandelic acid) was 68.4 umol/24 h (normal value <85 umol/24 h).

The patient had undergone Laparoscopic adrenalectomy and pleura mass resection in general anesthesia. No intraoperative blood pressure fluctuated. Pathologic analysis confirmed the diagnosis of right adrenal neuroblastoma, also confirmed the pleura soft tissue was metastatic. Immunohistochemistry showed: syn (+), CgA (+), CD56 (+), Ki-67>20%, NF (-), GFAP (-), MB45 (-), CK (-) (Figure 3, 4).

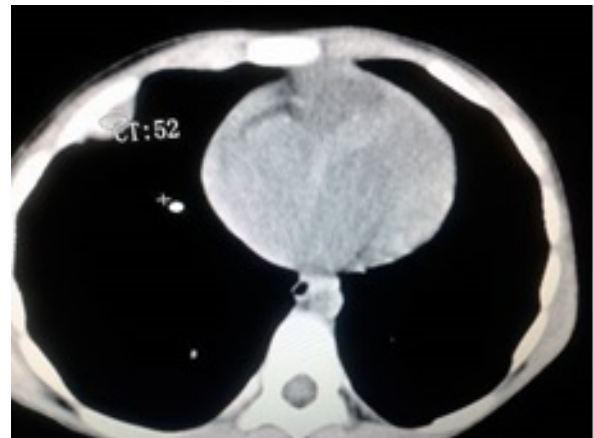### Discussion

Adrenal neuroblastoma is a common tumor in children patients [1,2]. It is derived from the sympathetic nervous system of embryonic malignancies. But rarely occurs in adults [3]. Only a few cases have been reported in adults [1,3,4].

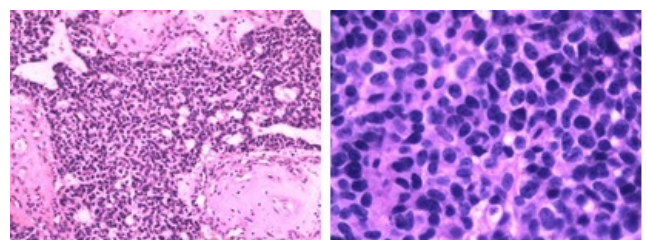
The main adverse prognostic factors were age, more than one year old patients with poor prognosis, low pathological grade and high-stage clinical also affect prognosis. At present, for treatment of adrenal neuroblastoma were drug therapy and surgery. Basic experiments have

confirmed that the vascular endothelial growth factor played a very key role on tumor growth, metastasis and other biological activity [5].

Increased vascular density and micro vascular value-added is the main cause of NB clinical progression and poor prognosis [6-8].



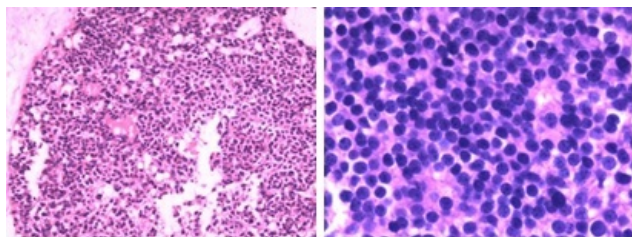
**Figure 2:** A soft tissue mass on the right side of the pleura, pathologic analysis confirmed it was metastatic.



**Figure 3:** Pathological picture of the adrenal tumor.

Angiogenesis inhibitor is a good choice for the treatment of adult malignancies [9] and in NB animals such anti-tumor effect was confirmed [10], this experiment observed the antagonism of Sorafenib for NB's vascular growth factor. Keir and other studies suggest that Sorafenib had a multi-inhibited of the adrenal neuroblastoma cell lines [11].

Since Gagner et al. [12] first reported in 1992, the laparoscopic adrenalectomy in treatment for benign adrenal lesions, laparoscopic surgery has become the gold standard of treatment of benign adrenal diseases. But for adrenal cancer is still controversial.



**Figure 4:** Pathological picture of the pleural metastasis.

As technology continues to mature surgery for smaller adrenal malignancies, laparoscopic surgery are still had value. Haase [13] studied 7 cases of adrenal cancer patients, the mean tumor diameter was  $2.8 \pm 0.9$  cm, mean operative time was  $138.6 \pm 65.5$  m, mean hospital stay was  $2.9 \pm 1.6$  d. Only one patient due to bleeding and giving blood transfusions, all patient follow-up was  $18.8 \pm 6.1$  m. No recurrence and delayed surgical complications. He concluded: For adrenal cancer patients, only in smaller tumors (<6 cm), adrenal gland surrounding anatomical clear no significant adhesions circumstances was suitable for laparoscopy.

Because of the adrenal neuroblastoma's characteristic is invasion growth, the majority of patients in need of open surgery. There are many authors believe that the intraperitoneal is the better surgical approach, and can simultaneously bilateral adrenal exploration areas, and major bleeding complications [14].

## Conclusion

Adult adrenal neuroblastoma combined pleural metastasis rare, surgical removal of lesions and metastases acceptable short-term results, due to lack of large clinical data reported, its long-term effect needs further follow-up.

## References

1. Meltzer S (1926) Neuroblastoma occurring in adults. *Can Med Assoc J* 16: 647-651.

2. Ronald AD, Shamlal M (2004) The adrenal gland in Sternberg's Diagnostic Surgical Pathology, Vol 1. Fourth edition. Lippincott Williams and Wilkins, Philadelphia, USA : p 643.

3. Maclean TW, Iskander SS, Shimada H, Hall MC (2004) Neuroblastoma in an adult. *Urology* 64: 1232.

4. Franks LM, Bollen A, Seeger RC, Stram DO, Matthay KK (1997) Neuroblastoma in adults and adolescents: an indolent course with poor survival. *Cancer* 79: 2028-2035.

5. Kakodkar NC, Peddinti RR, Tian Y, Guerrero LJ, Chlenski A, et al. (2012) Sorafenib Inhibits Neuroblastoma Cell Proliferation and Signaling, Blocks Angiogenesis, and Impairs Tumor Growth. *Pediatr Blood Cancer* 59: 642-647.

6. Meitar D, Crawford SE, Rademaker AW, Cohn SL (1996) Tumor angiogenesis correlates with metastatic disease, N-myc amplification, and poor outcome in human neuroblastoma. *J Clin Oncol* 14: 405-414.

7. Eggert A, Ikegaki N, Kwiatkowski J, Zhao H, Brodeur GM, et al. (2000) High-level expression of angiogenic factors is associated with advanced tumor stage in human neuroblastomas. *Clin Cancer Res* 6:1900-1908.

8. Peddinti R, Zeine R, Luca D, Seshadri R, Chlenski A, et al. (2007) Prominent microvascular proliferation in clinically aggressive neuroblastoma. *Clin Cancer Res* 13: 3499-3506.

9. Ellis LM, Hicklin DJ (2008) VEGF-targeted therapy: Mechanisms of anti-tumour activity. *Nat Rev Cancer* 8: 579-591.

10. Chlenski A, Liu S, Cohn SL (2003) The regulation of angiogenesis in neuroblastoma. *Cancer Lett* 197: 47-52.

11. Keir ST, Maris JM, Lock R, Kolb EA, Gorlick R, et al. (2010) Initial testing (stage 1) of the multi-targeted kinase inhibitor sorafenib by the pediatric preclinical testing program. *Pediatr Blood Cancer* 55: 1126-1133.

12. Gagner M, Lacroix A, Bolte E (1992) Laparoscopic adrenalectomy in Cushing's syndrome and pheochromocytoma. *N Engl J Med* 327: 1033.

13. Haase GM, Perez C, Atkinson JB (1999) Current aspects of biology, risk assessment, and treatment of neuroblastoma. *Semin Surg Oncol* 16: 91-104.

14. de Barros F, Romão RL, de Pinho-Apezato ML, Prieto Velhote MC, Schilaich Ricardi LR, et al. (2012) Laparoscopic Adrenalectomy in Children for Neuroblastoma: Report of Case Series, *Surg Laparosc Endosc Percutan Tech* 22: 79-81.