

## Pilar Leiomyoma Located on the Back: A Case Report

Ayman Elgendy<sup>1\*</sup>, Eslam Alshawadfy<sup>2</sup> and Eman Ali<sup>2</sup>

<sup>1</sup>Department of Dermatology, Benha University, Egypt

<sup>2</sup>Department of Dermatology research, National Research Centre, Cairo, Egypt

\*Corresponding authors: Ayman Elgendy, Professor of Dermatology and Venereology, Benha University, Egypt, Tel: +966507364687; Email: aymanelgendy91@yahoo.com

Received date: Mar 07, 2015; Accepted date: May 05, 2015; Published date: May 07, 2015

Copyright: © 2015 Elgendy A, et al. This is an open-access article distributed under the terms of the Creative Commons Attribution License, which permits unrestricted use, distribution, and reproduction in any medium, provided the original author and source are credited.

### Abstract

Leiomyoma is a benign tumour commonly encountered in the genitourinary and gastrointestinal organs in adults. Cutaneous leiomyomas are rare benign tumors arising from the arrector pili muscle of hair follicles. Cutaneous leiomyomas are more likely to occur in adults than in children. We describe a case of a 30-year-old male who presented with skin-coloured masses on the back. A punch biopsy was performed. Under high-power examination, spindle cells with an eosinophilic cytoplasm were observed and immunohistochemical studies were performed; the cells stained strongly positive for smooth muscle actin (SMA). The patient was subsequently diagnosed with pilar leiomyoma and referred to a plastic surgeon for surgical treatment. A careful clinical assessment led to the correct diagnosis and therapy in the present case.

**Keywords:** Leiomyoma; Smooth muscle actin

### Introduction

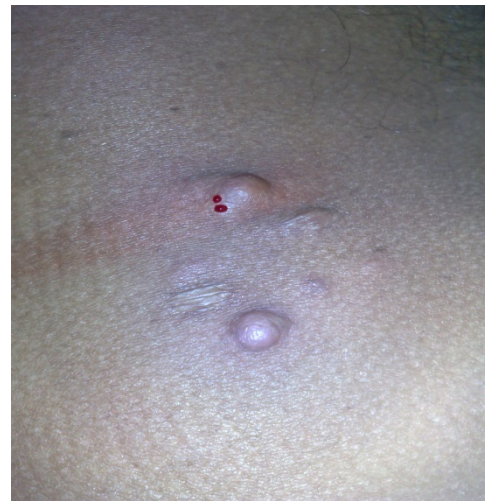Leiomyoma is a benign tumour commonly encountered in the genitourinary and gastrointestinal organs in adults. The skin is the second most common location for leiomyoma after the uterus, hosting ~5% of all leiomyomas [1].

Cutaneous leiomyomas are rare benign tumors arising from the arrector pili muscle of hair follicles, ranging in number from a few to several hundred [2,3]. Cutaneous leiomyomas are derived from smooth muscle in the skin. Piloleiomyomas, genital leiomyomas (dartoic), and angioleiomyomas are subtypes, each having distinct origins and clinicopathologic features [4,5]. Cutaneous leiomyomas are more likely to occur in adults than in children, and often arise in the fifth and sixth decades of life [6]. These lesions may be hereditary or sporadic [7].

### Case Report

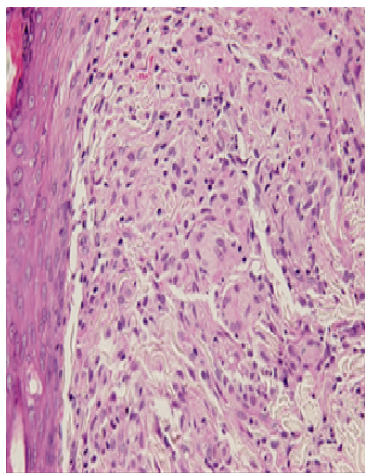
In the present study, we describe a case of a 30-year-old male with a two-month history of lesions in the lumbar region. During the second month, the mass was observed to have increased in size and become painful. The pain experienced may be spontaneous or as a result of exposure to cold, pressure or emotional stress. On clinical examination, skin-colored nodules were observed on the back of the patient, the largest of which measured ~10 × 15 mm and was located in the lumbar region (Figure 1).

Thorough clinical examination did not reveal any evidence of tumors located elsewhere or any pertinent past clinical history. No history of significant or hereditary diseases in the family was reported. A punch biopsy was performed by the clinician. Spindle cells with an eosinophilic cytoplasm were observed under high-power examination (Figure 2).

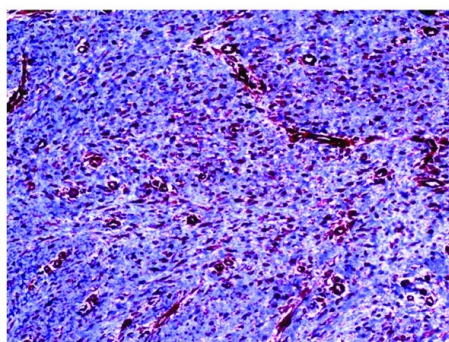


**Figure 1:** Skin-colored nodules on the back of the patient, (NB) blood drops due to injection of anesthesia.

Immunohistochemical studies were performed and the cells stained strongly positive for smooth muscle actin (SMA) (Figure 3). As a result, the patient was diagnosed with pilar leiomyoma.



**Figure 2:** Spindle cells with an eosinophilic cytoplasm (H&E).



**Figure 3:** Immunohistochemical staining (SMA).

## Discussion

Cutaneous leiomyomas can occur anywhere smooth muscle exists. Piloleiomyomas originate from the arrector pili muscles of the pilosebaceous unit, and may be either multiple or solitary [8]. Solitary variants develop during adulthood (with rare congenital/pediatric exceptions), whereas multiple leiomyomas occur typically from ages 10-30 years, with these distribution being unclear in either case. Ninety percent of piloleiomyomas are painful, described as burning, pinching, or stabbing; these sensations are usually secondary to cold, pressure, or emotion [8]. Although the exact cause of pain remains unknown, several reports propose impingement of the local nerve fibers after smooth muscle contraction to be causative [8].

Inherited leiomyomas are associated with various syndromes. Hereditary leiomyomatosis and renal cell cancer (HLRCC) is a rare disorder that manifests when Reed's syndrome is associated with renal cell cancer [9]. Most of the pathogenetic details of sporadic CLs are unknown; however, it is established that piloleiomyomas can originate from any of the attachment points of the arrector pili muscle, proximal to the hair follicle and distal to multiple attachment points within the papillary and reticular dermis and basement membrane zone [10].

Multiple leiomyomas, unlike solitary tumors, can be inherited in an autosomal-dominant fashion with variable penetrance [11].

It has been found that there were heterozygous germline mutations of the Krebs cycle enzyme, fumarate hydratase (FH), in patients with Reed's syndrome [12]. FH, a constituent enzyme of the Krebs or tricarboxylic acid (TCA) cycle, is known to exist in mitochondrial and cytosolic forms. FH, a constituent enzyme of the Krebs or tricarboxylic acid (TCA) cycle, is known to exist in mitochondrial and cytosolic forms. The mitochondrial variant catalyzes the conversion of fumarate to malate, and since 2002, has been considered a tumor suppressor [13].

If untreated, cutaneous leiomyomas continue to grow, with new lesions appearing over many years [14]. Surgical excision, with or without skin grafts, is the gold standard for cure [15]. Destructive methods such as electrodesiccation, cryotherapy, or carbon-dioxide laser may be employed for small lesions, but there is little known benefit over excision, and unwanted scarring may occur [16,17]. Leiomyoma associated pain can be managed medically with drugs known to affect smooth muscle contraction, such as nitroglycerine, nifedipine, phenoxybenzamine, and doxazosin; recent reports also suggest the use of calcium channel blockers, botulinum toxin type A injections, antidepressants, and triamcinolone acetonide injections [18,19]. For temperature-induced tenderness, gabapentin and topical analgesics, such as lidocaine or capsaicin, may be used [20,21].

## References

1. Yamato M, Nishimura G, Koguchi Y, Saotome K (1999) Calcified leiomyoma of deep soft tissue in a child. *Pediatr Radiol* 29: 135-137.
2. Martinez-Mir A, Gordon D, Horev L, Klapholz L, Ott J, et al. (2002) Multiple cutaneous and uterine leiomyomas: refinement of the genetic locus for multiple cutaneous and uterine leiomyomas on chromosome 1q42.3-43. *J Invest Dermatol* 118: 876-880.
3. Christenson LJ, Smith K, Arpey CJ (2000) Treatment of multiple cutaneous leiomyomas with CO<sub>2</sub> laser ablation. *Dermatol Surg* 26: 319-322.
4. Malhotra P, Walia H, Singh A, Ramesh V (2010) Leiomyoma cutis: a clinicopathological series of 37 cases. *Indian J Dermatol* 55: 337-341.
5. Badeloe S, van Geel M, van Steensel MA, Bastida J, Ferrando J, et al. (2006) Diffuse and segmental variants of cutaneous leiomyomatosis: novel mutations in the fumarate hydratase gene and review of the literature. *Exp Dermatol* 15: 735-741.
6. Robati RM, Barikbin B, Kavand S, Sarrafi-Rad N, Moradloo M (2009) Solitary cutaneous leiomyoma in an infant. *Pediatr Dermatol* 26: 621-623.
7. Fons ME, Bachhuber T, Plaza JA (2011) Cutaneous leiomyosarcoma originating in a symplastic pilar leiomyoma: a rare occurrence and potential diagnostic pitfall. *J Cutan Pathol* 38: 49-53.
8. Malik K, Patel P, Chen J, Khachemoune A (2015) Leiomyoma Cutis: A Focused Review on Presentation, Management, and Association with Malignancy. *Am J Clin Dermatol* 16: 35-46.
9. Launonen V, Vierimaa O, Kiuru M, Isola J, Roth S, et al. (2001) Inherited susceptibility to uterine leiomyomas and renal cell cancer. *Proc Natl Acad Sci USA* 98: 3387-3392.
10. Kudur MH (2013) A generalized multiple cutaneous piloleiomyomatosis in a young male: rare case report. *Indian J Dermatol* 58: 245.
11. Deveci U, Kapakli MS, Altintoprak F, Cayirci M, Manukyan MN et al. (2013) Bilateral nipple leiomyoma. *Case Rep Surg* 2013: 475215.
12. Tomlinson IP, Alam NA, Rowan AJ, Barclay E, Jaeger EE, et al. (2002) Germline mutations in FH predispose to dominantly inherited uterine fibroids, skin leiomyomata and papillary renal cell cancer. *Nat Genet* 30: 406-410.

13. Bayley JP, Launonen V, Tomlinson IP (2008) The FH mutation database: an online database of fumarate hydratase mutations involved in the MCUL (HLRCC) tumor syndrome and congenital fumarase deficiency. BMC Med Genet 9: 20.
14. Elbuluk N, Bichakjian CK, Lowe L (2011) What is your diagnosis? Multiple cutaneous and uterine leiomyomatosis (Reed Syndrome). Cutis 87: 65, 76-77.
15. Holst VA, Junkins-Hopkins JM, Elenitsas R (2002) Cutaneous smooth muscle neoplasms: clinical features, histologic findings, and treatment options. J Am Acad Dermatol 46: 477-490.
16. Montgomery H, Winkelmann RK (1959) Smooth-muscle tumors of the skin. AMA Arch Derm 79: 32-40.
17. Christenson LJ, Smith K, Arpey CJ (2000) Treatment of multiple cutaneous leiomyomas with CO<sub>2</sub> laser ablation. Dermatol Surg 26: 319-322.
18. Liu C, Tang ZH, Bei H, Zeng HY (2013) Treatment of a patient with multiple cutaneous piloleiomyoma-related pain with a local injection of triamcinolone acetonide. Dermatology 227: 52-54.
19. Hindley JT, Law PA, Hickey M, Smith SC, Lamping DL et al. (2002) Clinical outcomes following percutaneousmagnetic resonance image guided laser ablation of symptomatic uterine fibroids. Hum Reprod 17: 2737-2741.
20. Alam M, Rabinowitz AD, Engler DE (2002) Gabapentin treatment of multiple piloleiomyoma-related pain. J Am Acad Dermatol 46: S27-S9.
21. Batchelor RJ, Lyon CC, Highet AS (2004) Successful treatment of pain in two patients with cutaneous leiomyomata with the oral alpha-1 adrenoceptor antagonist, doxazosin. Br J Dermatol 150: 775-776.