

Piebaldism Associated with Neurofibromatosis Type I: A Case Report

Ayman Elgendy^{1*}, Eslam Alshawadfy^{2*}, Eman Ali^{2*} and Abdelaziz Altaweel^{1*}

¹Department of Dermatology, Benha University, Egypt

²Department of Dermatology research, National Research Centre, Cairo, Egypt

*Corresponding authors: Ayman Elgendy, Professor of Dermatology and Venereology, Benha University, Egypt, Tel: +966507364687; Email: aymanelgendy91@yahoo.com

Eslam Alshawadfy, Ass. Lecturer of Dermatology and Venereology (National Research Centre, Cairo, Egypt), MSc. Dermatology, MRCP (SCE Dermatology), European Board of Dermatology & Venereology (Frankfurt), Diploma in Dermatology (RCPSG) Glasgow. Tel: +201150177887; Email: eslamshawadfy@hotmail.com

Eman Ali, Ass. Lecturer of Dermatology and Venereology (National Research Centre, Cairo, Egypt), MSc. Dermatology, American Board of Aesthetic Medicine, Tel: +201005250969; Email: emansleem2977@hotmail.com

Abdelaziz Altaweel, Professor of Dermatology and Venereology, Benha University, Egypt, Tel: +201001633773; Email: a.eltaweel@hotmail.com

Received date: Mar 12, 2015, Accepted date: Mar 28, 2015, Published date: Mar 30, 2015

Copyright: © 2015 Elgendy A, et al. This is an open-access article distributed under the terms of the Creative Commons Attribution License, which permits unrestricted use, distribution, and reproduction in any medium, provided the original author and source are credited.

Abstract

Piebaldism is a rare disorder present at birth and inherited as an autosomal dominant trait. It results from a mutation in the c-kit proto-oncogene and is associated with a defect in the migration and differentiation of melanoblasts from the neural crest. We report a 15-year-old girl with both piebaldism and neurofibromatosis type 1 (NF1). She presented with a congenital depigmented patch of the forehead, as well as acquired white forelock, depigmentation of the medial eyebrows, and depigmented patches of the legs. In addition, some café au lait macules were observed at birth on the trunk and neck. To our knowledge, the association of piebaldism and NF1 has been described previously in at least 6 case reports. Awareness of this rare association is relevant to ensure early diagnosis and adequate follow-up for NF1.

Keywords: Piebaldism; Neurofibromatosis type I; c-Kit

Introduction

Piebaldism is a rare autosomal dominant disorder of melanocyte development characterized by congenital depigmented patches of skin and hair principally involving the forehead, central chest and abdomen, upper arms, and lower legs [1,2]. Most distinctive is a white forelock occurring in 80 ± 90% of piebald individuals. Neurofibromatosis type 1 (NF1) is a common autosomal dominant neurocutaneous disorder with variable clinical manifestations, including development of benign and malignant tumors at an increased frequency [3,4].

Despite significant progress in understanding the molecular bases of NF1, the diagnosis of this disease is still based on clinical criteria established by the National Institutes of Health (NIH) Consensus Conference in 1987 [4]. According to these criteria, two or more of the following findings must be present in order to establish the diagnosis of NF1: six or more café au lait spots (CALM) more than 15 mm after puberty, two or more neurofibromas or one plexiform neurofibroma, freckling in the axillary or inguinal regions, an optic pathway tumor, two or more Lisch nodules (iris hamartomas), a distinctive bone lesion such as sphenoid wing dysplasia, and a first-degree relative with NF1. We report the occurrence of piebaldism and NF1 in the same patient.

Case Report

The patient, a 15-year-old girl, is the first child of non-consanguineous parents. She presented with a congenital depigmented patch of the forehead, as well as acquired white forelock, depigmentation of the medial eyebrows, and depigmented patches of

the legs. In addition, some café au lait macules were observed at birth on the trunk and neck.

On examination, there was a depigmented patch on the midline forehead with adjacent white forelock and poliosis of the medial eyebrows. White patches were observed on the anterior of the midportion of her legs (Figures 1A and 1B).

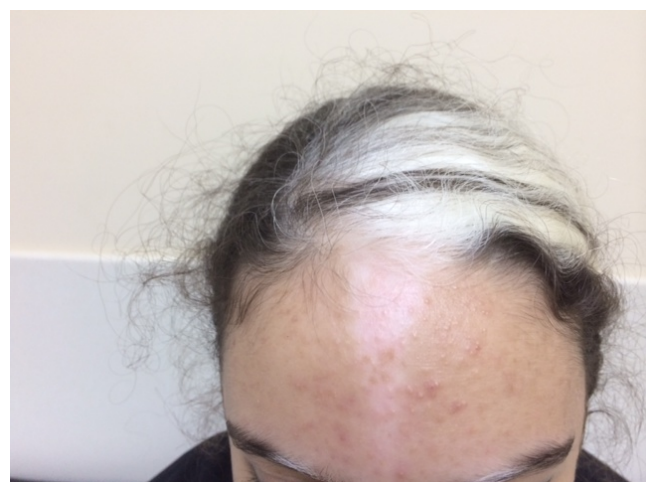

Figure 1A: A prominent, large depigmented patch on the central forehead associated with a white forelock and depigmentation of the hairs of the medial eyebrows and the eyelashes.

Numerous café au lait spots larger than 1.5 cm in diameter were scattered on the entire body. She also had numerous (CALM) on the trunk and extremities, 7 of which were larger than 15 mm and many over 5 mm in diameter (Figures 2A, 2B and 2C). There was bilateral axillary and inguinal freckling. No neurofibromas were detected. Ophthalmologic evaluation revealed Lisch nodules in the iris (Figure 3). There were iris heterochromia, or dystopia canthorum. Patient was otherwise healthy and her physical and mental development was normal. Her family history was significant in that both her mother and maternal grandfather were similarly affected with leukodermic patches. Based on the clinical features, a diagnosis of NF-1 and piebaldism was made.

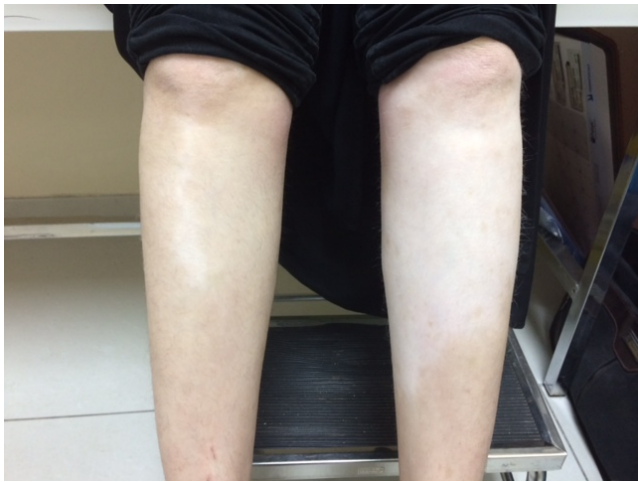


Figure 1B: White patches on the anterior of the portion of legs.

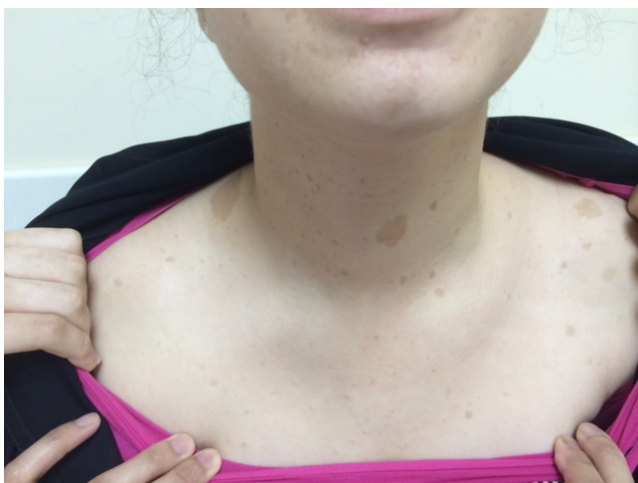

Figure 2A: Café au lait macules are seen on the chest and neck.

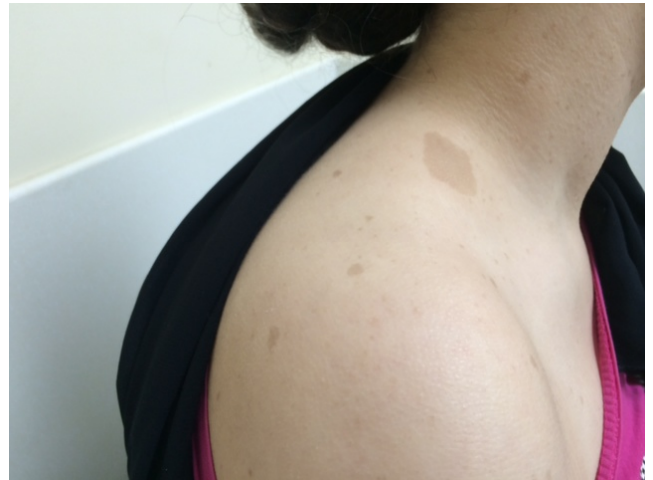

Figure 2B: Large café au lait macules on neck.

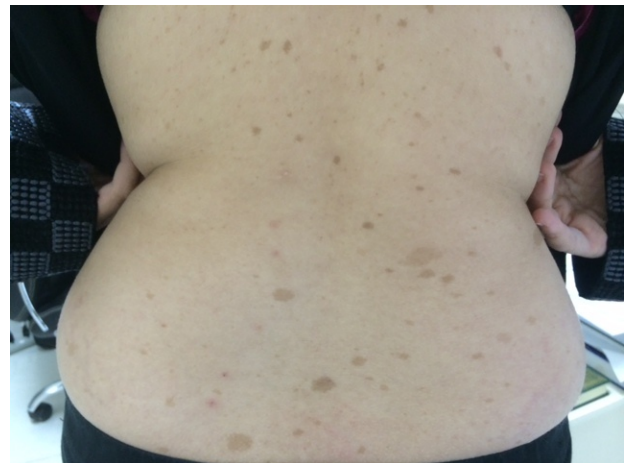

Figure 2C: Several café au lait macules are seen on the back.

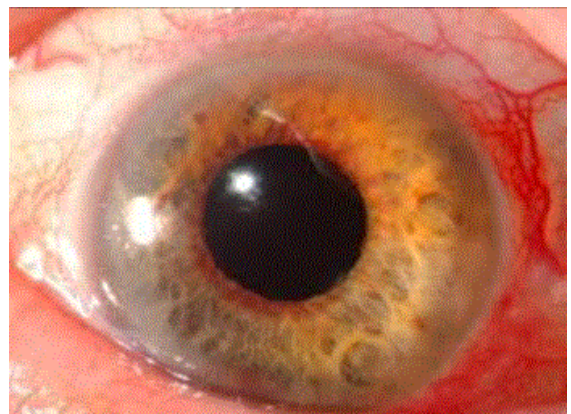


Figure 3: Lisch nodules in the iris.

Discussion

Piebaldism is usually a benign isolated skin condition, but there are rare reports of piebaldism association with Hirschprung disease, mental retardation, NF1, congenital dyserythropoietic anemia type II, Diamond-Blackfan anemia, Grover disease, deafness, and cerebellar ataxia [5]. Review of the literature revealed six reports, all in the dermatology literature, of 9 patients who were said to have both piebaldism and NF1 (Chang et al., 1993; Tay, 1998; Angelo et al., 2001; Duarte et al., 2010, Stevens et al., 2012 and Yvonne et al., 2013) in addition to our case report [6-11].

As in our case, the girl described by Tay [7] also had Lisch nodules, while the first two patients reported by Chang et al. [6] had café au lait spots and axillary freckling as diagnostic features of NF1. Of interest, none of these patients or their relatives had neurofibromas.

Whether, the simultaneous occurrence of these two dominantly inherited diseases is significantly higher than by chance remains to be established. Both are autosomal dominant conditions, but the genes for them have been localized to different chromosomes: the NF-1 gene, a tumor suppressor gene, has been localized to chromosome 17q 11.2 [12]. Mutations of the c-KIT gene which has been mapped to chromosome 4q12 have been identified in piebaldism [13].

Piebaldism is caused by an autosomal dominant mutation in the *KIT* proto-oncogene [14]. The KIT protein product is a receptor tyrosine kinase that activates several intracellular signaling pathways. Legius syndrome is characterized by multiple CALMs and axillary or inguinal freckling, without other features of NF1 such as neurofibromas, Lisch nodules, and central nervous system tumors [15]. Autosomal dominant loss-of-function mutations in *SPRED1*, resulting in induction of the Ras/MAP kinase pathway, is the cause of Legius syndrome [8].

Phosphorylation of SPRED1 by kinases such as KIT is required for activation and efficient suppression of the Ras/MAP kinase pathway [6,15]. It has been suggested that loss of SPRED1 function due to inadequate phosphorylation by KIT is the cause for the CALMs and freckling seen in some patients of piebaldism. It has been suggested that multiple CALMs and intertriginous freckling can be seen within the piebaldism spectrum of disease and that loss of function of SPRED1 due to inadequate phosphorylation of the KIT-binding domain by KIT is the cause of the hyperpigmented lesions seen in some individuals with piebaldism [11]. Based on current understanding of KIT and SPRED1 protein interactions, it is proposed that café au lait macules and freckling may be seen in some patients with piebaldism and does not necessarily represent coexistence of neurofibromatosis type 1 [11].

The presence of Lisch nodules in our case confirmed the diagnosis of neurofibromatosis, but we mentioned Legius syndrome as an example which may explain the possible mechanism which links the association between CALMs of our case with piebaldism. This case report and the others could also be used to demonstrate the different clinical manifestation and phenotypic severity of piebaldism.

Acknowledgment

Special thanks go to Ahmed Mahmoud Emad Elsaïdi, a third year medical student at Ainshams University, Cairo, Egypt for his valuable contribution in this research by helping in collecting data and gathering images for this case report.

References

1. Orlow SJ (1995) Congenital disorders of hypopigmentation. *Semin Dermatol* 14: 27-32.
2. Spritz RA (1997) Piebaldism, Waardenburg syndrome, and related disorders of melanocyte development. *Semin Cutan Med Surg* 16: 15-23.
3. Rasmussen SA, Friedman JM (2000) NF1 gene and neurofibromatosis 1. *Am J Epidemiol* 151: 33-40.
4. [No authors listed] (1988) Neurofibromatosis. Conference statement. National Institutes of Health Consensus Development Conference. *Arch Neurol* 45: 575-578.
5. Thomas I, Kihiczak GG, Fox MD, Janniger CK, Schwartz RA (2004) Piebaldism: an update. *Int J Dermatol* 43: 716-719.
6. Chang T, McGrae JD Jr, Hashimoto K (1993) Ultrastructural study of two patients with both piebaldism and neurofibromatosis 1. *Pediatr Dermatol* 10: 224-234.
7. Tay YK (1998) Neurofibromatosis 1 and piebaldism: a case report. *Dermatology* 197: 401-402.
8. Angelo C, Cianchini G, Grosso MG, Zambruno G, Cavalieri R, et al. (2001) Association of piebaldism and neurofibromatosis type 1 in a girl. *Pediatr Dermatol* 18: 490-493.
9. Duarte AF, Mota A, Baudrier T, Morais P, Santos A, et al. (2010) Piebaldism and neurofibromatosis type 1: family report. *Dermatol Online J* 16: 11.
10. Stevens CA, Chiang PW, Messiaen LM (2012) Café-au-lait macules and intertriginous freckling in piebaldism: clinical overlap with neurofibromatosis type 1 and Legius syndrome. *Am J Med Genet A* 158A: 1195-1199.
11. Chiu YE, Dugan S, Basel D, Siegel DH (2013) Association of Piebaldism, Multiple Café au lait Macules, and Intertriginous Freckling: Clinical Evidence of a Common Pathway between KIT and Sprouty Related, Ena/ Vasodilator-Stimulated Phosphoprotein Homology-1 Domain Containing Protein 1 (SPRED1) *Pediatr Dermatol* 30: 379-382.
12. Ledbetter DH, Rich DC, O'Connell P, Leppert M, Carey JC (1989) Precise localization of NF-1 to 17q11.2 by balanced translocation. *Am J Hum Genet* 44: 20-24.
13. Morrison-Graham K, Takahasyi Y (1993) Steel factor and c-Kit receptor: From mutants to a growth factor system. *Bioessays* 15: 77-83.
14. Kato R, Nonami A, Taketomi T, Wakioka T, Kuroiwa A, et al. (2003) Molecular cloning of mammalian Spred-3 which suppresses tyrosine kinase-mediated Erk activation. *Biochem Biophys Res Commun* 302: 767-772.
15. Wakioka T, Sasaki A, Kato R, Shouda T, Matsumoto A, et al. (2001) Spred is a Sprouty-related suppressor of Ras signalling. *Nature*. 412:647-651.