

## Pheochromocytoma Presents as Takotsubo Cardiomyopathy

Alsaffar YR\* and Ho K

Department of Endocrinology, Faculty of Medicine and Health Sciences, Macquarie University, New South Wales, Australia

\*Corresponding author: Yasameen Riyadh Alsaffar, M.B.CH.B, F.I.B.M.S, Department of Endocrinology, Faculty of Medicine and Health Sciences, Macquarie University, New South Wales, Australia, Tel: +61422983092; E-mail: [dr.yassamin@gmail.com](mailto:dr.yassamin@gmail.com)

Received date: July 09, 2016; Accepted date: October 05, 2016; Published date: October 10, 2016

Copyright: © 2016 Alsaffar YR, et al. This is an open-access article distributed under the terms of the Creative Commons Attribution License, which permits unrestricted use, distribution, and reproduction in any medium, provided the original author and source are credited.

### Abstract

A hypertensive crisis, with an acute heart failure and pulmonary oedema had complicated anesthesia induction, during an elective surgery was done to an elderly aged patient. This patient had hypertension, with a very controlled BP on Irbesartan (angiotensin receptor blocker), and a normal cardiac function before admission. The operation was aborted, and the patient was resuscitated in the theatre and the ICU. Investigations showed cardiomegaly on CXR, with abnormal size and function of the Lt Ventricle on echocardiograph, as well as high levels of serum troponin, and very high values of serum catecholamine's metabolites (metanephrines and normetanephrines). A high suspicion of pheochromocytoma was raised, and this was confirmed later by the presence of a large RT adrenal mass on abdominal CT scan and MIBG scan. After 3 weeks of supportive treatment in the ICU, with continuous monitoring of the very labile BP, the patient underwent a laparoscopic adrenalectomy. Postoperatively, the patient's BP and cardiac function were restored

**Keywords:** Pheochromocytoma; Takotsubo cardiomyopathy

### Background

Pheochromocytomas are rare catecholamine-secreting tumours that arise from the adrenal medulla. They could arise from extra-adrenal sites, and in this case, they called paraganglioma. Pheochromocytomas are usually benign tumours, with 10% risk of malignancy [1]. They usually present themselves in the features of catecholamine excess, such as a headache, perspiration, anxiety, palpitation, and malignant hypertension [2]. Nevertheless, pheochromocytomas can present as life-threatening events, such as Takotsubo cardiomyopathy, acute myocardial infarction, acute pulmonary oedema, acute renal failure, strokes, acute ischemic ileus, and multiorgan failure. These life-threatening events are related directly to the tumour size, as well as to the catecholamine levels [2].

Takotsubo cardiomyopathy is a reversible form of heart failure; it has many names like broken heart syndrome, acute left ventricular apical ballooning syndrome, and acute cardiac sympathetic disruption syndrome [3]. It is characterized by chest pain, non-specific ST/T wave changes on the ECG, transient LT ventricular regional wall motion abnormality with ballooning of the apical segment, and features of pulmonary oedema. These manifestations are due to catecholamine excess, and could not be attributed to coronary arteries insufficiency [4].

### Case Presentation

A 77 year old graphic artist lady with a 10 year history of hypertension, her BP was controlled by ARB (angiotensin receptor blocker, irbesartan tablet 300 mg). She has hypothyroidism due to subtotal thyroidectomy, and she is on thyroxin tablets 100 microgram. The patient has no family history of any disease, she has two sons; with a number of grandson's, all of whom are healthy. The patient denies chest pain, palpitation, headache, flushing or postural symptoms. Recently, the patient has had an unsteady gait, with multiple falls, for

which she went to her GP who sent her for a brain MRI that showed a vascular aneurysm plus hydrocephalus. She was arranged for a VPS surgery (ventriculoperitoneal shunt). During the surgery, the patient developed a hypertensive crisis, with SBP>300 mmHg, tachycardia and pulmonary oedema (Figures 1,2).

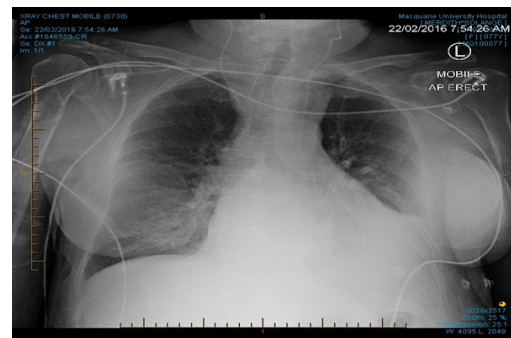


Figure 1: Chest X-ray.

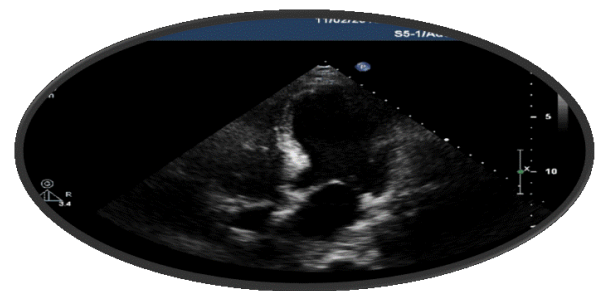


Figure 2: Scan report.

## Work up

Her ECG showed non-specific ST/T waves changes, with runs of atrial fibrillation (AF). Her serum troponin came back very high. Her echocardiography showed LT ventricular dilatation and ballooning, highly suggestive of Takotsubo cardiomyopathy. The patient had a brain, chest, and abdominal CT scans as part of malignant hypertension work up. The abdominal CT scan showed: a large RT adrenal mass 6.7 cm, with multiple hepatic cysts. Also, there was a large retrosternal goitre (TFT did not suggest thyrotoxic crisis). The clinical suspicion of pheochromocytoma has risen, and the patient was sent for serum and urinary catecholamine metabolites (metanephrine and normetanephrine). Magnesium sulphate and sodium nitroprusside infusions were initiated to control her BP. Alpha blocker; phenoxybenzamine in increasing doses was given to her, as well as B-blockers to control her tachycardia. IV fluid support and liberal salts intake were included in her management (Figure 3). Non-contrast CT scan is preferred over contrasts enhanced CT scan, as IV contrast can precipitate a hypertensive crisis. CT scan shows homogeneous solid mass measures >10 HU, with scattered areas of necrosis.

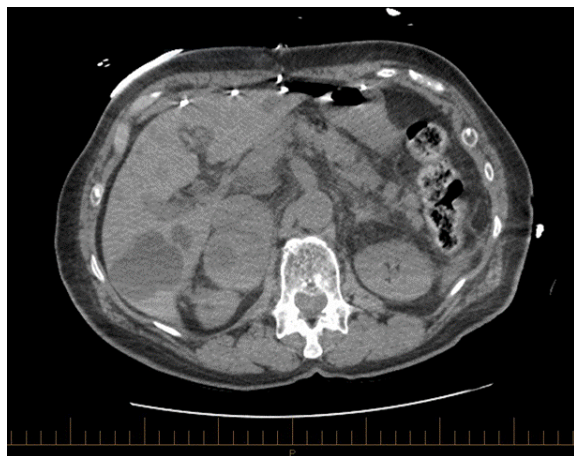


Figure 3: Non contrast CT scan.

## Subsequent management

After ten days of support in the ICU, plasma catecholamine metabolite results came back very high; plasma metanephrines 14.90 nmol/L (normal<0.40), and plasma nor\_ metanephrines 17.80 nm/L (normal<0.90), these results have increased the probability of pheochromocytoma. The next step was to localise the tumour, and to rule out metastasis by doing MIBG, and to prepare the patient for laparoscopic adrenalectomy (Figure 4).

## Perioperative management

The patient's BP was controlled with increasing doses of phenoxybenzamine (alpha blocker) 60 mg TDS. Propranolol( B-blockers) 40 mg TDS had been used to control her heart rate. Difficult to control blood pressure was controlled with Sodium Nitroprusside 1 mg/h continued throughout ICU admission. Prazosin 1 mg QID was added before the operation.

Intraoperatively, the patient's BP was supported with IV fluid and inotropic. A laparoscopic adrenalectomy had been done (Figures 5-7).

## I 123 MIBG scan

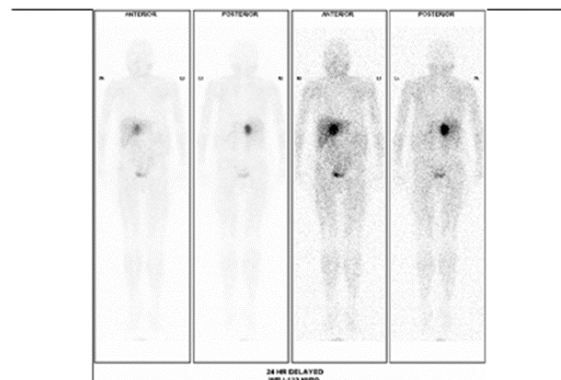


Figure 4: MIBG scan.

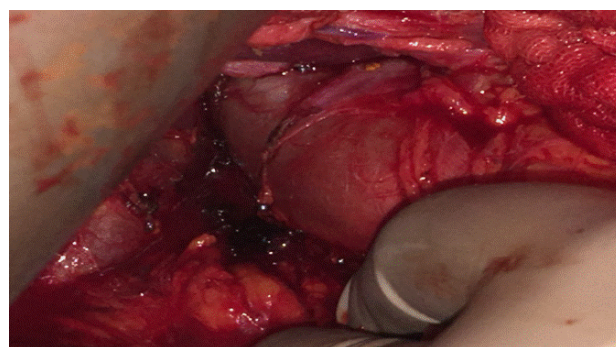


Figure 5: Laparoscopic adrenalectomy.

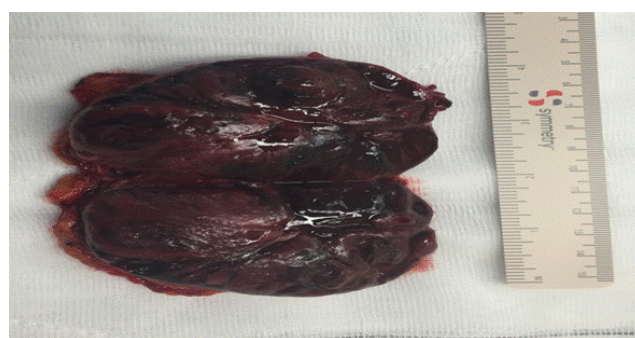
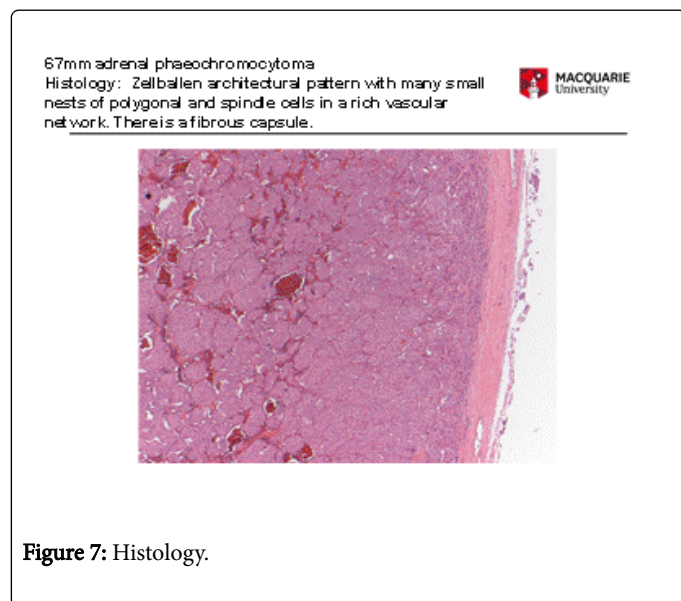


Figure 6: Size of tumour.

## Postoperative and follow-up

The patient had an uneventful recovery; her BP was controlled with calcium channel blockers only. Her ECG returned to sinus rhythm, and her echocardiography showed restoration of the Left ventricular size and function. Her serum metanephrine and normetanephrine returned to normal values at 0.17 and 0.55 respectively. The tumour

had been sent for genetic testing for MEN syndrome, and VHL syndrome and the results came back negative.



## Discussion

Pheochromocytomas are rare tumours arise from catecholamines secreting cells in the adrenal medulla. They frequently manifest themselves in the features of catecholamines excess, such as a headache, perspiration, palpitation, or anxiety. However, in our case, pheochromocytoma presents itself in an acute heart failure as takotsubo cardiomyopathy.

There are few case reports of pheochromocytomas that have been presented as takotsubo cardiomyopathy. One of these cases was a healthy 46-year-old female patient with pheochromocytoma, who was in shock due to cardiac arrest. She was successfully treated with extracorporeal membrane oxygenation (ECMO) as a bridge to pharmacological therapy and curative adrenalectomy [5].

Another case report that mentioned the relationship between pheochromocytoma and Takotsubo cardiomyopathy, is a 16-year-old boy, who had Takotsubo cardiomyopathy, and a large RT adrenal mass that had been diagnosed later. Open adrenalectomy was done to him, and the histopathology proved that it was a pheochromocytoma. The patient had an excellent recovery and remained normotensive [6].

Finally, a middle-aged male who was completely asymptomatic, underwent an elective surgery (just like our patient). He had spinal

anaesthesia to remove a 1<sup>st</sup> metatarsal osteophyte in the outpatient setting. In the recovery room, he developed high BP, sinus tachycardia, acute pulmonary oedema which required intubation and mechanical ventilation. His Chest CT scan showed a large Para-aortic mass, with high serum and urinary catecholamine metabolites, and MIBG features of paraganglioma. The patient had supportive treatments to control his situation, and eventually treated with surgical resection of the tumour, and he had a very good recovery with normal BP and cardiac function [6].

## Conclusion and Take Home Messages

Pheochromocytomas are rare tumours of the adrenal medulla, and could be extra-adrenal (paraganglioma). These are benign, but could be malignant in 10% of cases. They had benign manifestations, such as a headache, sweating, palpitation, but could be presented as life-threatening events. Acute illnesses and induction of anaesthesia are among the most important precipitating factors to the acute crises caused by pheochromocytoma. Takotsubo cardiomyopathy is an acute, reversible heart failure, occurs due to a surge in catecholamine levels, such as bad news, acute events, or pheochromocytomas. A high degree of suspicion needs to be considered when facing patients without heart problems and has acute heart failure in the setting of high catecholamine levels, and in the absence of coronary arteries insufficiency.

## References

1. Eisenhofer G, Pacak K, Maher ER, Young WF, de Krijger RR (2013) Pheochromocytoma. *Clin Chem* 59: 466-472.
2. Riester A, Weismann D, Quinkler M, Lichtenauer UD, Sommerey S, et al. (2015) Life-threatening events in patients with pheochromocytoma. *Eur J Endocrinol* 173: 757-764.
3. Zhu D, Yu J, Li X, Jiang X, Zhuang C (2014) Takotsubo-like cardiomyopathy in a giant pheochromocytoma. *Int J Cardiol* 176: e113-e116.
4. Demirçelik MB, Aydın H (2013) Tako-tsubo-like cardiomyopathy induced by pheochromocytoma crisis. *Anadolu Kardiyol Derg* 13: E35-E36.
5. Flam B, Broome M, Frenckner B, Branstrom R, Bell M (2015) Pheochromocytoma-Induced Inverted Takotsubo-Like Cardiomyopathy Leading to Cardiogenic Shock Successfully Treated With Extracorporeal Membrane Oxygenation. *J Intensive Care Med* 30: 365-372.
6. Sharkey SW, McAllister N, Dassenko D, Lin D, Han K, et al. (2015) Evidence That High Catecholamine Levels Produced by Pheochromocytoma May be Responsible for Tako-Tsubo Cardiomyopathy. *Am J Cardiol* 115: 1615-1618.