

Phenotypic Analyses of T, B, NK and NKT Cells in a Human Fetus with D and C Alloimmune Anemia

Juliana Araujo de Carvalho Schettini*, Isabela Cristina Coutinho de Albuquerque Neiva Coelho, Melania Maria Ramos de Amorim and Leuridan Cavalcante Torres

Instituto de Medicina Integral Professor Fernando Figueira, Brazil

Abstract

Fetal hypoxxygenation due to the anemia may be an important factor in stimulating the maturation processes of the immune system in the fetus, determining the switch from fetal to adult form. We performed an immunological evaluation in a fetus in the 29th week of gestation with secondary hypoxemia and RhD and C alloimmune anemia. We found normal relative values for total T, TCD4+ and TCD8+, and low levels of B memory and NK cells. NKT cells were absent. There IL-8 serum levels were higher than those of the mother. Fetal anemia was not capable of activating the humoral immune response and differentiation of memory B cells. Our data suggest that NKT cell differentiation may be related to thymus development in humans.

Keywords: Anemia; Fetus; Cytokines; Immunophenotyping; Cordocentesis

Abbreviations

IL-12p70: Interleukin 12; TNF- α : Tumor Necrosis Factor alpha; IL-1 β : Interleukin 1 beta; IL-6: Interleukin 6; IL-8: Interleukin 8; IL-10: Interleukin 10

Introduction

The thymus plays a crucial role in adaptive immunity and the development, proliferation, and differentiation of mature T cells, with the size of the thymus being a predictor of immune function [1,2]. In humans, by week 15–16 of gestation, the architecture of the fetal thymus resembles that of the neonate [3]. T-cell precursors are therefore present in the thymus and susceptible to late gestational injury, making this organ a potential target for prenatal stress-induced changes. It is currently accepted that the neonates have a phenotypically and functionally immature immune system [4], but little is known about the percentile of T, B, NK and NKT cells in the fetus during human gestation because of the difficulty of obtaining samples and ethical issues. In the present study, we performed an immunological evaluation of a fetus with secondary hypoxemia and D and C alloimmune anemia. The fetal hypoxxygenation caused by the anemia may be an important factor in stimulating the maturation processes of the immune system in the fetus, determining the switch from fetal to adult form.

Methods

The study was carried out at the Fetal Medicine Unit of the Department of Obstetrics and Gynecology and the Translational Research Laboratory of the IMIP. The established clinical and laboratory protocols were carried out and the study was approved by the IMIP's Research Ethics Committee. The pregnant women gave written informed consent.

Case report

Mother: A 32 year old woman, blood group A RhD negative, multigravida (Gesta 4 to 3), 3 prior cesareans, in the second trimester, with a history of two stillbirths and a positive indirect Coombs test of 1/2048 was referred to the Instituto de Medicina Integral Prof. Fernando Figueira (IMIP), Recife, Brazil. The first birth, nine years previously at term, had been of a blood group A RhD positive baby weighing 3200 g with neonatal jaundice who underwent phototherapy. The mother had not received anti-D immunoglobulin treatment during

or after pregnancy. The second and third pregnancies were stillbirths with hydropsy. D and C red cell antibodies (RCA) were detected in the mother's serum by antigen-antibody reaction.

Fetus: In this pregnancy, the fetus with RhD and C alloimmunization had an abnormal middle cerebral artery peak systolic velocity (MCA-PSV) for gestational age and was studied by way of a single fetal blood sample obtained by ultrasound-guided cordocentesis in the 29th week of gestation (Figure 1). Fetal transfusion was necessary (fetal Hb 4.7 g/dL; hematocrits 13.7%) and the antigen expression of the lymphocyte subpopulations was assessed in the fetal blood sample taken prior to transfusion. The blood-transfused preparation consists only of O RhD and C negative packed red blood cells for the correction of the anemia. The fetus had ascites, hepatomegaly, pericardial effusion and polyhydramnios and no signs of hydropsy or other malformations were detected by ultrasound. The gestational age was determined on the basis of ultrasound examinations performed in the first trimester of pregnancy.

a. Current Clinical evaluation: The cesarean birth was performed in the 34th week of gestation after two intra-uterine transfusions; the baby is alive and has received some transfusions.

Immunophenotyping of T, B, NK and NKT cells: Six-color flow cytometric immunophenotyping of peripheral blood was performed using FACSVERSE (BD Biosciences). The following monoclonal antibodies were used: anti-CD3, anti-CD4, anti-CD8, anti-CD19, anti-CD16, anti-CD56, anti-CD27 and anti-CD161 (BD Biosciences, CA). The cells were analyzed using the most appropriate lymphocyte gate with a combination of forward and side scatters and the data obtained were processed using FACSSuite software (BD Biosciences).

***Corresponding author:** Juliana Araujo de Carvalho Schettini, MD, PhD student, Instituto de Medicina Integral Professor Fernando Figueira, Recife, Pernambuco Brazil, Tel: +55 81 2122-4702; Fax +55 81 2122-4703; E-mail: julianaschettini@yahoo.com.br

Received August 08, 2014; **Accepted** October 28, 2014; **Published** November 04, 2014

Citation: Schettini JAC, Coelho ICCAN, Amorim MMR, Torres LC (2014) Phenotypic Analyses of T, B, NK and NKT Cells in a Human Fetus with D and C Alloimmune Anemia. Transl Med 4: 140. doi: [10.4172/2161-1025.1000140](https://doi.org/10.4172/2161-1025.1000140)

Copyright: © 2014 Schettini JAC, et al. This is an open-access article distributed under the terms of the Creative Commons Attribution License, which permits unrestricted use, distribution, and reproduction in any medium, provided the original author and source are credited

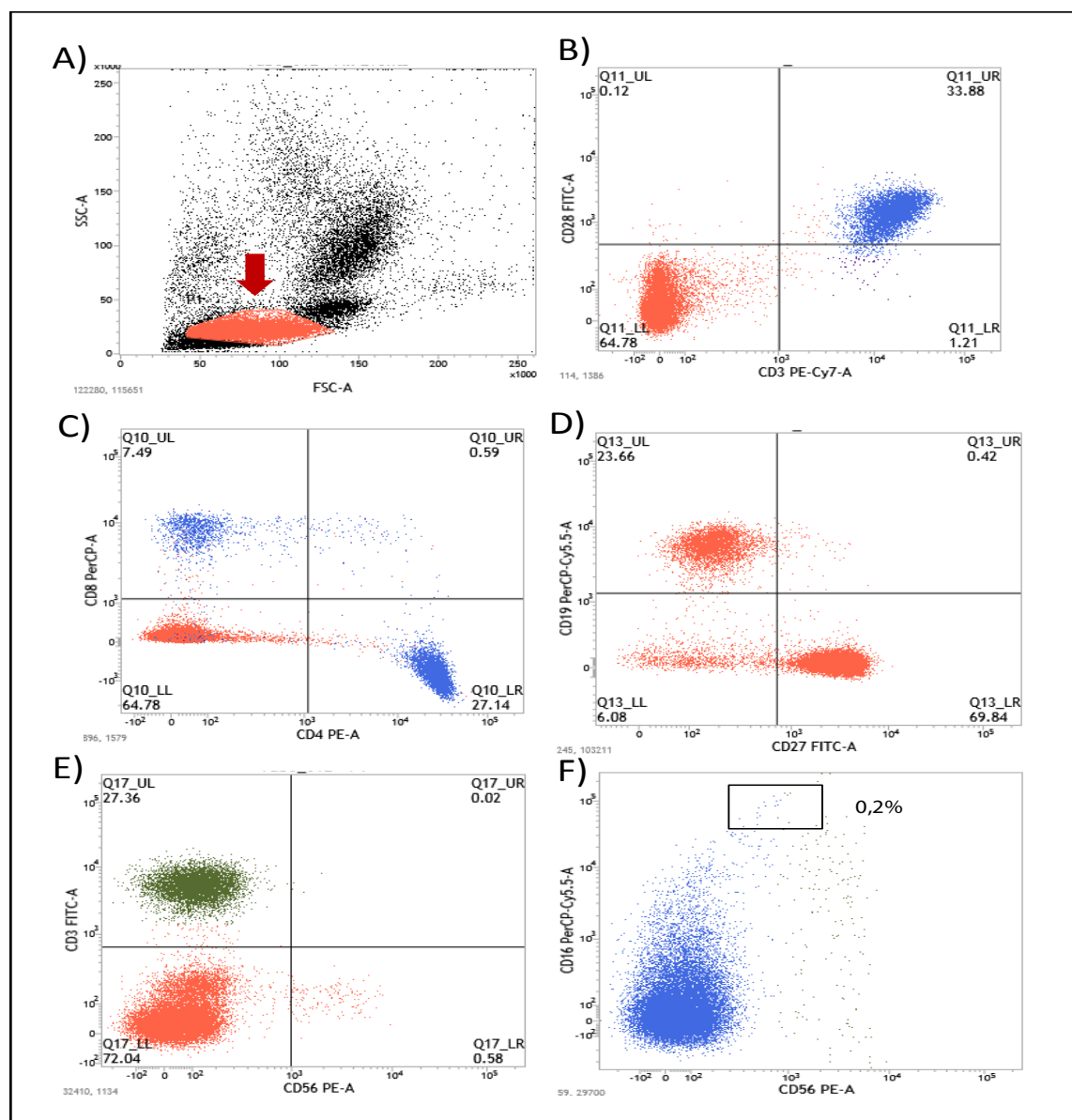


Figure 1: Immunophenotyping analyses of the fetus in the 29th week: A) Lymphocyte gate, B) T cell CD28⁺ CD3⁺, C) TCD4⁺ and TCD8⁺, D) B cell (CD19⁺) and B memory (CD19⁺/CD27⁺), E) NKT cells (CD3⁺/CD56⁺), F) NK cells (CD16⁺/CD56⁺/CD3⁺/CD34⁻).

Proinflammatory cytokines: Proinflammatory cytokines (IL-12p70, TNF- α , IL-10, IL-6, IL-1 β and IL-8) were examined using an inflammatory BD CBA kit (BD Pharmingen). Samples were analyzed by flow cytometry on a BD FACSVERSE (Becton Dickinson, CA).

Results and Discussion

In the present study the fetus had severe anemia Hg 4.7 g/dl prior to the first transfusion. Levels of fetal hemoglobin (Hb) increased gradually during the gestation with short-term high levels. By the 10th week of pregnancy, the average concentration of Hb in the fetus was 9 mg/dL, by around 22 to 24 weeks, had reached levels of 14–15 mg/dL and, at the midpoint and at the end of the third trimester, was around 16.6 g/dL [5].

We believed that the presence of one or more maternal antibodies may suggest worse anemia and more IUT's but some studies have

shown that the presence of anti-D appears to be the most significant factor guiding the course of isoimmunization with multiple antibodies [6]. In RhD sensitized women, the presence of additional antibodies did not influence the degree of fetal anemia or the first transfusion-delivery interval, although rates of fetal hydropsy were higher in the presence of multiple antibodies [7]. Hemolytic disease secondary to maternal Rhesus (RhD) alloimmunization is still a common cause of fetal anemia, despite the existence of effective prophylaxis owing to the use of anti-RhD immunoglobulin [8]. Approximately 10% of alloimmunised women have a child affected in the uterus by severe hemolytic anemia. These pregnancies therefore require proper monitoring with ultrasonography and evaluation of the middle cerebral artery peak systolic velocity (MCA-PSV), which is considered the gold standard for noninvasive diagnosis of fetal anemia [9], and is effective for identification of the correct time for treatment to prevent fetal hydropsy [9,10].

Immunologic evaluation of the fetus revealed normal relative values for total TCD3⁺/CD28⁺ (33.88%), TCD8⁺ (7.49%), TCD4⁺ (27.14%), TCD4⁺CD8⁺ (0.59%) and TCD4⁺CD8⁺ (64.7%) cells, compared to phenotype analyses of T lymphocytes in healthy fetuses, as described by Zhao et al. [11]. Relative levels of B cells were normal (CD19⁺/CD3⁺: 23.6%) compared to those of healthy neonates [12]. Some authors, however, have reported increased percentages of T cells, TCD4⁺ and TCD8⁺ lymphocytes in eight fetuses with RhD alloimmunization [13]. On the other hand, there were low relative levels of B memory (CD19⁺/CD27⁺: 0.4%) and NK cells (CD3⁺/CD16⁺Bright/CD56⁺dim: 0.02%). NKT cells (CD3⁺/CD161⁺/CD56⁺) were absent (Figure 1).

In the human fetus, most lymphocyte development occurs in the liver for B and T cells. After birth, T cells also originate from the bone marrow but all the important events in their development, especially changes in cell surface molecules, occur in the thymus. The generation of the lineage of T cells occurs in the thymus through a series of orchestrated developmental events that result in a carefully selected population of TCD4⁺ or TCD8⁺ lineage and require approximately three weeks of post-thymus maturation before transitioning into the mature T cell compartment [14]. The B cells develop in the bone marrow with the help of stromal cells and achieve maturity in peripheral lymphoid organs [15]. In intrauterine life, the lymphocyte count increases linearly with pregnancy weeks [13]. At 17 weeks the lymphocyte count reaches 50% of the total at term [16]. On the other hand, the neutrophil count remains very low up to 32 weeks, but then increases exponentially, the neutrophil being the most common white blood cell at term [13]. It may be that the thymus is essential for the development of NK and NKT cells and alloimmunization is not capable of stimulating the cellular and humoral immune response in the fetus.

Examination of proinflammatory cytokines revealed heightened serum levels of IL-8, IL1 β and IL-6 (17 and 2.4 and 2.7 pg/mL, respectively) in the fetus compared to the mother (of 4.6 and 1.8 and 0.2 pg/mL, respectively). There were no detectable serum levels of IL12p70, TNF- α and IL10.

One study using blood samples from fetuses of mothers sensitized only to the RhD antigen demonstrated that the fetus is capable of mounting an inflammatory response to a non-infectious insult, namely anemia [17]. An elevated IL-6 concentration has been found in fetuses with fetal anemia, while none of the fetuses without proven anemia had such an increase. Moreover, there was a negative correlation between fetal hematocrit count and IL-6 concentrations. It is conceivable that the fetal anemia-associated increase in IL-6 concentration in fetal circulation is a consequence of "tissue damage" (i.e., destruction of antibody-coated red blood cells in the reticulo-endothelial system and/or tissue hypoxia) rather than the cause. The main limitation of this study was the relatively small number of cases with and without fetal anemia.

Conclusion

Patients at risk of fetal anemia should be referred to fetal referral care centers if abnormal MCA-PSV is detected. Even in developed countries, fetal anemia continues to be a substantial antenatal problem because of the inadequate use of anti-Rh immunoglobulin, the presence of other immunizing antigens (C, c, Kell, Kidd and others) for which there is as yet no effective immunoprophylaxis, and other causes of anemia, such as feto-fetal transfusion, infections and feto-maternal hemorrhages.

The present study found no change in the relative levels of TCD4⁺ and TCD8⁺ in the fetus with anemia. Fetal anemia was not capable

of activating the humoral immune response and differentiation of memory B cells. Our data suggest that NKT cell differentiation may be related to thymus development in humans.

Acknowledgments

The authors would like to thank the National Council for Scientific and Technological Development (CNPQ number 473426/2011-6) and FAPESP/IMIP for financial support and the pregnant women.

References

1. Cromi A, Ghezzi F, Raffaelli R, Bergamini V, Siesto G, et al. (2009) Ultrasonographic measurement of thymus size in IUGR fetuses: a marker of the fetal immunoendocrine response to malnutrition. *Ultrasound Obstet Gynecol* 33: 421-426.
2. Hartge R, Jenkins DM, Kohler HG (1978) Low thymic weight in small-for-dates babies. *Eur J Obstet Gynecol Reprod Biol* 8: 153-155.
3. Klein J, Horstjens J (1997) Immunology. Oxford: Blackwell Science.
4. Thilaganathan B1, Mansur CA, Morgan G, Nicolaides KH (1992) Fetal T-lymphocyte subpopulations in normal pregnancies. *Fetal Diagn Ther* 7: 53-61.
5. Walker J, Turnbull EP (1953) Haemoglobin and red cells in the human foetus and their relation to the oxygen content of the blood in the vessels of the umbilical cord. *Lancet* 265: 312-318.
6. Spong CY, Porter AE, Queenan JT (2001) Management of isoimmunization in the presence of multiple maternal antibodies. *Am J Obstet Gynecol* 185: 481-484.
7. Walsh CA, Russell N, McAuliffe FM, Higgins S, Mahony R, et al. (2013) Relationship between maternal antibody type and antenatal course following intrauterine transfusion for red cell alloimmunisation. *Eur J Obstet Gynecol Reprod Biol* 171:235-239.
8. Moise KJ (2005) Red blood cell alloimmunization in pregnancy. *Semin Hematol* 42: 169-178.
9. Pretlove SJ1, Fox CE, Khan KS, Kilby MD (2009) Noninvasive methods of detecting fetal anaemia: a systematic review and meta-analysis. *BJOG* 116: 1558-1567.
10. Bricca P, Guinchard E, Guitton Bliem C (2011) [Management of feto-maternal red cell allo-immunizations]. *Transfus Clin Biol* 18: 269-276.
11. Zhao Y, Dai ZP, Lv P, Gao XM (2002) Phenotypic and functional analysis of human T lymphocytes in early second- and third-trimester fetuses. *Clin Exp Immunol* 129: 302-308.
12. PiÅ...tosa B, Birbach M, Siewiera K, Ussowicz M, KaÅ,wak K, et al. (2013) Significant changes in the composition of the precursor B-cell compartment in children less than 2 years old. *Cytometry B Clin Cytom* 84: 179-186.
13. Noia G, Romano D, De Santis M, Gozto ML, Colacicco L, et al. (1999) Ontogeny of the fetal immune system: study on pregnancies with Rh-isoimmunization and nonimmune fetal hydrops. *Clin Immunol* 90: 115-118.
14. Fink PJ (2013) The biology of recent thymic emigrants. *Annu Rev Immunol* 31: 31-50.
15. Abbas AK, Lichtman AH, Pillai S (2014) Cellular and Molecular Immunology. Elsevier Saunders Press, Philadelphia, PA.
16. Davies NP, Buggins AG, Snijders RJ, Jenkins E, Layton DM, et al. (1992) Blood leucocyte count in the human fetus. *Arch Dis Child* 67: 399-403.
17. Vaisbuch E, Roberto R, Gomez R, Kusanovic JP, Mazaki-Tovi S, et al. (2011) An Elevated Fetal IL-6 Concentration Can Be Observed In Fetuses with Anemia Due To Rh Alloimmunization: Implications for the Understanding of the Fetal Inflammatory Response Syndrome. *J Matern Fetal Neonatal Med* 24: 391-396.