

Peripapillary Vascular Changes in Nonarteritic Anterior Ischemic Optic Neuropathy by Optical Coherence Tomography Angiography: A Case Report

Chun-Hsiu Liu, Ling-Yuh Kao, Wei-Chi Wu and Henry Shen-Lih Chen*

Department of Ophthalmology, Chang Gung Memorial Hospital, Chang Gung University College of Medicine, Taoyuan, Taiwan

*Corresponding author: Henry Shen-Lih Chen, Department of Ophthalmology, Chang Gung Memorial Hospital, Chang Gung University College of Medicine, Taoyuan, Taiwan, No 5, Fu-Shin Street, Kwei-Shan Hsien, Tau-Yuan Hsiang, Taiwan, Tel: 886-3-3281200 ext. 8666; Fax: 886-3-3287798; E-mail: hslchen@yahoo.com.tw

Received date: August 15, 2016; Accepted date: September 22, 2016; Published date: September 26, 2016

Copyright: © 2016 Liu CH, et al. This is an open-access article distributed under the terms of the Creative Commons Attribution License, which permits unrestricted use, distribution, and reproduction in any medium, provided the original author and source are credited.

Abstract

Background: To report the sequential peripapillary vascular changes in nonarteritic anterior ischemic optic neuropathy (NAION) with optical coherence tomography angiography (OCTA)

Methods: A 60-year-old male presented with right eye painless vision loss leading to inferior field defects and right eye 0.5 vision. The sequential OCTA was performed at presentation and 5 months later to evaluate the peripapillary vascular changes.

Results: At presentation, the OCTA revealed decreased peripapillary capillary perfusion in the area corresponding to the nerve fiber swelling, along with increased blood flow of the major retinal vessel. Five months later, the OCTA showed decreased blood flow in the major retinal vessel. The attenuation of peripapillary capillary plexus became more prominent.

Conclusion: OCTA can be a useful tool to demonstrate the detailed peripapillary vascular changes in NAION at the early stage of the disease.

Keywords: Nonarteritic anterior ischemic optic neuropathy; Optical coherence tomography angiography; Peripapillary retinal capillary; Blood flow; Optical coherence tomography

Introduction

Nonarteritic anterior ischemic optic neuropathy (NAION) is one of the most common and visually crippling diseases in middle-aged and elderly. It is presumed to result from vascular insufficiency in the optic nerve head, which is supplied by the posterior ciliary artery circulation [1]. Currently, fluorescein angiography (FA) is thought to be the only way to demonstrate the impaired circulation and its location in NAION. However, FA is an invasive procedure and requires contrast injection. On the contrary, newly developed optical coherence tomography angiography (OCTA) using split-spectrum amplitude-decorrelation angiography (SSADA) can visualize the blood flow and microvascular network by decorrelating the motion of red blood cells from the static tissues, without the need of contrast injection [2]. Herein, we report the peripapillary vascular changes by using OCTA in a case of NAION.

Material and Methods

In this observational case report, a 60-year-old male with history of hypertension and hyperlipidemia presented in the clinic after experiencing sudden onset of painless vision loss in the right eye for 14 days. Best corrected visual acuity was 0.5 in the right eye with right relative afferent *pupil* defect. Funduscopic examination revealed segmental disc edema in the patient's right eye and normal in the left eye (Figure 1). Humphrey perimetry disclosed inferior altitudinal

defect in the right eye and no visual field abnormalities in the left eye. The patient was diagnosed with NAION based on the lack of headache or tenderness.

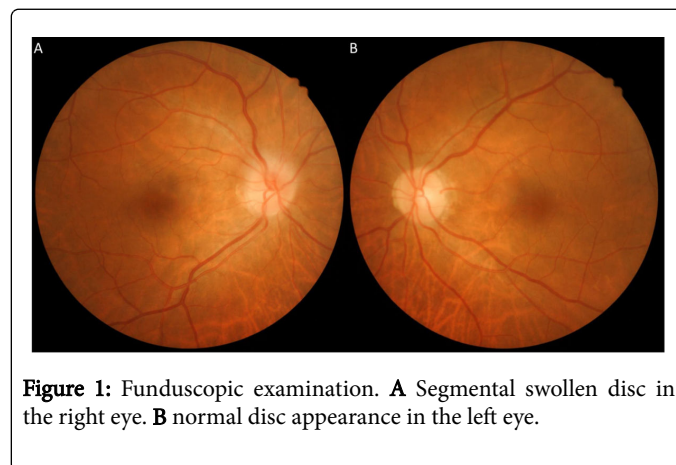


Figure 1: Funduscopic examination. **A** Segmental swollen disc in the right eye. **B** normal disc appearance in the left eye.

Initially, the OCTA (RTVue-XR, AngioVue; Optovue, Inc., Fremont, CA, USA, using standard AngioVue software (version 2015.1.0.90)) of left eye revealed a normally dense radial peripapillary capillary network. In the contrary, the OCTA of right eye revealed decreased radial peripapillary capillary perfusion in the area corresponding to the nerve fiber layer swelling. Grid-based vessel density in the corresponding area also showed much decrease in the right eye than left eye (36.59% and 53.17%, respectively). The blood flow of the major retinal vessel became more prominent. The choroidal capillary of right eye remained unchanged comparing with contralateral eye (Figure 2).

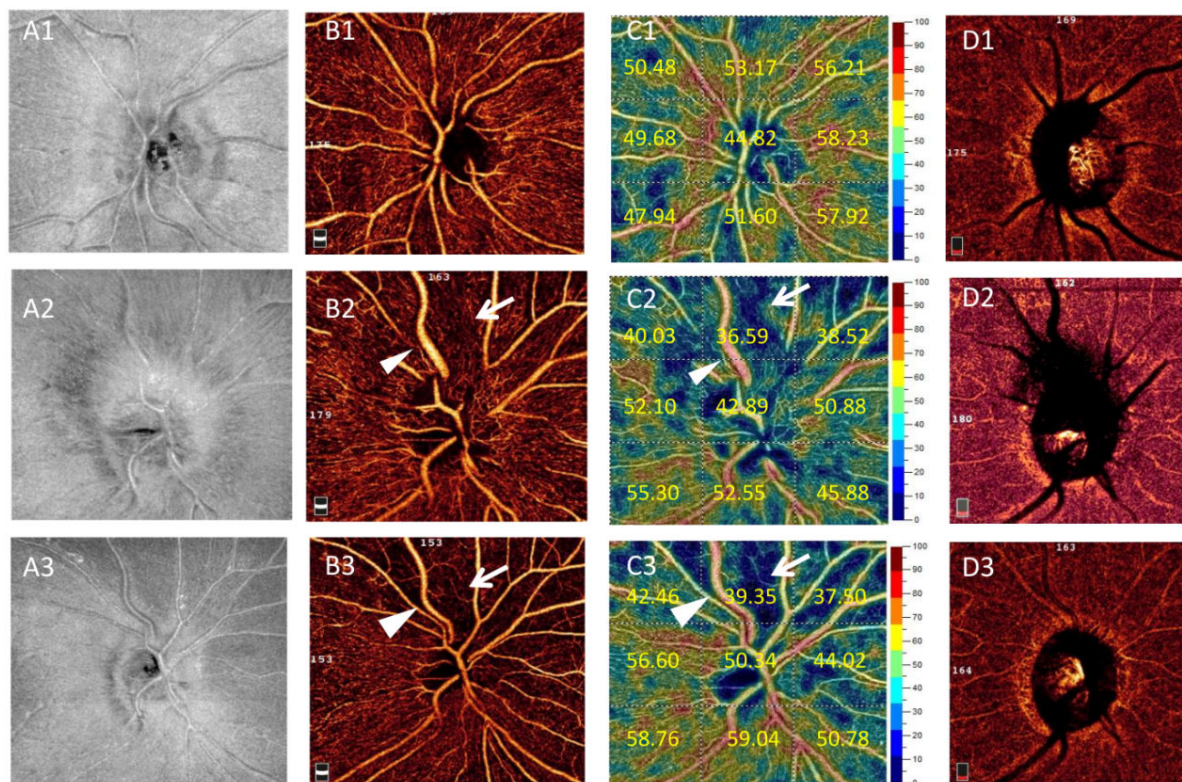


Figure 2: en face optical coherence tomography (A1-A3), optical coherence tomography angiography (OCTA) of radial peripapillary capillary (RPC) (B1-B3), color mapped OCTA of RPC and grid-based vessel density (%) (C1-C3), OCTA of choroid (D1-D3) in the left eye and right eye at baseline (A1-D1 and A2-D2 respectively), and in the right eye at 5 month (A3-D3). At baseline, the right eye revealed decreased peripapillary capillary perfusion (B2 and C2 arrows) in the area corresponding to the nerve fiber layer swelling. The blood flow of the major retinal vessels became more prominent (B2 and C2 arrowheads). At 5 month, the blood flow of the major retinal vessel decreased (B3 and C3 arrowheads) and the attenuation of peripapillary capillary perfusion persistent (B3 and C3 arrows). The choroidal capillary of right eye remained unchanged comparing with contralateral eye (D1) either at baseline (D2) or at 5 month (D3).

We advised to control vascular risk factors including hypertension and hyperlipidemia and did not prescribe other medication since there is no known effective therapy [3]. At the 5-month follow up visit, edema of the right optic nerve disc had resolved and the optic nerve disc appeared pale. The visual acuity and visual field remained unchanged. Follow-up OCTA of right eye revealed decreased blood flow in the major retinal vessel. The attenuation of small vascular branches became more prominent.

Results and Discussion

Our case demonstrated decreased radial peripapillary capillary perfusion in the area of nerve fiber layer swelling in the early stage of the disease. To the best of our knowledge, this is the first case report using OCTA in NAION.

The pathogenesis of NAION remains unclear. It is presumed to result from infarction in the retrolaminar portion of the optic nerve head, but the exact location is still poorly understood [1]. Previous study using laser Doppler velocimetry revealed decreased optic nerve head circulation at both temporal and nasal sites [4], but laser Doppler velocimetry is not sensitive enough to measure detailed changes of small vessels. FA study also demonstrated delayed optic disc filling

without impairment of choroidal circulation [5]. However, FA is not depth resolved and the localization of the depth of the lesion can be difficult. OCTA in comparison can visualize the individual vascular plexus. In the present report, OCTA showed focal radial peripapillary capillary non-perfusion in areas corresponding to the nerve fiber layer swelling, without change of the choroidal vascularity. It corresponds to previous FA results and corroborates that the impaired optic disc perfusion locates within the territory of the para-optic branches of the short posterior ciliary arteries, instead of resulting from short posterior ciliary artery occlusion or from hypoperfused peripapillary choroid [5]. In addition, the blood flow is still seen in the major retinal vessels and even more prominent than vessels in the contralateral eye. This phenomenon agrees with previous study which showed focal early disc hyperfluorescence in the inner surface layer of the disc, and is thought to result from compensatory capillary dilation in response to ischemia of adjacent disc tissue [5].

Conventional optical coherence tomography (OCT) is useful to monitor the peripapillary retinal nerve fiber layer (RNFL) and macular thickness changes. However, at early stage of NAION, the loss of retinal ganglion cell is prone to be masked by increased RNFL due to optic disc swelling. Therefore, previous reports demonstrated that the significant thinning of RNFL in AION could only be detected via OCT

until six months after disease onset [6]. The newly developed OCTA visualizes vasculature using motion contrast. The target of OCTA measurement is the dynamic blood flow within the vessel instead of the vessel itself. Thus, it is better to reveal the vascular change and less bias by the disc edema. As shown in our case, although the local geometry of the major retinal vessels is slight deformed secondary to disc edema, OCTA still can reveal decreased radial peripapillary capillary perfusion as early as two weeks after disease onset.

Our case demonstrates peripapillary vascular change in NAION. Although it is still unclear whether vascular changes are a primary or secondary consequence in NAION, OCTA provides a new non-invasively imaging target to characterize retinal vascular changes and may have a role in understanding the pathophysiology and early diagnosis of NAION.

Acknowledgments

The authors have neither proprietary nor financial interests in the devices described in this paper.

References

1. Knox DL, Kerrison JB, Green WR (2000) Histopathologic studies of ischemic optic neuropathy. *Trans Am Ophthalmol Soc* 98:203-220;
2. Jia Y, Morrison JC, Tokayer J, Tan O, Lombardi L, et al. (2012) Quantitative OCT angiography of optic nerve head blood flow. *Biomed Opt Express* 3:3127-3137.
3. Katz DM, Trobe JD (2015) Is there treatment for nonarteritic anterior ischemic optic neuropathy. *Current opinion in ophthalmology* 26: 458-463.
4. Collignon-Robe NJ, Fekete GT, Rizzo JF 3rd (2004) Optic nerve head circulation in nonarteritic anterior ischemic optic neuropathy and optic neuritis. *Ophthalmology* 111: 1663-1672.
5. Arnold AC, Hepler RS (1994) Fluorescein angiography in acute nonarteritic anterior ischemic optic neuropathy. *American journal of ophthalmology* 117: 222-230.
6. Goto K, Miki A, Araki S, Mizukawa K, Nakagawa M, et al. (2016) Time Course of Macular and Peripapillary Inner Retinal Thickness in Non-arteritic Anterior Ischaemic Optic Neuropathy Using Spectral-Domain Optical Coherence Tomography. *Neuro-ophthalmology* 40: 74-85.