

Pericardial Angiosarcoma: An Elusive Diagnosis

Ashley Silakoski¹, Felecia Jinwala², George Batsides², Leonard Lee², Anthony Lemaire² and Aziz Ghaly^{2*}

¹Rutgers-Robert Wood Johnson Medical School, 675 Hoes Lane West, Piscataway, N.J. 08854

²Rutgers-RWJUH, Department of Surgery, 1 Robert Wood Johnson Place, New Brunswick, N.J. 08901

*Corresponding author: Aziz Ghaly, Rutgers-RWJUH, Department of Surgery, 1 Robert Wood Johnson Place, New Brunswick, NJ 08901, USA, Tel: 732-235-78101; E-mail: aziz.ghaly@rwjms.rutgers.edu

Received date: Jul 06, 2015; Accepted date: Jul 30, 2015; Published date: Jul 31, 2015

Copyright: ©2015 Silakoski A, et al. This is an open-access article distributed under the terms of the Creative Commons Attribution License, which permits unrestricted use, distribution, and reproduction in any medium, provided the original author and source are credited.

Abstract

The diagnosis of pericardial angiosarcoma is rare. We present a 33 year-old man with recurrent hemorrhagic pericardial effusions ultimately diagnosed with pericardial angiosarcoma by surgical biopsy. This case report highlights the challenges in diagnosing primary pericardial malignancy.

Keywords: Pericardial effusion; Angiosarcoma; Pericardiectomy

Introduction

Primary cardiac tumors are exceedingly rare, with reports of primary pericardial tumors even more limited. Angiosarcoma is the most common primary pericardial malignancy. The diagnosis of pericardial angiosarcoma is difficult to make, since the presentation is generally non-specific and imaging modalities, such as echocardiography and computer tomography (CT) scan, are non-specific. The most common presenting symptom is dyspnea caused by tamponade due to pericardial effusion or direct compression from the mass. Frequently, patients are misdiagnosed with viral pericarditis and the diagnosis is made late in the course when the patient deteriorates rapidly or during surgical exploration. When the diagnosis is made early, however, patients may benefit from surgical resection and chemotherapy. Mean survival is approximately 6 months even with aggressive treatment [1].

Case Presentation

We report a 33 year-old man who presented to an outside hospital with chest pain and dyspnea on exertion. An echocardiogram demonstrated a large pericardial effusion. The patient underwent pericardiocentesis, which removed two liters of hemorrhagic fluid; however, the effusion recurred, requiring open drainage via a subxiphoid incision during the same admission. Postoperatively the effusion recurred, and the patient was transferred to our institution. An echocardiogram demonstrated tamponade physiology and for this reason, the patient was taken to the operating room for drainage of the recurrent effusion. An incision was made over the patient's previous subxiphoid incision but due to extensive adhesions the operation was converted to a median sternotomy. These adhesions resembled an acute inflammatory process. Multiple pockets of hemorrhagic effusion were drained. Pericardial and epicardial biopsies demonstrated dense fibroconnective tissue consistent with fibrinous pericarditis. Cytology revealed abundant red blood cells. The patient's immediate post-operative course was uncomplicated, and he was discharged on a course of non-steroidal anti-inflammatory drugs and colchicine.

The patient presented to his cardiologist two months later with dyspnea. An echocardiogram demonstrated a moderate pericardial

effusion. The patient was readmitted for progressive dyspnea. Two days after his admission, the patient's symptoms worsened and a repeat echocardiogram showed a thickened pericardium and a loculated effusion, which failed percutaneous drainage. Similarly, a CT angiogram of the chest demonstrated markedly thickened pericardium and pericardial effusion (Figures 1A and 1B). He was taken to the operating room on hospital day four for re-do sternotomy and pericardiectomy. There was thick, leathery pericardium and extensive adhesions, making the heart chambers difficult to identify. Given the complexity of the case, the patient was placed on cardiopulmonary bypass via groin cannulation before proceeding with the dissection. Dense adhesions prohibited dissection of the posterior pericardium, but the sac was otherwise dissected off the great vessels and diaphragmatic surface. The chest was left open and drains were placed. Total bypass time was 182 minutes.

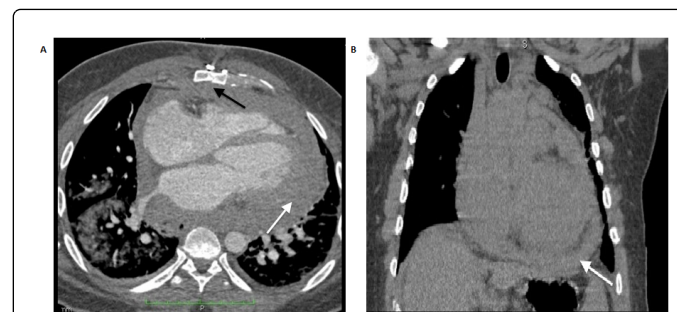


Figure 1: Axial and coronal chest CT images respectively. The axial image demonstrates the diffuse, thickened pericardium and associated effusion (white arrow), despite the patient's previous sternotomy (black arrow). This finding is also readily identified on the coronal image. A visible pericardial mass was not identified on either section.

Postoperatively, the patient developed severe metabolic acidosis, diffuse mottling of his skin, and multi-system organ dysfunction. He had multiple episodes of cardiopulmonary arrest and ultimately expired on post-operative day 1. Surgical pathology of the pericardium demonstrated angiosarcoma (Figures 2A and 2B).

Discussion

Angiosarcoma of the pericardium is a rare malignancy, often difficult to diagnose. Currently, fewer than 30 case reports exist in the literature. In many of these cases, the chief complaint was dyspnea resulting from cardiac tamponade. Nearly all patients had at least a mild pericardial effusion, though most were large and hemorrhagic. A case report by Park et al. describes a young adult man who presented with hemorrhagic pericardial effusion of unknown etiology [2].

Workup including cytology, CT, and echocardiography failed to identify a malignancy. The effusion recurred 3 months later, at which time CT scan demonstrated an unresectable pericardial angiosarcoma. This highlights the difficulty in early diagnosis of this malignancy and the limitations of imaging modalities during early stage disease. Holtan et al. described a similar case of recurrent pericardial effusions; however, diagnosis of primary pericardial angiosarcoma was made by open surgical exploration and biopsy [3].

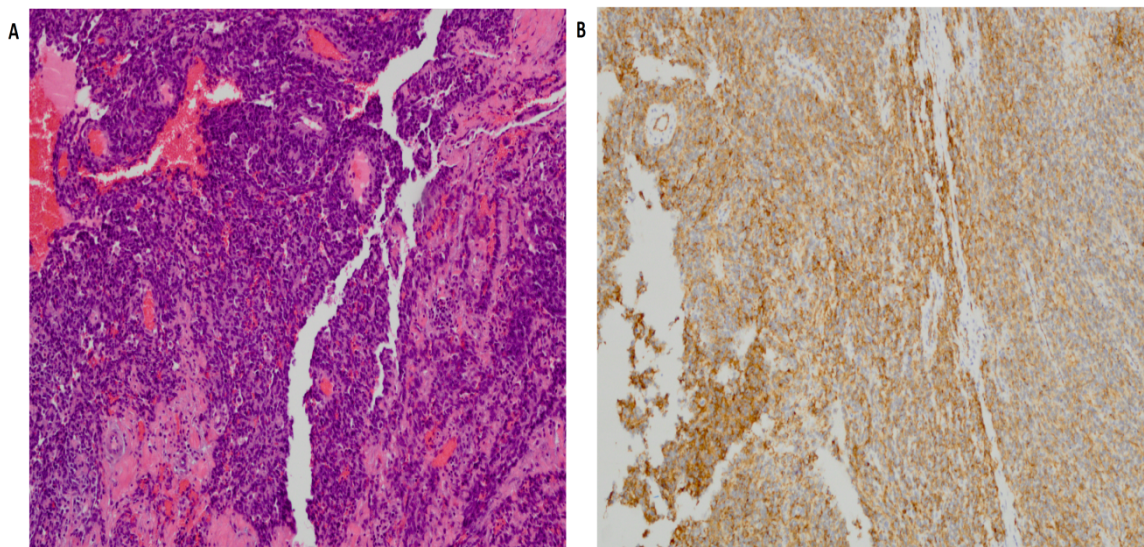


Figure 2: Histological specimens obtained from the pericardium (10X). The lesion shows exuberant proliferation of cells with high nuclear to cytoplasmic ratio, numerous mitoses, and necrosis with focal papillary architecture and anastomosing vascular channels in the first image. The second image demonstrates positive immunohistochemical stain for CD31, a marker found on endothelial cells and associated with vascular tumors such as angiosarcomas

In young patients with recurrent hemorrhagic pericardial effusions, suspicion of malignancy should be high and the patient should undergo close monitoring. While chest CT scan appropriately identify many types of pericardial pathology, CT is not effective at consistently detecting pericardial malignancy [4]. Primary pericardial tumors often appear as thickened pericardium with diffuse enhancement, and thus appear similar to other types of constrictive pericarditis. CT may be more accurate in the later stages as the cancer becomes bulky, as seen by Park et al. While studies examining the efficacy of magnetic resonance imaging (MRI) in detecting pericardial malignancy have not been performed, it is an imaging modality that may hold promise. Despite advances in medical technology, the most accurate way to diagnose pericardial angiosarcoma remains surgical pericardiectomy with wide margins (both diagnostic and therapeutic).

Early diagnosis may provide the best chance for survival since it allows time to treat with chemotherapy. There are few case reports demonstrating the efficacy of chemotherapy for primary pericardial angiosarcoma. In a case similar to ours, a 31 year-old man was misdiagnosed with viral pericarditis and was managed with anti-inflammatory medications and pericardiocentesis [5]. A pericardial mass invading the right atrium was later detected on MRI and surgical biopsy confirmed pericardial angiosarcoma. Transplantation was considered, but the patient was deemed to be a poor surgical candidate and chemotherapy with vincristine, ifosfamide, doxorubicin, and etoposide was initiated. Failure with this regimen prompted the

initiation of paclitaxel, which reduced the tumor size for only a few months. Pazopanib chemotherapy was then initiated and the patient improved clinically and was alive at 10-month follow up when the case was reported. Other studies have shown either clinical improvement or stabilization of the disease process with chemotherapy; others have demonstrated that patients treated with multimodal therapy (combination of resection, chemotherapy, and radiation) had longer survival than those treated with chemotherapy or resection alone [6,7]. A 32 year-old woman who underwent surgical resection and combination therapy was disease free at her 13th postoperative month, suggesting that advancements in multimodal therapy may prolong survival for patients and improve their overall quality of life [8].

In conclusion, clinicians should have a high index of suspicion for pericardial malignancy in young patients with unexplained recurrent pericardial effusions. Historically, these patients benefit from surgical exploration for definitive diagnosis and staging. Echocardiography and CT imaging have limited utility in the diagnosis of pericardial malignancy during the earliest stages of disease. Chemotherapy can be considered to extend survival or for palliation. Although early diagnosis may result in earlier surgical resection and chemotherapy administration, the prognosis remains dismal with few patients surviving past a few years.

Acknowledgements and disclosures

We would like to acknowledge the cardiothoracic surgery, radiology, and pathology departments for their assistance in guiding this project to completion. All authors have no conflicts of interest to disclose.

References

1. Brinckman SL, van der Wouw P (2005) Images in cardiovascular medicine. Angiosarcoma of the pericardium: a fatal disease. *Circulation* 111: e388-389.
2. Park SM, Kang WC, Park CH, Shin MS, Chung WJ, et al. (2008) Rapidly growing angiosarcoma of the pericardium presenting as hemorrhagic pericardial effusion. *Int J Cardiol* 130: 109-112.
3. Holtan SG, Allen RD, Henkel DM, Kamal AH, Novak GD, et al. (2007) Angiosarcoma of the pericardium presenting as hemorrhagic pleuropericarditis, cardiac tamponade, and thromboembolic phenomena. *Int J Cardiol* 115: e8-9.
4. Young PM, Breen JF (2013) CT imaging of the pericardium. *Curr Cardiovasc Imaging Rep* 6: 259-267.
5. Ong P, Greulich S, Schumm J, Backes M, Kaufmann M, et al. (2012) Favorable course of pericardial angiosarcoma under paclitaxel followed by pazopanib treatment documented by cardiovascular magnetic resonance imaging. *Circulation* 126: e279-281.
6. Mayer F, Aebert H, Rudert M, Königsrainer A, Horgner M, et al. (2007) Primary malignant sarcomas of the heart and great vessels in adult patients--a single-center experience. *Oncologist* 12: 1134-1142.
7. Fatima J, Duncan AA, Maleszewski JJ, Kalra M, Oderich GS, et al. (2013) Primary angiosarcoma of the aorta, great vessels, and the heart. *J Vasc Surg* 57: 756-764.
8. Olsun A, Duzyol C, Gur AK, Kaplan M, Tosun R (2007) Right atrial angiosarcoma: a case report. *Heart Surg Forum* 10: E219-221.