

# Percutaneous Extraction of a Catheter Fragment of Totally Implantable Venous Device Migrating into the Left Pulmonary Artery

Bouzelmat H, Kheyi J, Raissuni Z\*, Chaib A and Moustaghfir A

Department of Cardiac Intensive Care Unit, Mohammed V Military Hospital, Rabat, Morocco

\*Corresponding author: Raissuni Z, Department of Cardiac Intensive Care Unit, Mohammed V Military Hospital, 10000, Rabat, Morocco, Tel: 00212601389437; E-mail: zainab.raissouni@hotmail.com

Rec date: Apr 04, 2014, Acc date: Jun 24, 2014, Pub date: Jun 30, 2014

Copyright: © 2014 Bouzelmat H, et al. This is an open-access article distributed under the terms of the Creative Commons Attribution License, which permits unrestricted use, distribution, and reproduction in any medium, provided the original author and source are credited.

## Abstract

Totally implantable venous devices (TIVDs) are usually utilized for venous access for chemotherapy of cancers. Fracture and migration into the left pulmonary artery of catheter fragment are a potentially severe and rare complication. We present a case of an asymptomatic patient who had this complication. Percutaneous retrieval is now the standard of care. We discuss, through this observation, the usefulness of this technique used an intravascular snare to capture and secure the catheter fragment and we concluded that it is generally advisable to retrieve this foreign body even in asymptomatic patients.

**Keywords:** Totally implantable venous devices; Catheter complications; Catheter migration; Left pulmonary artery; Snare technique

## Introduction

Totally implantable venous devices (TIVDs) are usually utilized for venous access for chemotherapy of cancers. The use of these systems has improved the quality of life of patients. However, despite the great usefulness of TIVDs, their insertion is not free of complications. We present a case of a patient who had a rare and potentially serious complication secondary to catheter disconnection and migration into the left pulmonary artery.

## Case Report

A 50-year-old female patient had breast cancer. She underwent placement of a TIVDs via the right subclavian vein, for the infusion of chemotherapeutic agents. The procedure was simple, and a routine chest XR showed no complication. After two months, the patient was seen for her third cycle of treatment. Blood aspiration was impossible, and a saline injection of the port caused pain over the superior aspect of the right anterior chest wall. She was stable, with normal investigations including an ECG. A chest XR showed that fragment was positioned between right ventricle and the left pulmonary artery (Figure 1A). A transthoracic echocardiography demonstrated the exact location of the two tips: the proximal one is located at the apex of the right ventricle and the distal at the left pulmonary artery (Figure 1B). Computed tomography (CT) was not performed because she had a moderate renal impairment. Our patient had no symptoms but she insisted on undergoing this foreign body retrieval. Four days later, a trans-venous percutaneous retrieval via the right groin approach, under local anaesthetic, and using The Needle's Eye Snare® was underwent successfully. After a right femoral vein percutaneous access using a micropuncture technique. A guide wire was introduced through the sheath and manipulated through the right heart into the left main pulmonary artery. Then, the fragment was captured (Figure 1C). The snare with the secured catheter fragment was withdrawn

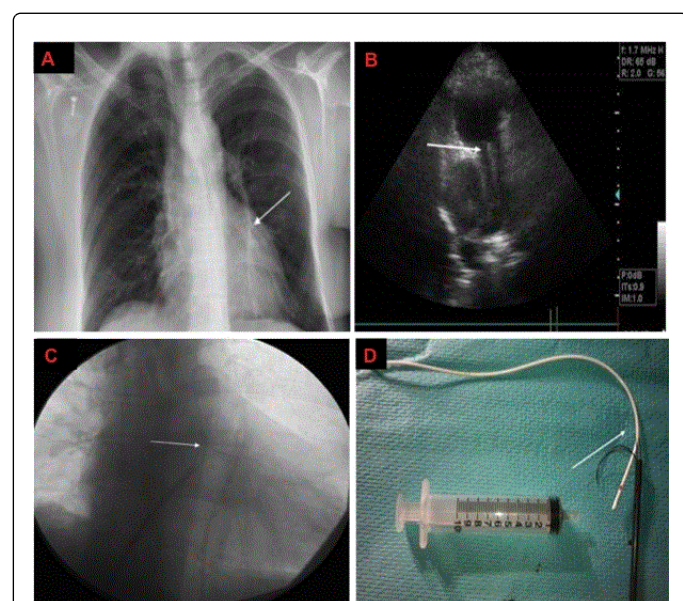
through the tricuspid valve, right atrium, and into the inferior vena cava (IVC). The vascular sheath and snared catheter fragment were then withdrawn as a unit out through the skin of the right groin (Figure 1D). Fluoroscopic examination of the IVC, heart and pulmonary arteries revealed no residual catheter fragments. The entire procedure, from the initial access of the femoral vein to extraction of the fragment through the skin, was 43 minutes in duration with no complication.

## Discussion

TIVDs constitute a convenient access for long term intravenous chemotherapy [1]. Several large studies have demonstrated the safety and low rate of complication associated with TIVDs. These complications include infection, thrombosis, venous perforation, catheter leakage, dislodgment, subintimal entrapment [2,3]. Catheter fracture and migration are rare complications and may occur in up to 1% of TIVDs used for long-term treatment [4]. The mechanism of catheter fracture is thought by many authors to be a result of the so-called 'pinch-off' syndrome that is defined as the anatomic mechanical compression of a catheter as it passes between the clavicle and first rib at the costoclavicular space [5]. Most often the intravascular fragment becomes lodged within the right heart where it may produce an arrhythmia or compromise a valve. Less frequently, the intravascular fragment lodges more distally within a pulmonary artery with the risk of causing a pulmonary infarction. A very rare migration site is the left pulmonary artery. A French study has divided clinical signs of catheter embolization as follows: catheter malfunction (56.3%), arrhythmia (13%), pulmonary symptoms (4.7%), and septic syndromes (1.8%), but 24.2% of cases were asymptomatic [6]. Richardson et al. followed 76 cases of retained catheter emboli and found a complication rate of 45% and a mortality rate of 23.7% [7]. Despite these reviews, there exist in the literature arguments for conservative management of catheter emboli particularly asymptomatic patient [8,9]. However, even patients without symptoms may have actively mobile catheter in the future that could provoke life-threatening complications [10]. Until 1964, thoracotomy was the only method to retrieve catheter emboli [11]. Percutaneous retrieval is now

the standard of care. it is inexpensive, of relatively low risk, and is almost always successful [11-13].

There are several endovascular techniques available for retrieving intravascular foreign bodies including endovascular forceps and retrieval baskets similar to those used in the biliary system and urinary tract. However, the most commonly used device for intravascular catheter fragment retrieval is an endovascular snare introduced via a catheter as originally described by Curry [14]. Snare have an advantage because when opened they fill the cross section of the vessel. These devices require that one end of the catheter fragment remains in a vessel and not in a chamber.]. In our case, the location in left artery full-filled this condition. Consequently, the procedure was not difficult. In rare cases, surgical intervention is needed [15].



**Figure 1:** A- Initial chest film showing migrated catheter fragment into the left pulmonary artery (white arrow). B- Trans-thoracic echocardiography visualising catheter fragment in the left pulmonary artery (white arrow). Right pulmonary artery is free. C- The tip of the fragment in the left pulmonary artery is captured with The Needle's Eye Snare ® (white arrow). D- The vascular sheath and the 23 cm snared catheter fragment were withdrawn as a unit out through the skin (white arrow).

## Conclusion

Fracture and migration into the left pulmonary artery of catheter fragment are a potentially severe and rare complication.

Patients might be asymptomatic or may develop severe systemic clinical signs. The Decision of the intervention should depend essentially on the clinical tolerance and on the patient choice. However, it is generally advisable to this retrieve this foreign body percutaneous even in asymptomatic patients because of the possible mobility of this fragment in the future.

## References

- Hall P, Cedermark B, Swedenborg J (1989) Implantable catheter system for long-term intravenous chemotherapy. *J Surg Oncol* 41: 39-41.
- Kock HJ, Pietsch M, Krause U, Wilke H, Eigler FW (1998) Implantable vascular access systems: experience in 1500 patients with totally implanted central venous port systems. *World J Surg* 22: 12-16.
- Polderman KH, Girbes AJ (2002) Central venous catheter use. Part 1: mechanical complications. *Intensive Care Med* 28: 1-17.
- Andris DA, Krzywda EA, Schulte W, Ausman R, Quebbeman EJ (1994) Pinch-off syndrome: a rare etiology for central venous catheter occlusion. *JPEN J Parenter Enteral Nutr* 18: 531-533.
- Aitken DR, Minton JP (1984) The "pinch-off sign": a warning of impending problems with permanent subclavian catheters. *Am J Surg* 148: 633-636.
- Marie O, Leverger G, Douard MC, Mourey F, Roche A, et al. (1986) [Intravascular migration of fragments of central venous catheters. 3 cases]. *Presse Med* 15: 1270-1272.
- Richardson JD, Grover FL, Trinkle JK (1974) Intravenous catheter emboli. Experience with twenty cases and collective review. *Am J Surg* 128: 722-727.
- Graham KJ, Barratt-Boyes BG, Cole DS (1970) Catheter emboli to the heart and pulmonary artery. *Br J Surg* 57: 184-186.
- Székely J, Rác L, Karátson A (1989) Broken piece in the lungs: a complication of haemodialysis via subclavian cannulation. *Int Urol Nephrol* 21: 533-540.
- Anoma N, Scott OT (2004) Delayed Migration of a Catheter Fragment from the Left to the Right Pulmonary Artery. *J Vasc Interv Radiol* 15: 497-499.
- Fisher RG, Ferreyro R (1978) Evaluation of current techniques for nonsurgical removal of intravascular iatrogenic foreign bodies. *AJR Am J Roentgenol* 130: 541-548.
- Edwards AC, Sowton E (1978) Management of embolised central venous catheters. *Br Med J* 2: 669-670.
- Huang TY, Abaskaron M (1984) Nonsurgical removal of intravascular fragmented catheter. *Am Fam Physician* 30: 177-180.
- Curry JL (1969) Recovery of detached intravascular catheter or guide wire fragments. A proposed method. *Am J Roentgenol Radium Ther Nucl Med* 105: 894-896.
- Sattari M, Kazory A, Phillips RA (2003) Fracture and cardiac migration of an implanted venous catheter. *Interact Cardiovasc Thorac Surg* 2: 532-533.