

Percutaneous Closure of Periprosthetic Paravalvular Leak: Single Center Experience

Giacomo Giovanni Bocuzzi^{1*}, Catia De Rosa², Innocenzo Scrocca², Mauro De Benedictis², Emanuele Meliga², Tiziana Aranzulla², Eulogio Garcia³ and Maria Rosa Conte²

¹Division of cardio-vascular intervention, Ospedale San Giovanni Bosco, Turin, Italy

²Interventional Cardiology Unit, Mauriziano Hospital, Turin, Italy

³Department of Interventional Cardiology, Cardiovascular Institute, Hospital Clínico San Carlos, Madrid, Spain

Abstract

Background: Clinical significant periprosthetic paravalvular leak (PVL) is an uncommon but serious complication after surgical valve replacement. Percutaneous closure has been utilized as an alternative to surgical repair in high-risk surgical patients.

Aim: to evaluate the feasibility and efficacy of percutaneous closure of PVL using the Amplatzer vascular Plug III device in a consecutive series of patients referred to our structural heart disease center.

Methods: Between February 2010 and February 2013, 12 patients (mean age 68.3 ± 9.2 years, 66% male) who were believed to be poor operative candidates (heart team evaluation) underwent PVL closure with Amplatzer Vascular Plug III device.

Results: 58.3 % of patients had mitral paravalvular leak, 41.7% had aortic one. The median time since valve replacement (biologic prosthesis 88% and mechanical prosthesis 12%) was 36 ± 9 months. Technical procedural success was achieved in 92% of cases; in 6 patients (50%) more than one device was necessary. One intra-Hospital death occurs after fifteen days from procedure for non-cardiac causes. At follow up (ranging between 3-20 months) clinical success was achieved in 83% (10 of 12 patients). One patient underwent second procedure with third device implantation 49 days after first closure; one patient, with persistent residual leak and haemolysis parameters worsening, underwent surgical repair. At 12 month 83.3% of patients were alive.

Conclusions: In our experience, percutaneous closure of PVL is feasible and safe. It may be considered in selected patients in whom re-surgical intervention is deemed high-risk or is contraindicated.

Keywords: Paravalvular leak; Cardiac catheterization; Transcatheter closure

Introduction

The incidence of primary paravalvular leak (PVL) after cardiac valve replacement varies from 2% to 17% in the different series. Most frequently it is observed after mitral valve replacement, occurring in up to 12.5% of patients and represents the most common reason for repeat of mitral valve replacement surgery [1-3]. Most PVLs remain clinically silent; however, 1-5% of patients with PVLs can lead to serious clinical consequences [4-6]. Surgical reoperation is the gold standard therapy for symptomatic PVLs, but both the risk of re-leak and the operative mortality increase with each successive both of valve replacement or repair, starting at the first intervention from 22-35% and 6%, respectively [7,8]. On the other hand, previous studies have reported an improved long-term survival, for patients with PVL, if aggressive strategy is adopted [9].

The percutaneous closure of PVL would offer the potential for being the "first step" therapy in patients who are poor surgical candidates due to complex surgical history or to the significantly compromised ventricular function. The procedure was first proposed and attempted by Hourihan et al. more than ten year ago using a double-umbrella device for aortic paravalvular and valvular leaks [10]. However, due to technical difficulties, inadequate devices and lack of follow up results, the experience is still limited. Results of percutaneous PVL closure have been reported by a number of case series [11-28] showing that for the high-risk symptomatic PVL patient, percutaneous closure is a viable therapeutic strategy to surgical PVL repair. This study was performed to evaluate the feasibility and efficacy of percutaneous closure of PVL

using the Amplatzer vascular Plug III device in a consecutive series of patients referred to our structural heart disease center.

Material and Methods

Definition

Periprosthetic paravalvular leak is defined as a regurgitant jet, demonstrated by Doppler echocardiography, originating between the outer margin of the prosthetic sewing ring and the native tissues around the valve. Congestive heart failure is defined as symptoms consistent with a New York Heart Association (NYHA) functional class greater than II. Haemolysis can be identified by a serum lactate dehydrogenase level >460 U/L and any two of the four following criteria: blood haemoglobin <13.8 g/dL for males or <12.4 g/dL for females, serum haptoglobin <50 mg/dL, and reticulocyte count $>2\%$ [29]. Technical success can be defined as the correct deployment of an occlusive device through the PVL and the lack of significant residual regurgitation or

***Corresponding author:** Giacomo G Bocuzzi, Department of Cardiology, Invasive Cardiology Unit, Ospedale San Giovanni Bosco, Piazza donatore del sangue, 310154 Torino, Italy, Tel: 00390112402422, 00393473177021; Fax: 00390112402852; E-mail: giacomobocuzzi@libero.it

Received May 14, 2013; Accepted June 04, 2013; Published June 06, 2013

Citation: Bocuzzi GG, De Rosa C, Scrocca I, De Benedictis M, Meliga E et al., (2013) Percutaneous Closure of Periprosthetic Paravalvular Leak: Single Center Experience. J Clin Exp Cardiol S3: 007. doi:10.4172/2155-9880.S3-007

Copyright: © 2013 Bocuzzi GG, et al. This is an open-access article distributed under the terms of the Creative Commons Attribution License, which permits unrestricted use, distribution, and reproduction in any medium, provided the original author and source are credited.

new prosthetic valve malfunction. Clinical success, depending on the indication for intervention, is defined as an improvement in ≥ 1 NYHA-functional class and/or improvement in mechanical haemolysis.

Patient selection

Patients were considered candidates for attempted transcatheter closure of paravalvular leak only if 1) closure was indicated for clinical and haemodynamic reasons and 2) either the risk associated with annular reconstruction and valve replacement was considered too high. The Heart team made this determination (Table 1). Each patient had one of the following conditions: history of mediastinitis, chronic obstructive pulmonary disease, other prosthetic valve and severe haemolytic anaemia requiring multiple transfusions of packed red blood cells (Table 2).

All patients underwent detailed two and 3D dimensional Doppler and colour flow imaging by transthoracic and transesophageal echocardiography (TEE). TEE 3-D perfectly defines the size and shape of the paravalvular leak, especially mitral ones.

Procedure

The procedures were performed under general anaesthesia or deep sedation. Standard fluoroscopy, invasive hemodynamics, and two-dimensional (2D) and three-dimensional (3D) transesophageal echocardiography (TEE) imaging were performed during device placement.

Paravalvular mitral leak: Left femoral artery and right femoral vein were obtained and a 5 and a 8 Fr sheath were inserted, respectively. Heparin sulphate (150 IU/kg; maximum 7,500 IU) was given after performing the Brockenbrough atrial septostomy with a 19 gauge transeptal needle (Cook) and an 8 Fr Mullins sheath (Cook). A left ventricular angiogram in the right anterior oblique view (long-axial view) was obtained as judge necessary. Mitral paravalvular leaks were closed using the anterograde or the retrograde approach. In the anterograde approach, the leak was crossed using a 0.035" glide wire (Terumo) and a 5 Fr right coronary Judkins or a mammary catheter (Cordis, Miami, FL). After crossing the leak, in most cases the wire was further advanced into the ascending aorta and an AV loop was formed using a gooseneck snare in the ascending aorta previously introduced from the femoral artery. The delivery sheath is advanced over the AV loop from the venous site to the left ventricle (LV) through the leak, and the selected Amplatzer Vascular Plug III device was loaded and advanced through the sheath until it reached the tip and then the retention flange was deployed in to the left ventricle. The sheath and the device were pulled back to the level of paravalvular leak and the device was deployed in the defect.

In the retrograde approach, the leak was crossed using a 4 Fr right coronary Judkins catheter or a Mammary catheter with the aid of a 0.035 glide wire or a 0.014 wire (Figure 1) that was advanced to a pulmonary vein (from LV through the left atrium reaching the left superior pulmonary vein). An Amplatz gooseneck snare was advanced through the aforementioned Mullins long sheath, already in the left atrium, into the pulmonary vein and the wire was snared and exteriorized trough the venous sheath to establish a stable arterio-venous guidewire circuit (Figure 2). The delivery sheath is advanced over the AV loop from the venous site to the left ventricle (LV) through the leak. The selected device was loaded into the delivery system and placed across the leak in the manner previously described (Figure 3). Repeat complete TEE study and left ventricular angiogram were used to assess final device position and to evaluate the residual defect's dimension.

Paravalvular aortic leak. Right femoral artery was obtained and 6 Fr sheath was inserted. Heparin sulphate (150 IU/kg; maximum 7,500 IU) was given. An aortography was routinely obtained in the left anterior oblique view. Aortic PVLs were closed using the retrograde technique except in cases where aortic and mitral PVLs were simultaneously closed in the same procedure. In the retrograde technique, PVL was crossed using a 5 Fr Multipurpose catheter with the aid of a hydrophilic guidewire (Figure 4). After crossing the defect, the catheter was removed and the delivery system was advanced across the paravalvular leak into left ventricle (Figure 5). Then the selected Amplatzer Vascular Plug III device was loaded and placed in the manner previously described. The aortography was repeated to confirm the position of the device and to evaluate the residual defect's dimension (Figure 6).

Statistical analysis

Basic statistical test were performed using SPSS (version 12). For each parameter, mean, median, variance, standard deviation, and range were calculated.

Results

Between February 2010 and February 2013, 12 patients (mean age 68.3 ± 9.2 years) were referred to our centre for percutaneous closure

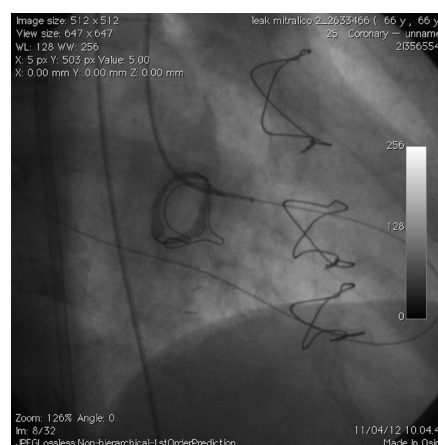


Figure 1: Mitral leak closure. Straight Terumo wire through anterolateral leak by anterograde approach and through posterolateral leak passing retrogradely.

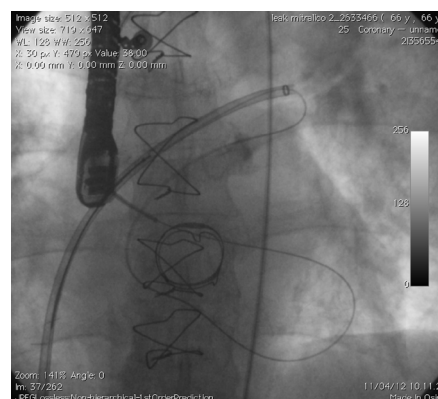


Figure 2: Mitral leak closure. Arteriovenous loop: transeptal catheter through interatrial septum, hydrophilic wire passing retrogradely through leak from left ventricle, Amplatz Gooseneck catheter snaring wire in right pulmonary vein

of paravalvular leak. There was a male preponderance of 66%. There were 13 procedures performed in 12 patients with aortic paravalvular leak (42%) and mitral paravalvular leak (58%). One patient (patient 7) underwent the procedure twice due to the significant residual leak. The patient demographics, the cardiac history and the clinical findings are summarized in Table 2. At the time of presentation, seven patients had symptoms of severe congestive heart failure (NYHA III-IV) and five had haemolytic anaemia requiring multiple transfusions.

Successful deployment was achieved in 100% of cases. The Amplatzer Vascular Plug III was used in 92% of the procedures, one patient required a Amplatzer Septal Occluder. Six patients (50%) need more than one device for total leak occlusion. Technical success was 92%. One patient (patient 7) underwent a second procedure after 49 days from the first.

Complications

Five patients required blood transfusion after the procedure due to hematoma or blood loss but all had an admission haemoglobin value <10 g/dl and previous recent multiple transfusions. Two patients had a transient worsening of the haemolytic anaemia and another had transient impairment of renal function.

Immediate and follow-up results

Immediate results after release of the device demonstrated a total

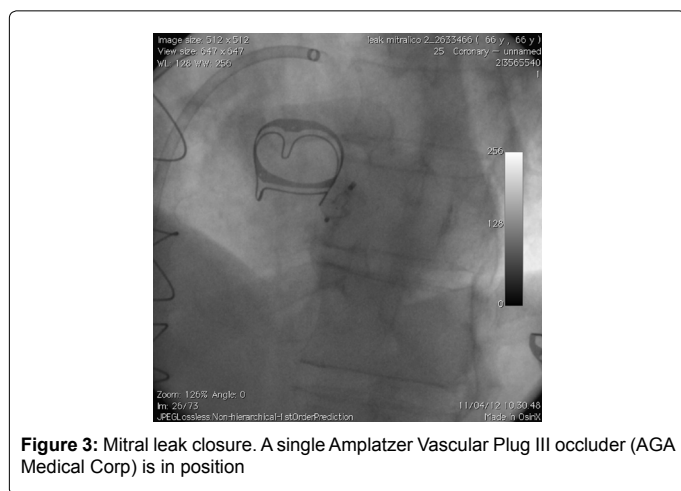


Figure 3: Mitral leak closure. A single Amplatzer Vascular Plug III occluder (AGA Medical Corp) is in position

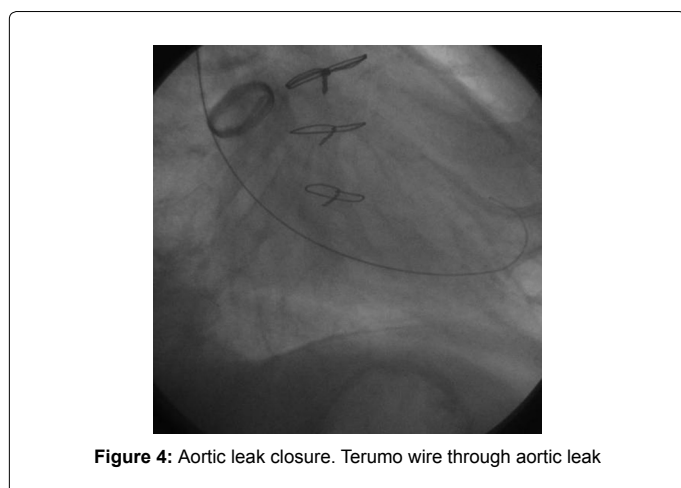


Figure 4: Aortic leak closure. Terumo wire through aortic leak

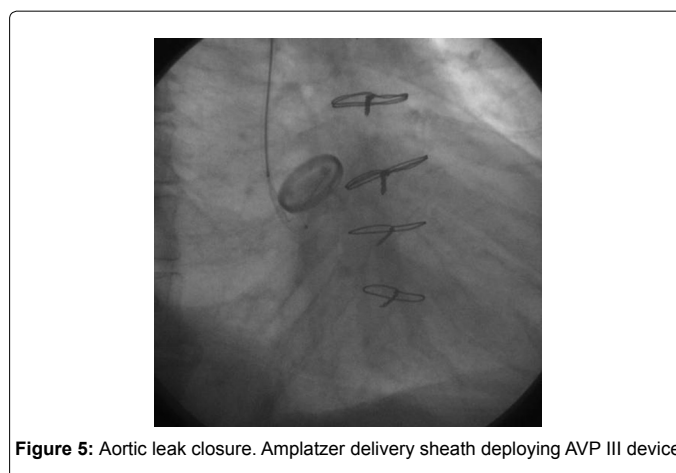


Figure 5: Aortic leak closure. Amplatzer delivery sheath deploying AVP III device

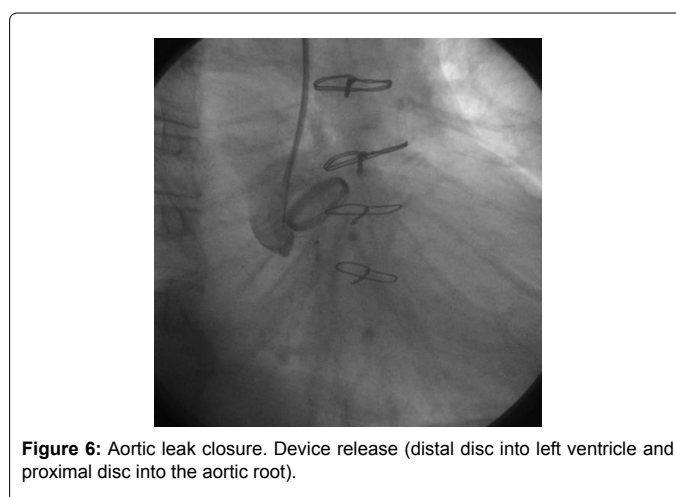


Figure 6: Aortic leak closure. Device release (distal disc into left ventricle and proximal disc into the aortic root).

defect occlusion in 6 patients and mild residual leak in 5 patients. During the follow-up period ranging from 3-20 months, seven patients have clinical improvement from New York Heart Association congestive heart failure class III-IV to class I-II and ten patients had a significantly decrease in transfusion requirement. Clinical success was achieved in 83% (10 of 12 patients). One intra-Hospital death occurs after fifteen days from procedure for non-cardiac causes. One patient, with persistent residual leak and recurrence haemolysis, underwent surgical repair after 12 months.

Discussion

Previous studies have shown that the therapeutic strategy influence the outcome either in patients with severe paravalvular leak than in patients with mild and moderate defects [9]. The aggressive surgical strategy improved survival and reduce symptoms even in patients with mild and moderate defects. However, surgical intervention carries an operative risk that varies from 6-22% [7,8] in the different series and a re-leak incidence of 22-35% [8]. These risks further increase in poor surgical candidates, like our patients, because of the complex surgical history and associated clinical condition. Percutaneous approaches to PVL closure have therefore been developed as a less-invasive strategy, and may be accomplished via transseptal access, apical left ventricular access, or retrograde arterial access. Since the first reports of the procedure in 1992, a number of series have been published, with

EuroSCORE		Patient														
		1	2	3	4	5	6	7	8	9	10	11	12			
Patient related risk factors																
	Age, > 65 years		x		x		x	x		x	x	x	x			
	Female (%)				x		x	x			x					
	Chronic pulmonary disease				x		x			x						
	Extracardiac arteriopathy															x
	Neurological dysfunction							x							x	
	Previous cardiac surgery	x	x	x	x	x	x	x	x	x	x	x	x	x	x	x
	Serum creatinine > 200 µmol/l								x			x				x
	Active endocarditis															
	Critical preoperative state	x														
Cardiac-related factors																
	Unstable angina															
	LV dysfunction: moderate or LVEF 30-50% poor or LVEF < 30%		x	x											x	
	Recent myocardial infarction (>90 days)															
	Pulmonary Hypertension	x	x		x			x	x	x	x	x	x			x
Operation-related risk factors																
	Emergency															
	Other than isolated CABG															
	Surgery on thoracic aorta															
	Postinfarct septal rupture															
Score		11	8	6	20	6	25	24	4	6	7	7	10			

Table 1: Application of the European scoring system for cardiac operative risk evaluation (EuroSCORE) to our population.

Patient	Age	Gender	Cardiovascular history	Acute problems	Pertinent medical history
1	58	M	Mitral valve replacement x 3	Perivalvular mitral leak; NYHA IV	Hemolysis, Heart failure
2	67	M	aortic valve replacement x 2	Perivalvular aortic leak; NYHA III	Endocarditisx1
3	64	M	Aortic valve replacement x 2 Mitral valve replacement x 2	Perivalvular mitral and aortic leak; NYHA IV; Haemolytic anemia	Re-surgical intervention post percutaneous procedure
4	77	F	Mitral valve replacement x 2	Perivalvular mitral leak; NYHA IV; Haemolytic anemia	Endocarditis x 1; Atrial Fibrillation COPD
5	62	M	aortic valve replacement x 1	Perivalvular aortic leak; NYHA IV; Haemolytic anemia	CABG, Atrial Fibrillation,PM
6	77	F	Aortic valve replacement x 1 Mitral valve replacement x 2	Perivalvular mitral leak; NYHA II	Mediastinitis, atrial fibrillation,COPD
7	83	F	Mitral valve replacement x 1	Perivalvular mitral leak; NYHA II	2 procedures; atral fibrillation; hemolitic anemia
8	54	M	Mitral valve replacement x 1;	Perivalvular mitral leak; NYHA IV; Haemolytic anemia	HCM; ASD occluder
9	66	M	Mitral valve replacement x 2;	Perivalvular mitral leak; NYHA IV;	COPD; atrial fibrillation
10	72	F	Mitral valve replacement x 1	Perivalvular mitral leak; NYHA II; Haemolytic anemia	Mediastinitis; Atrial fibrillation HCV
11	74	M	Aortic valve replacement x 1	Perivalvular aortic leak; Haemolytic anemia	
12	66	F	Mitral valve replacement x 1	Perivalvular mitral leak; Haemolytic anemia	Pulmonary Hypertension

Table 2: Clinical characteristics of the patients

encouraging rates of procedural success and good clinical outcomes. The largest experience of percutaneous PVL closure is derived from two centres, with 57 and 141 PVLs, respectively [14,16]. Reported technical success ranged from 77 to 86% and clinical success ranged from 67 to 77%, with a median follow-up of 11 months. In our centre, increased utilization of TEE 3-D has further improved the rates of technical (92%) and clinical success (83%), confirming the feasibility and safety of PVL closure with Amplatzer Vascular Plug III device. Therefore, the 30-day all cause mortality rate of 8% appears to be lower than that of 1 large surgical series (12%) [9]. One limitation of this technique is a steep learning curve, especially in mitral PVLs. The procedure is complex, time-consuming, and not always totally successful. The development

of newer low profile and largely adaptive devices that can conform to the variety of shapes of these defects and are specifically designed for this application will undoubtedly improve the current results. With regard to the safety of the procedure, the rate of severe complications is low, considering the severity of the disease treated and the often poor clinical condition of the patients.

Conclusions

We believe that the collaborative effort with a skilled interventional team, the cumulative experience of the operators, the use of hydrophilic catheters, 3-D echocardiographic guidance and the use of more user-friendly devices, can result in successful technical and clinical outcomes

with apparently lower morbidity and mortality rates in comparison to surgical series.

As reported in the last ESC Guidelines on the management of valvular heart disease transcatheter closure of PVL may be considered in selected patients in whom reintervention is deemed high risk or is contraindicated [30].

Conflict of Interest Disclosures Section

I have no conflicts to disclose.

References

- Jindani A, Neville EM, Venn G, Williams BT (1991) Paraprosthesis leak: a complication of cardiac valve replacement. *J Cardiovasc Surg (Torino)* 32: 503-508.
- Hammermeister K, Sethi GK, Henderson WG, Grover FL, Oprian C, et al. (2000) Outcomes 15 years after valve replacement with a mechanical versus a bioprosthetic valve: final report of the Veterans Affairs randomized trial. *J Am Coll Cardiol* 36: 1152-1158.
- Ionescu A, Fraser AG, Butchart EG (2003) Prevalence and clinical significance of incidental paraprosthesis valvar regurgitation: A prospective study using transoesophageal echocardiography. *Heart* 89: 1316 – 1321.
- Rallidis LS, Moysakakis IE, Ikonomidis I, Nihoyannopoulos P (1999) Natural history of early aortic paraprosthesis regurgitation: a five-year follow-up. *Am Heart J* 138: 351-357.
- Pate GE, Al Zubaidi A, Chandavimol M, Thompson CR, Munt BI, et al. (2006) Percutaneous closure of prosthetic paravalvular leaks: case series and review. *Catheter Cardiovasc Interv* 68: 528-533.
- Davila-Roman VG, Waggoner AD, Kennard ED, Holubkov R, Jamieson WR, et al. (2004) Prevalence and severity of paravalvular regurgitation in the artificial valve endocarditis reduction trial (avert) echocardiography study. *J Am Coll Cardiol* 44: 1467 – 1472.
- Echevarria JR, Bernal JM, Rabasa JM, Morales D, Revilla Y, et al. (1991) Reoperation for bioprosthetic valve dysfunction. A decade of clinical experience. *Eur J Cardiothorac Surg* 5: 523-526.
- Emery RW, Krogh CC, McAdams S, Emery AM, Holter AR (2010) Long-term follow up of patients undergoing reoperative surgery with aortic or mitral valve replacement using a St. Jude Medical prosthesis. *J Heart Valve Dis* 19: 473-484.
- Genoni M, Franzen D, Vogt P, Seifert B, Jenni R, et al. (2000) Paravalvular leakage after mitral valve replacement: improved long-term survival with aggressive surgery? *Eur J Cardiothorac Surg* 17: 14-19.
- Hourihan M, Perry SB, Mandell VS, Keane JF, Rome JJ, et al. (1992) Transcatheter umbrella closure of valvular and paravalvular leaks. *J Am Coll Cardiol* 20: 1371-1377.
- Moscucci M, Deeb GM, Bach D, Eagle KA, Williams DM (2001) Coil embolization of a periprosthetic mitral valve leak associated with severe hemolytic anemia. *Circulation* 104: E85-86.
- Eisenhauer AC, Piemonte TC, Watson PS (2001) Closure of prosthetic paravalvular mitral regurgitation with the Gianturco-Grifka vascular occlusion device. *Catheter Cardiovasc Interv* 54: 234-238.
- Moore JD, Lashus AG, Prieto LR, Drummond-Webb J, Latson LA (2000) Transcatheter coil occlusion of perivalvular mitral leaks associated with severe hemolysis. *Catheter Cardiovasc Interv* 49: 64-67.
- Alonso-Briales JH, Munoz-Garcia AJ, Jimenez-Navarro MF, Dominguez-Franco AJ, Melero-Tejedor JM, et al. (2009) Closure of perivalvular leaks using an amplatzer occluder. *Rev Esp Cardiol* 62: 442-446.
- Cortes M, Garcia E, Garcia-Fernandez MA, Gomez JJ, Perez-David E, et al. (2008) Usefulness of transesophageal echocardiography in percutaneous transcatheter repairs of paravalvular mitral regurgitation. *Am J Cardiol* 101: 382-386.
- Garcia-Borbolla Fernandez R, Sancho Jaldon M, Calle Perez G, Gomez Menchero AE, de Zayas Rueda R, et al. (2009) Percutaneous treatment of mitral valve periprosthetic leakage. An alternative to high-risk surgery? *Rev Esp Cardiol* 62: 438-441.
- Hein R, Wunderlich N, Robertson G, Wilson N, Sievert H (2006) Catheter closure of paravalvular leak. *EuroIntervention* 2: 318-325.
- Nietlispach F, Johnson M, Moss RR, Wijesinghe N, Gurchich R, et al. (2010) Transcatheter closure of paravalvular defects using a purpose-specific occluder. *JACC Cardiovasc Interv* 3: 759-765.
- Shapira Y, Hirsch R, Kornowski R, Hasdai D, Assali A, et al. (2007) Percutaneous closure of perivalvular leaks with Amplatzer occluders: feasibility, safety, and short-term results. *J Heart Valve Dis* 16: 305-313.
- Nashef SAM, Roques F, Michel P, Gauducheau E, Lemeshow S, et al. (1999) European system for cardiac operative risk evaluation (EuroSCORE). *Eur J Cardiothorac Surg* 16: 9-13.
- Moneta A, Villa E, Donatelli F (2003) An alternative technique for non-infective paraprosthesis leakage repair. *Eur J Cardiothorac Surg* 23: 1074-1075.
- Rihal CS, Sorajja P, Booker JD, Hagler DJ, Cabalka AK (2012) Principles of percutaneous paravalvular leak closure. *JACC Cardiovasc Interv* 5: 121-130.
- Sorajja P, Cabalka AK, Hagler DJ, Rihal CS (2011) Long-term follow-up of percutaneous repair of paravalvular prosthetic regurgitation. *J Am Coll Cardiol* 58: 2218-2224.
- Kim MS, Casserly IP, Garcia JA, Klein AJ, Salcedo EE, et al. (2009) Percutaneous transcatheter closure of prosthetic mitral paravalvular leaks: are we there yet? *JACC Cardiovasc Interv* 2: 81-90.
- Ruiz CE, Jelmin V, Kronzon I, Dudiy Y, Del Valle-Fernandez R, Einhorn BN, et al. (2011) Clinical outcomes in patients undergoing percutaneous closure of periprosthetic paravalvular leaks. *J Am Coll Cardiol* 58: 2210-2217.
- García E, Sandoval J, Unzué L, Hernández-Antolín R, Almería C, et al. (2012) Paravalvular leaks: mechanisms, diagnosis and management. *EuroIntervention* 8: Q41-Q52.
- Kliger C, Eiros R, Isasti G, Einhorn B, Jelmin V, et al. (2013) Review of surgical prosthetic paravalvular leaks: diagnosis and catheter-based closure. *Eur Heart J* 34: 638-649.
- Sorajja P, Cabalka AK, Hagler DJ, Rihal CS (2011) Percutaneous repair of paravalvular prosthetic regurgitation: acute and 30-day outcomes in 115 patients. *Circ Cardiovasc Interv* 4: 314-321.
- Skoularigis J, Essop MR, Skudicky D, Middlemost SJ, Sareli P (1993) Frequency and severity of intravascular hemolysis after left-sided cardiac valve replacement with Medtronic hall and St. Jude medical prostheses, and influence of prosthetic type, position, size and number. *Am J Cardiol* 71: 587-591.
- Joint Task Force on the Management of Valvular Heart Disease of the European Society of Cardiology (ESC); European Association for Cardio-Thoracic Surgery (EACTS), Vahanian A, Alfieri O, Andreotti F, et al. (2012) Guidelines on the management of valvular heart disease (version 2012). *Eur Heart J* 33: 2451-2496.

This article was originally published in a special issue, [Valvular Heart Diseases](#) handled by Editor(s), Dr. Peter A. McCullough, St. John Providence Health System, USA; Dr. Yasmin S. Hamirani, University of New Mexico, USA