

# Percutaneous Aspiration Embolectomy in the Treatment of Acute Arterial Embolic Infrainguinal Vascular Occlusion

Schleder S<sup>1\*</sup>, Diekmann M<sup>2</sup>, Manke C<sup>3</sup> and Heiss P<sup>1</sup>

<sup>1</sup>Department of Radiology, University Medical Center Regensburg, Germany

<sup>2</sup>Radiology Center Rahlstedt, Rathenaustr. 182, 22337 Hamburg, Germany

<sup>3</sup>Department of Radiology, General Hospital Fulda, Pacelliallee 4, 36043 Fulda, Germany

\*Corresponding author: Schleder S, Department of Radiology, University Medical Center Regensburg, Franz-Josef-Strauss-Allee 11, 93053 Regensburg, Germany, Tel: +49 176 20103644, +49 941 944 7442; E-mail: [stephan.schleder@ukr.de](mailto:stephan.schleder@ukr.de)

Received date: May 10, 2017; Accepted date: May 16, 2017; Published date: May 20, 2017

Copyright: © 2017 Schleder S, et al. This is an open-access article distributed under the terms of the Creative Commons Attribution License, which permits unrestricted use, distribution, and reproduction in any medium, provided the original author and source are credited.

## Abstract

**Background:** Since its introduction, percutaneous aspiration embolectomy (PAE) has become a well-known, widely accepted and frequently applied technique for the treatment of acute arterial embolic infrainguinal vascular occlusion in lower limb ischemia.

**Purpose:** To evaluate the technical and clinical success of sole percutaneous aspiration embolectomy (PAE) for the treatment of acute arterial embolic infrainguinal vascular occlusion.

**Material and Methods:** During a period of 7 years, 50 patients (24 female, 48%) with a mean age of 73 (range 53–95) years were identified in whom 54 cases of PAE were performed for the treatment of arterial embolic infrainguinal vascular occlusion. Primary technical success was defined as residual stenosis of <50% in diameter after sole PAE, secondary technical success was defined as residual stenosis of <50% in diameter after PAE and additional percutaneous transluminal angioplasty (PTA) and/or stenting. Clinical outcome parameters (e.g. need for further intervention and/or amputation) were evaluated for the 30-day postinterventional period.

**Results:** The primary technical success rate was 85% (46 of 54 cases). The secondary technical success rate was 96% (52 of 54 cases). Clinical outcome data were achievable in 50 of the 54 cases (93%). In 43 of the 50 patients (86%) there was no need for further intervention within the 30-day postinterventional period. In summary, during this 30-day postinterventional period after PAE amputation was carried out or death occurred in 5 of 50 patients (10%).

**Conclusion:** Minimally invasive PAE is an effective and safe technique for the treatment of acute arterial embolic infrainguinal vascular occlusion.

**Keywords:** Interventional-Vascular; Percutaneous; Angioplasty; Arteries; Vascular

## Introduction

Arterial embolism results when a clot of blood migrates through vessels, ultimately getting stuck in a distal artery where blood flow is obstructed. This obstruction may lead to ischemia, organ failure and potential infarction. Complications of arterial embolism are multiple and a leading cause of disability and death in developed countries. Manifestations of this complex disease include medical and surgical emergencies such as stroke, acute upper or lower limb ischemia as well as mesenteric ischemia or renal failure. Despite today's advances in diagnosis and management, arterial embolic disease still poses a challenge to clinicians of different specializations, while contributing greatly to morbidity and mortality [1,2].

Upper and especially lower limb ischemia is one of the most frequent causes of morbidity and mortality from arterial embolic disease. Although the incidence of peripheral arterial embolism has nowadays decreased due to the wider use of anticoagulation it is still a

considerable cause of morbidity, mortality and hospitalization in developed countries. Emboli to the lower extremities occur approximately four times as often as emboli to the upper extremities [1,3].

Since its introduction, percutaneous aspiration embolectomy (PAE) has become a well-known, widely accepted and frequently applied technique for the treatment of acute arterial embolic infrainguinal vascular occlusion in lower limb ischemia [4]. Though the technique is applied for more than 30 years there are limited data on the technical and clinical success rate and the rate of complications for this kind of treatment [5-7].

The purpose of the present survey was to report the single-center experience of a municipal academic teaching hospital on the technical and clinical success of PAE for the treatment of acute arterial embolic infrainguinal vascular occlusion.

## Material and Methods

### Patients

The Independent Ethics Committee of our institution confirmed, that for this scientific project no ethics-approval or commission's opinion was necessary due to the fact, that according to our applicable laws and guidelines such retrospective study without any study-related clinical intervention or use of patients' personal data does not have to be submitted to the ethics committee.

In a period of seven years all patients undergoing infrainguinal arterial PAE at a municipal academic teaching hospital were retrospectively identified using the institutional radiologic information system searching for the key words "percutaneous aspiration thromboembolism (PAT)", "percutaneous aspiration embolectomy (PAE)", "aspiration", "thrombectomy" and "embolectomy". Review of all identified patients was performed in detail by two radiologists with more than two and ten years of experience in interventional radiology. As reported before [7] 176 acute infrainguinal arterial occlusions had been treated with PAT/PAE in 158 patients in the mentioned time period. The mean age of these 158 patients (61 female, 39%) was 73 years (with an age range from 39 to 96 years). Most important comorbidities were arterial hypertension, diabetes mellitus, atrial fibrillation, arterial occlusive disease, chronic renal failure, coronary heart disease, nicotine abuse and a history of stroke in 56% (89 patients), 34% (54 patients), 33% (53 patients), 28% (44 patients), 22% (34 patients), 21% (33 patients), 15% (23 patients), and 13% (21 patients), respectively. The recognized cause of acute arterial occlusion was arterial embolism, arterial thrombosis, thromboembolism in line with infrainguinal percutaneous transluminal angioplasty (PTA), and thromboembolism in line with percutaneous thrombolysis in 30% (54 cases), 23% (40 cases), 27% (47 cases), and 20% (35 cases), respectively. The findings of the 47 cases with thromboembolism in line with infrainguinal PTA have been published before in detail elsewhere [7].

In the present survey, the basic disease, the technique of PAE as well as the technical success rate and the clinical outcome of the subgroup of 54 cases in 50 patients with acute arterial embolic infrainguinal vascular occlusion are outlined (two patients had distinct events and 2 patients had bilateral disease treated simultaneously).

### Percutaneous aspiration embolectomy

In patients in whom PAE was considered indicated, a 6 or 8 French sheath (e.g. Terumo, Leuven, Belgium or Cordis, Bridgewater NJ, USA) was inserted antegrade into the common femoral artery in Seldinger technique. The size of the sheath was adjusted to the size of the occluded artery, e.g. for aspiration of emboli within arteries below the knee usually a 4 to 6 French sheath was sufficient. A hydrophilic 0.035 inch guidewire (Terumo, Leuven, Belgium) was carefully progressed past the embolus; if passing was not possible, the guidewire was maneuvered into the embolus. According to the diameter of the occluded artery, 4 to 8 French aspiration catheters (Angiomed, Karlsruhe, Germany) were inserted for PAE. With the wire in place, the tip of the aspiration catheter was passed into or – if possible – through the embolus. The guidewire was removed. Using a 20 or 50 mL syringe aspiration was applied manually to the catheter simultaneous with slow catheter withdrawal, thus achieving aspiration of the embolus. No mechanical or chemical thrombolysis was employed. Typically, several passes of aspiration were performed to achieve complete clot removal.

Completion digital subtraction angiography was carried out to assess the final result. Postinterventional the patients were given 75 mg per day Clopidogrel (Plavix®, Sanofi Pharma Bristol-Myers Squibb SNC, Paris, France) for 4 weeks and 100 mg per day aspirin for lifetime, those suffering from atrial fibrillation were given the anti-coagulant Marcumar if possible.

### Technical success and clinical outcome

Primary technical success was defined as residual stenosis of less than 50% in diameter after solitary PAE. Secondary technical success was defined as residual stenosis of less than 50% in diameter after PAE and additional percutaneous transluminal angioplasty (PTA) and/or stenting. Clinical outcome including need for further intervention and/or amputation was evaluated for the 30 day postinterventional period.

## Results

### Patients

Mean age of these 50 patients (24 female, 48%) was 73 years (age range 53 to 95 years). Atrial fibrillation, arterial hypertension, nicotine abuse, chronic renal failure, diabetes mellitus, coronary heart disease, history of stroke and arterial occlusive disease and were present in 62% (31 patients), 46% (23 patients), 32% (16 patients), 30% (15 patients), 22% (11 patients), 12% (6 patients), 6% (3 patients), and 4% (2 patients), respectively (Table 1).

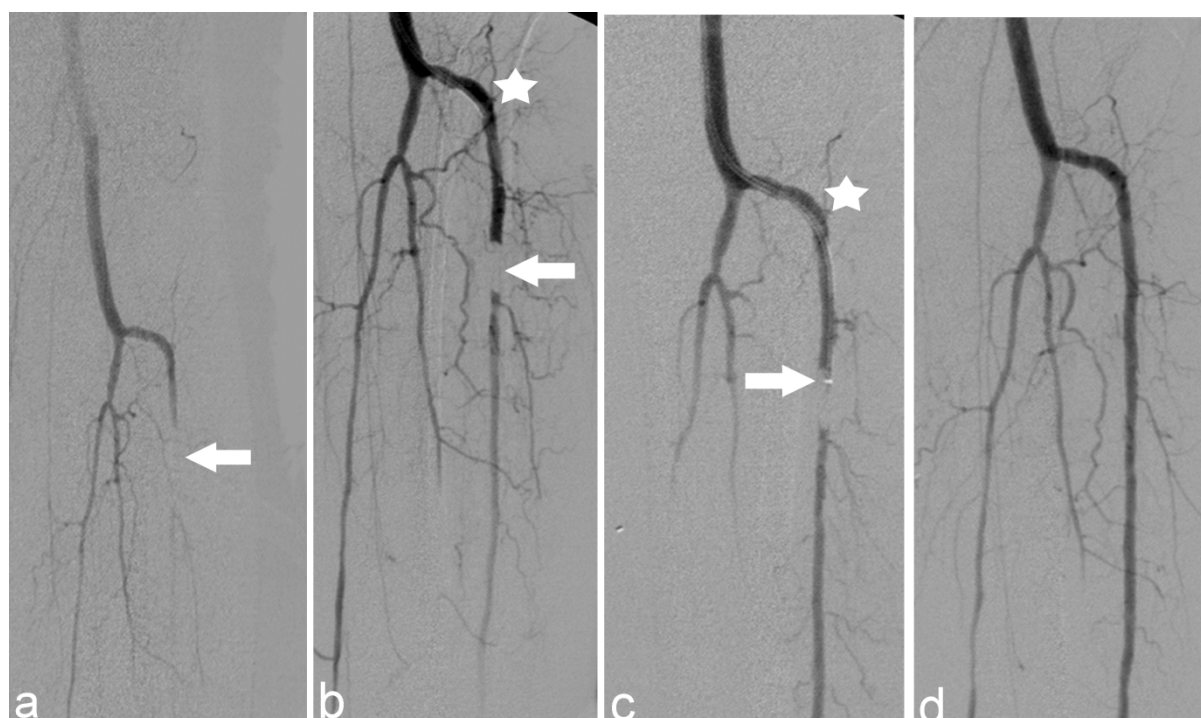
Comorbidities	Number of patients	Percentage
atrial fibrillation	31 patients	62%
arterial hypertension	23 patients	46%
nicotine abuse	16 patients	32%
chronic renal failure	15 patients	30%
diabetes mellitus	11 patients	22%
coronary heart disease	6 patients	12%
history of stroke	3 patients	6%
arterial occlusive disease	2 patients	4%

**Table 1:** Comorbidities of the 50 patients treated with percutaneous aspiration embolectomy for acute arterial embolic infrainguinal vascular occlusion.

### Technical success of percutaneous aspiration embolectomy

The emboli were located within the superficial femoral artery, the popliteal artery and below-the-knee in 30% (16 of 54 cases), 40% (22 of 54 cases), 30% (16 of 54 cases), respectively. Median length of the embolic arterial occlusion was 2 cm (range 0.5 to 15 cm). PAE was carried out by 3 interventional radiologists with 2, 5 and 10 years of experience in interventional angiography. Median duration of sole PAE was 25 minutes (range 12 to 75 minutes).

The primary technical success rate was 85% (46 of 54 cases). The secondary technical success rate was 96% (52 of 54 cases), which is illustrated by Figure 1.



**Figure 1:** 1a: A fifty two-year-old male patient with coronary heart disease and diabetes mellitus was administered to angiography for acute ischemia of the left forefoot. Digital subtraction angiography of the left leg depicted an embolic occlusion of the anterior tibial artery (ATA, white arrow). Dear ladies and gentlemen, 1b: Percutaneous aspiration embolectomy (PAE) of the approximately 1.5 cm long vessel occlusion (white arrow) was considered, therefore a 4 French (F) guiding catheter was inserted into the proximal ATA (white star). 1c: The 4 F guiding catheter was replaced by a 4 F aspiration catheter (white star) and its tip was inserted into the proximal part of the embolus (white arrow) and PAE was performed. 1d: Control digital subtraction angiography after PAE of the ATA identified a patent vessel segment and the intervention was terminated successfully.

In two cases secondary technical success could not be achieved by PAE combined with PTA and/or stenting. In the first case an embolus within the tibiofibular trunk was removed by sole PAE. Control angiography showed acute thrombosis of the treated vessel segment, which could not be solved. Intra-arterial lysis therapy was indicated and carried out. Control angiography the next day proved complete patency of the treated artery occlusion and the patient could be released soon afterwards without the need for further intervention.

In the second case in which technical success could not be achieved an acute 15 cm long embolic occlusion of the superficial femoral artery was depicted. Though the embolus was rather long for PAE, primary PAE was indicated due to a lack of capacity in vascular surgery at the time the patient presented at the clinic. The length of the embolus could be reduced to 2 cm by PAE and the residual embolus was completely surgically removed the day after. The patient passed away 18 days after the intervention due to myocardial infarction.

### Clinical outcome

Clinical outcome data for the 30 day post interventional period were achievable in all 50 patients. In 86% (43 of 50 patients) there was no need for further radiologic or surgical intervention or amputation. In 10% (5 of 50 patients) further intervention was carried out: in three patients amputations had to be conducted (1 × above-knee, 1 × below-knee, 1 × forefoot), due to non salvageable limb tissue damage and not

because of incomplete revascularization. In two further patients the source of emboli was surgically deactivated (1 × partially thrombosed popliteal aneurysm, 1 × partially thrombosed aortic aneurysm). Another 4% (2 of 50 patients) passed away because of myocardial infarction on day 2 and 18 after PAE. In summary, during the 30 day postinterventional period after PAE amputation was carried out or death occurred in 10% (5 of 50 patients).

### Discussion

The results of the present study confirm the benefit and advantages of PAE for the treatment of acute arterial embolic infrainguinal vascular occlusion: 1) PAE can be safely performed with a very high effectiveness. In particular, in the present survey there were no complications like residual peripheral emboli, arterial dissection, bleeding and/or infection. 2) In our experience PAE can be easily learned and is relatively easy to perform. 3) PAE is a minimally invasive procedure which is relevant since many patients with embolic infrainguinal vascular occlusion are of advance age, exhibit several comorbidities and/or are in a reduced general condition. 4) PAE is cost-effective. The costs for the material required for PAE are about 100 Euro.

Major disadvantages of PAE are risk of arterial dissection or bleeding at the puncture site, in particular, when large bore sheaths and large bore catheters are used. In addition, PAE maneuvers can

induce migration of emboli into distal vessel segments and in patients with vast embolus burden and subsequent long-segment vessel occlusion PAE possibly cannot be performed successfully. But, as shown in this survey, overall the complication rate of PAE is low and PAE can be performed successfully in most patients. Wagner et al. reported on PAE for the treatment of acute arterial embolic infrainguinal vascular occlusion in 85 patients [5]. Clinical success was achieved in 77 of 90 limbs (86%). However, eight groin hematomas and two pseudoaneurysm of the puncture site occurred. The higher rate of these complications compared to the complication rate of the present study are presumably related to the fact, that in the study population of Wagner et al. fibrinolysis (urokinase) was administered in 74 of 104 interventions, which was not the case in our population.

Limitations for this study to be mentioned are 1) the retrospective nature of the study, and 2) the relatively low number of patients included (54 cases in 50 patients of which two patients had distinct events and 2 patients had bilateral disease treated simultaneously). Nevertheless, to the best of our knowledge, this survey is the first study evaluating the role of sole PAE for the treatment of acute arterial embolic infrainguinal vascular occlusion.

## Conclusion

In conclusion, PAE for the treatment of acute arterial embolic infrainguinal vascular occlusion can be performed as a minimally invasive therapeutic procedure with a high technical success and a low complication rate leading to a satisfying clinical outcome. Hence, PAE

should be considered as primary approach for the treatment of acute arterial embolic infrainguinal vascular occlusion.

## References

1. Lyaker MR, Tulman DB, Dimitrova GT (2013) Arterial embolism. *Int J Crit Illn Inj Sci* 3:77-87.
2. Clagett GP, Sobel M, Jackson MR, Lip GY, Tangelder M, et al. (2004) Antithrombotic therapy in peripheral arterial occlusive disease: The Seventh ACCP Conference on Antithrombotic and Thrombolytic Therapy. *Chest*: 609S-626S.
3. Tawes RL Jr, Harris EJ, Brown WH, Shoor PM, Zimmerman JJ, et al. (1985) Arterial thromboembolism. A 20-year perspective. *Arch Surg* 120: 595-599.
4. Wagner HJ, Starck EE (1992) Acute embolic occlusions of the infrainguinal arteries: percutaneous aspiration embolectomy in 102 patients. *Radiology* 182: 403-407.
5. Wagner HJ, Starck EE, Reuter P (1994) Long-term results of percutaneous aspiration embolectomy. *Cardiovasc Intervent Radiol* 17: 241-246.
6. Kim SK, Kwak HS, Chung GH (2011) Acute upper limb ischemia due to cardiac origin thromboembolism: the usefulness of percutaneous aspiration thromboembolectomy *via* a transbrachial approach. *Korean J Radiol* 12: 595-601.
7. Schleder S, Diekmann M, Mahnke C, Heiss P (2015) Percutaneous aspiration thrombectomy for the treatment of arterial thromboembolic occlusions following percutaneous transluminal angioplasty. *Cardiovasc Intervent Radiol* 38: 60-64.