

Paraneoplastic Pemphigus: An Unusual Neoplasm Association

Parviz Toosi¹, Zahra Asadi Kani², Mehdi Qeisari² and Nastaran Namazi^{3*}

¹Professor of dermatology, Skin research center, Shohad-e-Tajrish hospital, Shahid Beheshti university of medical science, Tehran, Iran

²Dermatopathologist, Skin research center, Shohad-e-Tajrish hospital, Shahid Beheshti university of medical science, Tehran, Iran

³Resident of dermatology, Skin research center, Shohad-e-Tajrish hospital, Shahid Beheshti university of medical science, Tehran, Iran

Abstract

The occurrence of paraneoplastic pemphigus (PNP) in childhood has been reported infrequently. Association with benign mesentery tumors has not been reported in these patients before. Here, we report an unusual case of PNP in a child that was concomitant with benign mesentery fibroma and responded to medical treatment only after surgical excision of tumor.

Keywords: Paraneoplastic pemphigus; Neoplasm association; Benign tumor; Mesentery fibroma

Introduction

PNP, described by Anhalt et al. in 1990, is an IgG-mediated disease, characterized clinically by polymorphous eruption with prominent mucosal and acral involvement in the presence of a known or occult neoplasm. The clinical features overlap with erythema multiforme and lichen planus pemphigoides. Patients have severe mucosal erosions and polymorphous cutaneous signs including blisters, erosions, particularly on the upper body, and acral lesions. Mucosal lesions are typically present in the oral cavity, and also frequently found in the eye, anogenital region, upper digestive and respiratory tracts [1-3].

The occurrence of PNP in childhood has been reported infrequently. Unlike adult cases of PNP, where non-Hodgkin's lymphoma is the most commonly associated neoplasm, in children and adolescents this disease has a striking association with Castleman's disease.

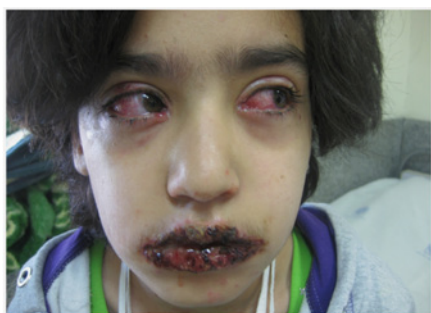

Figure 1: Perioral lesions, hemorrhagic crust on the lips and bilateral conjunctivitis.

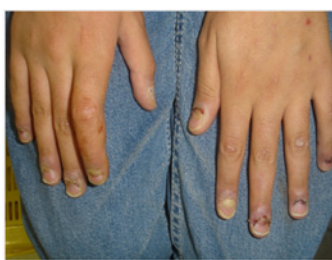

Figure 2: Periungual erosions and scaling.

Here we report an unusual case of childhood paraneoplastic pemphigus in association with benign mesocolon fibroma that responded to tumor excision dramatically.

Case Report

A 12 year old girl was referred to our dermatology clinic because of painful mucosal erosions from one month ago, made her unable to eat and drink. Genital mucosa was involved thereafter leading to dysuria. At the same time she experienced conjunctivitis. Also, she had mild dyspnea. The past medical history was unremarkable and there was no drug history. In the examination, she had widespread mucosal erosions in the oral and nasal mucosa with crust formation on the lips. She had vaginal, anal and conjunctival erosions (Figure 1 and Figure 2). There were periungual scaling and erythema in the upper and lower extremities. She had few bullae on the fingers and toes. Other physical examinations were normal except tenderness in lower abdominal area and non tender palpable lymph nodes in cervical region. Routine laboratory tests including cell blood count, liver function test, renal function and blood biochemistry were in normal limits. Abdominal sonography detected a solid pelvic mass that was confirmed in MRI as solid encapsulated tumoral lesion with marked heterogeneous enhancement suggestive of teratoma, dysgerminoma or neurogenic tumor. Stevensen-Johnson, viral infection and pemphigus vulgaris were suspected. Skin biopsy and direct immunofluorescence was performed that were suggestive of paraneoplastic pemphigus and no finding was found in favor of others. (Figure 3-6) Serologic tests for specific autoantigens were not performed.

Tumor markers were in normal range except CEA that was slightly raised. CT scan of thorax, abdomen and pelvis (other than the pelvic mass) was normal and oncologist did not find another source of malignant neoplasm. She was prescribed 30mg/day prednisolone and 50 mg/day azathioprine but she had poor response to treatment. The tumor was resected with gynecologist and surgeon consultations.

***Corresponding author:** Nastaran Namazi, Resident of dermatology, Skin research center, Shohad-e-Tajrish hospital, Shahid Beheshti university of medical science, Tehran, Iran, Tel: +9821222741507; Fax: +9821222741512; E-mail: nastarran22@yahoo.com

Received February 02, 2011; **Accepted** July 09, 2011; **Published** July 15, 2011

Citation: Toosi P, Kani ZA, Qeisari M, Namazi N (2011) Paraneoplastic Pemphigus: An Unusual Neoplasm Association. J Clin Exp Dermatol Res 2:124. doi:10.4172/2155-9554.1000124

Copyright: © 2011 Toosi P, et al. This is an open-access article distributed under the terms of the Creative Commons Attribution License, which permits unrestricted use, distribution, and reproduction in any medium, provided the original author and source are credited.

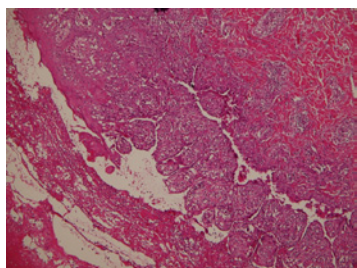


Figure 3: Over view, H & E, Widespread acantholysis and lichenoid reaction in dermoepidermal junction.

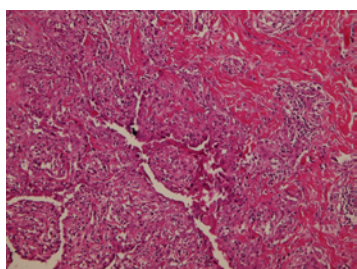


Figure 4: H & E, Acantholytic cells and infiltration in dermoepidermal junction.

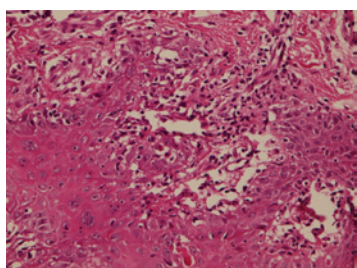


Figure 5: Hydropic degeneration of basal layer and dyskeratotic cells in dermoepidermal junction.

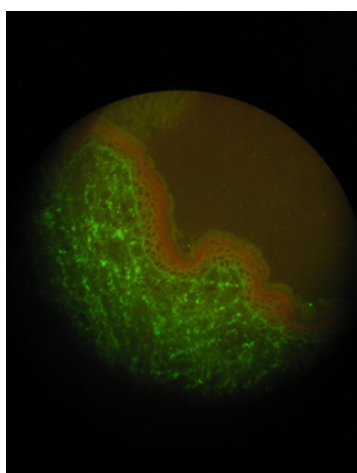


Figure 6: DIF, Focal intercellular suprabasal deposition and linear deposition along dermoepidermal junction (IgG & C3).

Histopathologic examination of tumor was consistent with mesocolon inflammatory fibroma and all the malignant markers were negative in immunohistochemistry. The mucocutaneous lesions were improved

significantly and no relapse or presentation of other malignancy was detected in 12 months follow up. Although acral lesion partially resolved, the response was not as good as mucosal lesion and chronic lichenoid dermatitis persisted over dorsal aspect of the hands.

Discussion

In PNP histology may show a range of features, including epidermal acantholysis, dyskeratosis with basal vacuolar changes, keratinocyte necrosis and exocytosis of inflammatory cells into the epidermis [1-4]. Immunofluorescence reveals typical binding of both IgG and C3 in a focal, intercellular epidermal pattern and linear granular pattern at the basement membrane zone. Immunoprecipitation and immunoblotting reveal several characteristic target antigens of molecular weights 250, 230, 210, 190 and 170 kDa corresponding to desmoplakin, the 230-kDa bullous pemphigoid (BP) antigen BP230, envoplakin, periplakin and transmembrane protein [5-9]. In addition, a pathogenic role has also been suggested for antidesmoglein (Dsg) antibodies [10].

The most commonly associated neoplasms are non-Hodgkin lymphoma (40%), chronic lymphocytic leukemia (30%), Castleman's disease (10%), malignant and benign thymomas (6%), sarcomas (6%) and Waldenstrom's macroglobulinemia (6%) [2,11]. There are reports of carcinomas of the lung, colon, hepatocellular, pancreas, and cervix [12-14]. In one case no underlying neoplasm was found over 8 years of follow-up [15]. The absence of common neoplasms is notable. Other triggers are radiotherapy, treatment with fludarabine and interferon- α [16,17].

In approximately one-third of patients, the underlying neoplasm is undiagnosed at the time the mucocutaneous disease develops. Patients with benign tumors, such as thymoma or localized Castleman's disease, should have the tumor surgically excised. The majority of these patients will either improve substantially or clear completely. However, it may take 6-18 months to see complete resolution of lesions after excision of a benign neoplasm [18].

PNP affects children and adolescents aged 8-18 years with no gender preference. Hispanic children appear to be more frequently affected. The key features of childhood and adolescent PNP are severe mucositis, specific association with B-cell lymphoproliferative disease, frequent respiratory involvement and a high fatality rate [19]. Castleman's disease is a rare lymphoproliferative disorder, characterized by a massive growth of lymphoid tissue, usually located in the mediastinum or retroperitoneum and is the most common neoplasm in children with PNP [20-22].

A case of PNP with lesions in the colon epithelium was reported in 2006 by Hiroshi MIIDA et.al. Levels of tumor markers CEA and CA19-9 were elevated, abdominal CT and MRI revealed thick mesentery that was not further investigated due to intervening complications. The biopsy specimen from the colon had similar histology to that associated with PNP [23]. We did not perform colonoscopy to assess colon epithelium. Association of PNP has been reported with inflammatory myofibroblastic tumors. They are typically composed of variable amounts of stromal and cellular elements, and are benign tumor-like lesions of unknown etiology that can occur at different anatomic sites and have variable non-specific clinical symptoms. Although myofibroblasts were not detected in histopathologic examination, it is possible that our case would be associated with these tumors [24].

With few exceptions, PNP in patients with malignant neoplasms has generally proved to be fatal, with no relation between the course of the mucocutaneous syndrome and tumour activity. Mortality is frequently the result of a complication of immunosuppression

[24] or gastrointestinal bleeding due to high dose of corticosteroids. Bronchiolitis obliterans frequently leads to respiratory failure and is the third cause of death in PNP [25]. Mean survival rate of the original group of cases reported by Anhalt was 9 months (with a maximum of 24 months).

Our case demonstrated an unusual one, firstly because of unique tumor association, secondly for a childhood PNP, that is rare and usually in the context of castleman's disease. Moreover, our case had good response to treatment although she had mild respiratory symptoms in favor of bronchiolitis obliterans. Although we did not perform serologic tests in this patient, clinical, histological and direct immunofluorescence findings were consistent with the diagnosis of PNP and the lesions improved significantly after resection of tumor.

Although our patient's lesions responded dramatically to tumor resection, we will follow the patient for possible existence of other proliferative diseases.

Acknowledgment

This project was funded by the Skin Research Centre, Shahid Beheshti University, M.C., Shohada-e-Tajrish Hospital. Nastaran Namazi had full access to all the data in this report and takes responsibility for the integrity of the data. Authors declare no financial interest in this manuscript and no affiliation (relationships) to disclose.

References

- Anhalt GJ, Kim S-C, Stanley JR, Korman NJ, Jabs DA, et al. (1990) Paraneoplastic pemphigus. An autoimmune mucocutaneous disease associated with neoplasia. *N Engl J Med* 323: 1729-1735.
- Mutasim DF, Pelc NJ, Anhalt GJ (1993) Paraneoplastic pemphigus. *Dermatol Clin* 11: 473-481.
- Anhalt GJ (1997) Paraneoplastic pemphigus. *Adv Dermatol* 12: 77-96.
- Mehregan DR, Oursler JR, Leiferman KM, Muller SA, Anhalt GJ, et al. (1993) Paraneoplastic pemphigus: a subset of patients with pemphigus and neoplasia. *J Cutan Pathol* 20: 203-210.
- Hashimoto T, Amagai M, Watanabe K, Chorzelski TP, Bhogal BS, et al. (1995) Characterization of paraneoplastic pemphigus autoantigens by immunoblot analysis. *J Invest Dermatol* 104: 829-834.
- Kim S-C, Kwon YD, Lee IJ, Chang SN, Lee TG (1997) cDNA cloning of the paraneoplastic pemphigus antigen reveals that envoplakin is a component of the antigen complex. *J Invest Dermatol* 109: 365-369.
- Mahoney MG, Aho S, Uitto J, Stanley JR (1998) The members of the plakin family of proteins recognized by paraneoplastic pemphigus antibodies include periplakin. *J Invest Dermatol* 111: 308-313.
- Borradori L, Trueb RM, Jaunin F, Limat A, Favre B, et al. (1998) Autoantibodies from a patient with paraneoplastic pemphigus bind periplakin, a novel member of the plakin family. *J Invest Dermatol* 111: 338-340.
- Kiyokawa C, Ruhrberg C, Nie Z, Karashima T, Mori O, et al. (1998) Envoplakin and periplakin are components of the paraneoplastic pemphigus antigen complex. *J Invest Dermatol* 111: 1236-1238.
- Amagai M, Nishikawa T, Nousari HC, Anhalt GJ, Hashimoto T (1998) Antibodies against desmoglein 3 (pemphigus vulgaris antigen) are present in sera from patients with paraneoplastic pemphigus and cause acantholysis in vivo in neonatal mice. *J Clin Invest* 102: 775-782.
- Anhalt GJ (2004) Para neoplastic pemphigus. *J Invest Dermatol Symp Proc* 9: 29-33.
- Matz H, Milner Y, Frusic-Zlotkin M, Brenner S (1997) Paraneoplastic pemphigus associated with pancreatic carcinoma. *Acta Derm Venereol* 77: 289-291.
- Niimi Y, Kawana S, Hashimoto T, Kusunoki T (2003) Paraneoplastic pemphigus associated with uterine carcinoma. *J Am Acad Dermatol* 48: S69-72.
- Hinterhauer G, Drach J, Riedl E, Böhler K, Ferenci P, et al. (2003) Paraneoplastic pemphigus in association with hepatocellular carcinoma. *J Am Acad Dermatol* 49: 538-540.
- Park GI, Lee JH, Yun SJ, Lee SC, Lee JB (2007) Paraneoplastic pemphigus without an underlying neoplasm. *Br J Dermatol* 156: 563-566.
- Kirsner RS, Anhalt GJ, Kerdel FA (1995) Treatment with alpha interferon associated with the development of paraneoplastic pemphigus. *Br J Dermatol* 132: 474-478.
- Gooptu C, Littlewood TJ, Frith P, Lyon CC, Carmichael AJ, et al (2001) Paraneoplastic pemphigus: an association with fludarabine? *Br J Dermatol* 144: 1255-1261.
- Jean L Bolognia, Joseph L Jorizzo, Ronald P Rapini, *Dermatology*, Second edition.
- Mimouni D, Anhalt GJ, Lazarova Z, Aho S, Kazerounian S, et al. (2002) Paraneoplastic pemphigus in children and adolescents. *Br J Dermatol* 147: 725-732.
- Castleman B, Toww VW (1954) Case records of the Massachusetts General Hospital. *N Engl J Med* 250: 1001-1005.
- Parez N, Bader-Meunier B, Roy CC, Dommergues JP (1999) Paediatric Castleman disease: report of seven cases and review of the literature. *Eur J Pediatr* 158: 631-637.
- Bowne WB, Lewis JJ, Filippa DA, Niesvizky R, Brooks AD, et al. (1999) The management of unicentric and multicentric Castleman's disease: a report of 16 cases and a review of the literature. *Cancer* 85: 706-717.
- Miida H, Kazama T, Inomata N, Takizawa H, Iwafuchi M, et al. (2006) Severe gastrointestinal involvement in paraneoplastic pemphigus. *Eur J Dermatol* 16: 420-422.
- Camisa C, Helm TN, Liu YC, Valenzuela R, Allen C, et al. (1992) Paraneoplastic pemphigus: a report of three cases including one long-term survivor. *J Am Acad Dermatol* 27: 547-553.
- Noussari HC, Deterding R, Wojtczak H, Aho S, Uitto J, et al. (1999) The mechanism of respiratory failure in paraneoplastic pemphigus. *N Engl J Med* 340: 1406-1410.