

# Pancreatic Mucinous Lesions: How Dangerous are they?

Jonathan Blair Williamson and Peter V Draganov\*

Division of Gastroenterology, Hepatology and Nutrition, University of Florida Gainesville, FL 32610, USA

Pancreatic cysts are being discovered with increasing frequency due to the expanding use of cross-sectional imaging. The prevalence of incidental pancreatic cystic lesions found on Multidetector Computed Tomography (MDCT) has been reported to be as high as 2.6% [1]. Retrospective reviews of Magnetic Resonance Imaging (MRI) have shown an even higher prevalence of pancreatic cysts, from 13.5% to 19.6% [2,3]. Mucinous cystic neoplasm (MCN) and Intraductal Papillary Mucinous Neoplasm (IPMN) comprise up to half of all resected pancreatic cysts that are incidentally discovered [4,5]. Most of these lesions harbor no malignancy at the time of diagnosis, though they are considered premalignant [6]. Traditional management has been to surgically resect all mucinous lesions; however, this paradigm is changing because risk of malignancy is not uniform among all types. The advent of Endoscopic Ultrasound with Fine Needle Aspiration (EUS-FNA) has significantly facilitated the diagnosis of mucinous pancreatic lesions [7]. Nevertheless, in everyday practice, we frequently struggle to firmly establish the mucinous nature of a lesion and to precisely determine its malignant potential.

The 2006 international consensus guidelines provided a useful framework for the diagnosis and management of pancreatic cysts [8]. Since then, a number of studies have provided us with a better understanding of the biologic behavior of mucinous pancreatic lesions. Therefore, the International Association of Pancreatology (IAP) released updated consensus guidelines for the management of IPMN and MCN of the pancreas [9]. Notable updates include: (1) a decreased threshold of Main Pancreatic Duct (MPD) dilation from 10 mm to 5 mm in order to suggest main duct IPMN (MD-IPMN); (2) a management algorithm that stratifies suspected branch duct IPMN (BD-IPMN) into lesions with “high-risk stigmata,” “worrisome features,” or no “worrisome features;” and (3) comment on the role of cyst fluid analysis for the diagnosis of pancreatic cystic lesions. A summary of the new management algorithm is provided in the figure 1.

MCN is defined histologically by the presence of ovarian stroma and has a relatively low prevalence of invasive carcinoma (<15%) at the time of diagnosis [10,11]. An argument could be made for close observation of MCN, especially if the lesion is small (<4 cm) and without mural nodules, as the reported prevalence of invasive cancer in such cases is very low [11,12]. However, because most patients are relatively young and lesions are predominantly located in the pancreatic body and tail, the IAP guidelines recommend resection in all surgically fit patients who have a reasonable life expectancy. The paucity of prospective data, including detailed information about the natural history of MCN, and lack of a definitively proven alternative therapy guide this recommendation.

IPMN is more variable in its presentation and data suggests that this lesion can be stratified with respect to malignant potential. MD-IPMN is known to possess a higher frequency of malignancy than BD-IPMN (61.6% versus 25.5%, respectively), and the incidence of invasive malignancy in MD-IPMN is 43.1% [9]. Furthermore, studies to date have shown no consistent predictive factors for malignancy in MD-IPMN. Therefore, resection is also recommended for all surgically fit patients with MD-IPMN. Unfortunately, the preoperative diagnosis is not always certain, so radiographic features must be utilized to guide the diagnosis. The most recent IAP guidelines use a cutoff

value of MPD dilation >5 mm without other causes of obstruction to characterize MD-IPMN. This decreased threshold increases the sensitivity for diagnosis of MD-IPMN without losing specificity [1]. Other diagnostic features, which are generally more obvious on EUS, include thickened walls, intraductal mucin, or mural nodules involving the MPD. Therefore, EUS can be considered if the MPD is from 5 to 10 mm in maximum diameter (Figure 1).

Certain characteristic features of BD-IPMN are known to increase the probability of inherent malignancy or malignant transformation. The current IAP guidelines categorize these features with the highest probability given to “high-risk stigmata,” which include obstructive jaundice, an enhancing solid component within the cyst, and MPD

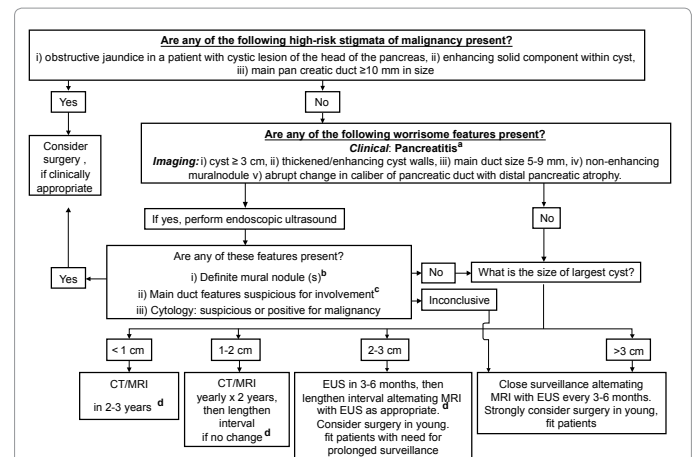


Figure 1:

- a. Pancreatitis may be an indication for surgery for relief of symptoms.
- b. Differential diagnosis includes mucin. Mucin can move with change in patient position, may be dislodged on cyst lavage and does not have Doppler flow. Features of true tumor nodule include lack of mobility, presence of Doppler flow and FNA of nodules showing tumor tissue.
- c. Presence of any one of the thickened walls, intraductal mucin or mural nodules is suggestive of main duct involvement. In their absence main duct involvement is inconclusive.
- d. Studies from Japan suggest that on follow-up of subjects with suspected BD-IPMN there is increased incidence of pancreatic ductal adenocarcinoma unrelated to malignant transformation of the BD-IPMN(s) being followed. However, it is unclear if imaging surveillance can detect early ductal adenocarcinoma, and, if so, at what interval surveillance imaging should be performed.

\*Corresponding author: Peter V Draganov, Division of Gastroenterology, Hepatology and Nutrition, University of Florida, 1600 SW Archer Road, Gainesville, FL 32610, USA, Tel: 352-273-9474; Fax: 352-392-3618; E-mail: [ercp@live.com](mailto:ercp@live.com)

Received September 28, 2012; Accepted October 01, 2012; Published October 04, 2012

Citation: Williamson JB, Draganov PV (2012) Pancreatic Mucinous Lesions: How Dangerous are they? Pancreat Disorders Ther 2:e122. doi:10.4172/2165-7092.1000e122

Copyright: © 2012 Williamson JB, et al. This is an open-access article distributed under the terms of the Creative Commons Attribution License, which permits unrestricted use, distribution, and reproduction in any medium, provided the original author and source are credited.

size  $\geq 10$  mm. For BD-IPMN with any “high-risk stigmata,” surgical resection is recommended. “Worrisome features” for BD-IPMN include a cyst  $\geq 3$  cm in diameter, thickened/enhancing cyst walls, MPD size 5-9 mm, a non-enhancing mural nodule, and an abrupt change in caliber of the MPD with distal pancreatic atrophy. Lesions that possess any “worrisome features” deserve further evaluation with EUS to evaluate for mural nodules, MPD involvement, or suspicious cytology, all of which would warrant surgical resection (Figure 1).

Even in the setting of no “high-risk stigmata” or “worrisome features” on initial evaluation, patients with BD-IPMN deserve radiologic follow-up at an interval defined by cyst size. The interval ranges from 3-6 months for cysts  $>3$  cm to 2-3 years for cysts  $<1$  cm (Figure 1). The reason for follow-up in all patients is 2-fold: (1) the natural history of BD-IPMN is not entirely clear and (2) preoperative diagnosis by radiologic means is not always accurate. The latter point is highlighted by one study that showed the accuracy of preoperative diagnosis to be only 68% for pancreatic cystic lesions; also, 20% of presumed BD-IPMN based on radiographic criteria had a histological main-duct component after review of the surgical specimen [13]. Not only should radiographic features be taken into account, but patient characteristics, such as advanced age, are important as well. The morbidity and mortality associated with surgery may not be justified in an elderly patient with BD-IPMN, which has an overall annual malignancy rate of approximately 2-3% [14]. Alternatives to surgery, such as EUS-guided ethanol ablation, have shown promise but more research is needed [1].

An exact preoperative diagnosis of pancreatic cysts would be ideal but is not realistic with radiologic evaluation alone. The important role of imaging (MDCT, MRI, and/or EUS) is to identify and risk stratify pancreatic cystic lesions. Whether or not an exact diagnosis is achieved may not turn out to be as important as the risk stratification based on imaging characteristics. A few recent prospective long-term follow-up studies showed that patients with presumed BD-IPMN in the absence of concerning radiographic features can be safely followed [15-17]. More importantly, the patients that developed suspicious radiologic findings (e.g. mural nodules or increase in cyst size) during close follow-up underwent surgical resection and none had invasive cancer [15-17].

Finally, the issue of pancreatic cyst fluid analysis has been studied more rigorously in recent years in an attempt to better classify lesions. Cyst fluid Carcinoembryonic Antigen (CEA) level  $\geq 192$ -200 ng/mL is close to 80% accurate for the diagnosis of a mucinous cyst, but the CEA level has no use in distinguishing benign from malignant cysts [7,18]. The addition of cytology in one study detected 30% more malignant lesions in small ( $<3$  cm) BD-IPMN [19]. Molecular analyses of cyst fluid, notably KRAS and GNAS mutations, also offer promise in the diagnosis of malignancy [20,21]. Despite this data, the IAP guidelines still consider cyst fluid analysis as investigational in most scenarios.

It should be highlighted that in the United States (U.S.), the management algorithm endorsed by the international consensus guidelines (old and new) is rarely followed [22]. The vast majority of patients with incidentally discovered pancreatic cysts in the U.S. will be evaluated by EUS and most will undergo FNA for cyst fluid analysis [22]. We believe that a multitude of factors contribute to this discrepancy, including: (1) we have very crude criteria to judge malignant potential (e.g. size), but cancer can be present even in small cysts; (2) the natural history of mucinous lesions is not well-defined; (3) in the U.S., there is a perception that a conservative approach is inferior to an invasive alternative that has diagnostic potential;

(4) U.S. patients are frequently unwilling to deal with uncertainty, particularly when it comes to the possibility of cancer; (5) from a medicolegal perspective, physicians are concerned that they may be liable if the diagnosis of cancer is missed (despite following the guidelines); (6) the U.S. medical system is fractionated and patients may not get appropriate follow-up imaging due to change of insurance status, geographic constraints, etc.; (7) there is growing concern about radiation exposure due to multiple CT's; (8) cumulative costs of a surveillance protocol are perceived to be higher; and (9) even if the patient is not a surgical candidate, a firm diagnosis can help with life planning.

In conclusion, the new IAP consensus guidelines for the management of IPMN and MCN of the pancreas highlight advancements in knowledge since the initial 2006 guidelines were published. Nevertheless, the levels of evidence for all items addressed in the new guidelines remain low. The paradigm of surgical resection for mucinous lesions is changing to a more stratified approach, with close observation for low-risk cystic lesions. Until the natural history is better defined and diagnostic modalities are more accurate, surgical resection may be the optimal management strategy in equivocal cases. If surgery is spared initially, though, the key is to maintain close and indefinite follow-up of all patients with suspected mucinous cystic lesions of the pancreas. Early EUS with FNA and fluid analysis has become the preferred strategy for evaluation of pancreatic cystic lesions in the U.S., which is a departure from the international guidelines. More prospective data is needed to further refine our approach.

## References

1. Laffan TA, Horton KM, Klein AP, Berlanstein B, Siegelman SS, et al. (2008) Prevalence of unsuspected pancreatic cysts on MDCT. *Am J Roentgenol* 191: 802-807.
2. Lee KS, Sekhar A, Rofsky NM, Pedrosa I (2010) Prevalence of incidental pancreatic cysts in the adult population on MR imaging. *Am J Gastroenterol* 105: 1079-1084.
3. Zhang XM, Mitchell DG, Dohke M, Holland GA, Parker L (2002) Pancreatic cysts: depiction on single-shot fast spin-echo MR images. *Radiology* 223: 547-553.
4. Fernández-del Castillo DF, Targarona J, Thayer SP, Rattner DW, Brugge WR, et al. (2003) Incidental pancreatic cysts: clinicopathological characteristics and comparison with symptomatic patients. *Arch Surg* 138: 427-433.
5. Goh BK, Tan YM, Cheow PC, Chung YF, Chow PK, et al. (2006) Cystic lesions of pancreas: an appraisal of aggressive resectional policy adopted at a single institution during 15 years. *Am J Surg* 192: 148-154.
6. Adsay NV (2008) Cystic neoplasia of the pancreas: pathology and biology. *J Gastrointest Surg* 12: 401-404.
7. Brugge WR, Lewandrowski K, Lee- Lewandrowski E, Centeno BA, Szydio T, et al. (2004) Diagnosis of pancreatic cystic neoplasms: a report of the cooperative pancreatic cyst study. *Gastroenterology* 125: 1330-1336.
8. Tanaka M, Chari S, Adsay V, Fernández-del Castillo C, Falconi M, et al. (2006) International consensus guidelines for management of intraductal papillary mucinous neoplasms and mucinous cystic neoplasms of the pancreas. *Pancreatol* 6: 17-32.
9. Tanaka M, Fernández-del Castillo C, Adsay V, Chari S, Falconi M, et al. (2012) International consensus guidelines 2012 for the management of IPMN and MCN of the pancreas. *Pancreatol* 12: 183-197.
10. Reddy RP, Smyrk TC, Zapiach M, Levy MJ, Pearson RK, et al. (2004) Pancreatic mucinous cystic neoplasm defined by ovarian stroma: demographics, clinical features and prevalence of cancer. *Clin Gastroenterol Hepatol* 2: 1026-1031.
11. Crippa S, Salvia R, Warshaw AL, Domínguez I, Bassi C, et al. (2008) Mucinous cystic neoplasm of the pancreas is not an aggressive entity: lessons from 163 resected patients. *Ann Surg* 247: 571-579.
12. Yamao K, Yanagisawa A, Takahashi K, Kimura W, Dio R, et al. (2011)

- Clinicopathological features and prognosis of mucinous cystic neoplasm with ovarian-type stroma: a multi-institutional study of the Japan pancreas society. *Pancreas* 40: 67-71.
13. Correa-Gallego C, Ferrone CR, Thayer SP, Wargo JA, Warshaw AL, et al. (2010) Incidental pancreatic cysts: do we really know what we are watching? *Pancreatology* 10: 144-150.
  14. Lévy P, Jouannaud V, O'Toole D, Couvelard A, Vullierme MP, et al. (2006) Natural history of intraductal papillary mucinous tumors of the pancreas: actuarial risk of malignancy. *Clin Gastroenterol Hepatol* 4: 460-468.
  15. Arlix A, Bournet B, Otaï P, Canevet G, Thevenot A, et al. (2012) Long-term clinical and imaging follow-up of nonoperated branch duct form of intraductal papillary mucinous neoplasms of the pancreas. *Pancreas* 41: 295-301.
  16. Tanno S, Nakano Y, Nishikawa T, Nakamura K, Sasajima J, et al. (2008) Natural history of branch duct intraductal papillary mucinous neoplasms of the pancreas without mural nodules: long term follow-up results. *Gut* 57: 339-343.
  17. Salvia R, Crippa S, Falconi M, Bassi C, Guarise A, et al. (2007) Branch-duct intraductal papillary mucinous neoplasms of the pancreas: to operate or not to operate? *Gut* 56: 1086-1090.
  18. Park WG, Mascarenhas R, Palaez-Luna M, Smyrk TC, O'Kane D, et al. (2011) Diagnostic performance of cyst fluid carcinoembryonic antigen and amylase in histologically confirmed pancreatic cysts. *Pancreas* 40: 42-45.
  19. Genevay M, Mino-Kenudson M, Yaeger K, Konstantinidis IT, Ferrone CR, et al. (2011) Cytology adds value to imaging studies for risk assessment of malignancy in pancreatic mucinous cysts. *Ann Surg* 254: 977-983.
  20. Khalid A, Zahid M, Finkelstein SD, LeBlanc JK, Kaushik N, et al. (2009) Pancreatic cyst fluid DNA analysis in evaluating pancreatic cysts: a report of the PANDA study. *Gastrointest Endosc* 69: 1095-1102.
  21. Wu J, Matthaei H, Maitra A, Dal Molin M, Wood LD, et al. (2011) Recurrent GNAS mutations define an unexpected pathway for pancreatic cyst development. *Sci Transl Med* 3: 92ra66.
  22. Buscaglia JM, Shin EJ, Giday SA, Kapoor S, Dunbar KB, et al. (2009) Awareness of guidelines and trends in the management of suspected pancreatic cystic neoplasms: survey results among general gastroenterologists and EUS specialists. *Gastrointest Endosc* 69: 813-820.