

## Pachydermoperiostosis vs. Acromegaly in a Patient with Cutis Verticis Gyrata

Jaimie Glick, Ravneet Ruby Kaur\* and Gina Taylor

Department of Dermatology, State University of New York Downstate Medical Center, USA

### Abstract

Cutis Verticis Gyrata (CVG) is a rare condition associated with thickening of the skin folds of the scalp and forehead that resembles the appearance of gyri of the brain cortex. These skin lesions can lead to local skin infections as well as cosmetic complaints.

Primary CVG has no obvious cause and is often associated with neurological conditions while secondary CVG is due to inflammation or infiltration of the scalp and is associated with endocrine or neoplastic conditions including acromegaly and pachydermoperiostosis.

We discuss a complicated case of a 34 year-old male with cutis verticis gyrata presenting simultaneously with hypertrophic osteoarthropathy and a pituitary macroadenoma. The patient was initially suspected of having acromegaly secondary to the pituitary adenoma but further workup showed normal insulin growth factor-1 and growth hormone levels inconsistent with acromegaly. Subsequent workup was consistent with a diagnosis of the complete form of primary hypertrophic osteoarthropathy also known as pachydermoperiostosis.

### Introduction

Cutis Verticis Gyrata (CVG) is a rare condition associated with thickening of the skin folds of the scalp and forehead that resembles the appearance of gyri of the brain cortex.

These skin lesions can lead to local skin infections as well as cosmetic complaints. The first case of CVG was first reported by Alibert in 1837 while in 1907 Unna presented a case series of the condition and coined the term cutis verticis gyrata [1,2].

Primary CVG has no obvious cause and is often associated with neurological conditions while secondary CVG is due to inflammation or infiltration of the scalp and is associated with endocrine or neoplastic conditions [1-3]. Primary CVG has been divided into two forms: nonessential and essential. Essential CVG is not associated with additional abnormalities while nonessential primary CVG is linked to neurological conditions including epilepsy, cerebral palsy, mental retardation and ocular abnormalities. The histopathology of primary CVG can be normal or contain thick connective tissue with hypertrophy or hyperplasia of sebaceous glands or hair follicles [2]. Secondary CVG has been associated with a number of medical conditions including eczema, psoriasis, amyloidosis, myxedema, insulin-resistance syndrome, acromegaly, and pachydermoperiostosis [2,4-7].

We discuss a complicated case of a 34 year-old male with cutis verticis gyrata presenting simultaneously with hypertrophic osteoarthropathy and a pituitary macroadenoma. The patient was initially suspected of having acromegaly secondary to the pituitary adenoma but further workup showed normal IGF-1 and growth hormone levels inconsistent with acromegaly. Subsequent workup was consistent with a diagnosis of the complete form of primary hypertrophic osteoarthropathy also known as pachydermoperiostosis.

### Case Report

A 34 year-old Jamaican male with bilateral hearing loss as a child presented to our clinic for coarse furrowing of the skin of the scalp and forehead consistent with cutis verticis gyrata that began during his teenage years. The patient had complaints of bilateral eyelid swelling and blurry vision as well as progressive bilateral knee pain.

He had noted swelling with enlargement of his hands and feet over the last few years. The patient did not report headache, vision loss, or enlargement of his facial features such as the nose, jaw or forehead. The patient's past medical history was significant for mental retardation and bilateral hearing loss since childhood. The history of present illness was obtained from his mother. The mother reported no known family history of genetic or heritable diseases and no family members with similar complaints. The patient's medications included only antibiotic eye drops for eyelid swelling and ibuprofen for joint pain.

A written photographic consent was obtained from the patient and a verbal consent was obtained from his mother. Physical exam was significant for scalp and forehead thickening with increased wrinkling (Figure 1 and 2). There was no alopecia or alterations in the distribution of hair over the folds of the scalp. The patient had significant hearing loss in both ears and he wore a hearing aid in his left ear. There was marked edema of the upper eyelids and inability to visualize objects in the right temporal visual field. There was significant enlargement of the bilateral hands (Figure 3 and 4) with non-pitting edema and tenderness of all carpal-metacarpal, MCP and interphalangeal joints. There was obvious bilateral clubbing of all digits on the hands and feet as well as nonpitting edema and tenderness of the bilateral knee, tarsal-metatarsal and interphalangeal joints.

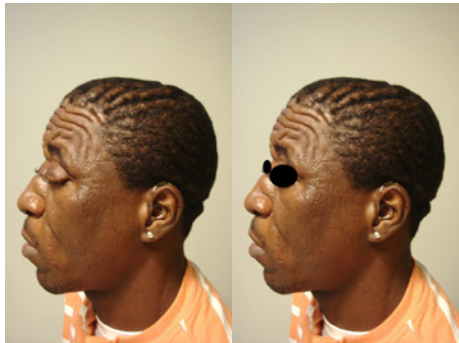Two weeks prior to presenting to our dermatology clinic the patient was admitted to the hospital for inpatient work-up of the above signs and symptoms. An MRI with intravenous contrast of the brain

**\*Corresponding author:** Ravneet Ruby Kaur, BSN, MD, Department of Dermatology, State University of New York Downstate Medical Center, 450 Clarkson Avenue, Brooklyn, NY, 11203, USA, Tel: (415) 939-5794; Fax: (718) 270-2794; E-mail: [RubyKaurMD@gmail.com](mailto:RubyKaurMD@gmail.com)


**Received** December 28, 2011; **Accepted** March 21, 2012; **Published** March 26, 2012

**Citation:** Glick J, Kaur RR, Taylor G (2012) Pachydermoperiostosis vs. Acromegaly in a Patient with Cutis Verticis Gyrata. J Clin Exp Dermatol Res 3:142. doi:10.4172/2155-9554.1000142

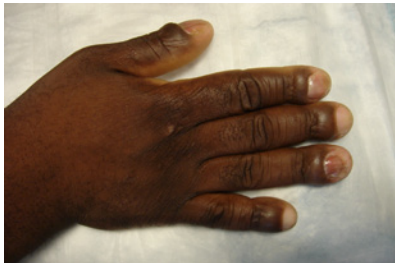**Copyright:** © 2012 Glick J, et al. This is an open-access article distributed under the terms of the Creative Commons Attribution License, which permits unrestricted use, distribution, and reproduction in any medium, provided the original author and source are credited.



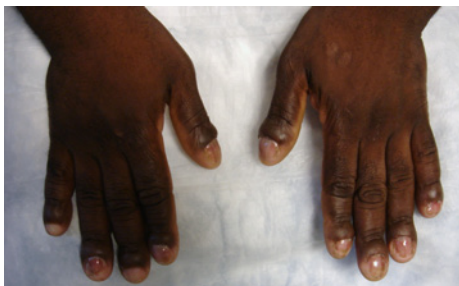**Figure 1:** Profile view of the patient, the furrows extending onto the forehead can be appreciated.



**Figure 2:** Note the furrows extending onto the forehead and the bilateral blepharoptosis.



**Figure 3:** Clubbing of the digits.



**Figure 4:** Clubbing of all the digits.

demonstrated a mildly enlarged pituitary in the sella turcica measuring 1.2 cm consistent with a pituitary macroadenoma. The patient was initially suspected of having acromegaly and an endocrine work-up was done. Laboratory results are shown in Table 1. X-rays of the patient's hands and feet consistent with hypertrophic osteoarthropathy are shown in Figures 5 and 6. A chest x-ray was performed which showed no masses, focal consolidation, pneumothorax or pleural effusion.

The patient's laboratory results were inconsistent with a diagnosis of acromegaly and a diagnosis of pachydermoperiostosis was made given the patient's clinical presentation, prolonged digital clubbing, and x-ray findings. Further evaluation including a glucose tolerance test and DEXA scan were ordered but the patient was subsequently lost to follow up.

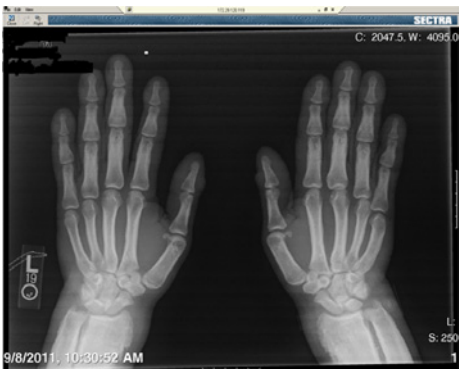Discussion

Pachydermoperiostosis (PDP) or primary hypertrophic osteoarthropathy is a rare genetic disorder characterized by clubbing of the digits, periosteal new bone formation, coarsening of the facial features and furrowing of the skin especially the face as in CVG. Primary hypertrophic osteoarthropathy accounts for 5% of all cases

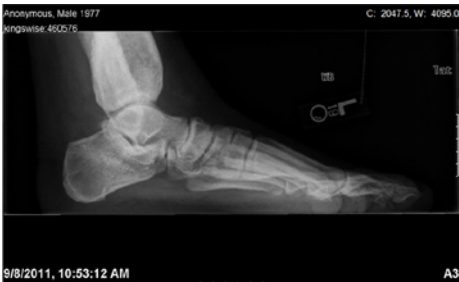Laboratory Test	Patient's Value	Normal Range
Thyroid Stimulating Hormone (TSH)	1.543	.35-5.50 mIU/L
Prolactin (PRL)	19.11	2.1-17.7 ng/mL
Growth Hormone (GH)	0.7	< 10 ng/mL
IGF-1	101	53-331ng/mL
Testosterone	738.75	241-827 ng/dL
Follicle Stimulating Hormone (FSH)	14.19	1.4-18.1mIU/mL
ACTH	11	7-50 pg/mL
Cortisol	8.98	mcg/dL
HgbA1c	5.5	< 6.5%
Rheumatoid Factor	7	<14 IU/mL

\*\*Reference Lab Quest Diagnostics, One Malcolm Ave, Teterboro, NJ 07608

Table 1: Lab Values.



**Figure 5:** X-Ray of the wrists and hands. Extensive irregular periosteal reaction of the radius and ulna with diffuse soft tissue swelling consistent with hypertrophic osteoarthropathy.



**Figure 6:** AP X-Ray view of the left ankle and foot. Irregular periosteal reaction of the long bones prominent in the distal tibia and fibula. Soft tissue swelling and right foot fifth digit dislocation. Impression consistent with hypertrophic osteoarthropathy.

of hypertrophic osteoarthropathy and is more common in African-Americans and males with the male-to-female ratio approximately 7:1 [8]. Pachydermoperiostosis is thought to be inherited as an autosomal dominant trait with variable expression [8-11]. However, cases have been reported without any obvious family history of the disorder suggesting a possible autosomal recessive inheritance or mutation [9,10]. The syndrome was first described in 1868 by Friedreich who reported a case of two male siblings with “hyperostosis of the entire skeleton [11]”. Later Touraine, Solente and Gole described pachydermoperiostosis as the primary form of hypertrophic osteoarthropathy differing from secondary hypertrophic osteoarthropathy, which is always associated with a primary disease often of a pulmonary or cardiac nature.

The diagnostic criteria for PDP include the presence of digital clubbing and radiographic evidence of periostosis [11]. Other findings include polyarthritides, cutis verticis gyrata, seborrheic dermatitis, acne, bilateral blepharoptosis, and hyperhidrosis. Disease onset usually begins in adolescence with gradual enlargement of the hands and feet, clubbing of the fingers and toes, coarsening of facial features and development of cutis verticis gyrata [8-11]. Progression of PDP typically ceases after 10 years but patients are left with significant morbidity due to restricted joint motion, neurologic problems and coarse facial features including cutis verticis gyrata.

Pachydermoperiostosis can present in three ways: the complete form, the incomplete form and the “forme fruste.” [8-11] The complete form has a gradual onset usually in adolescence. There is marked coarsening of facial features and the skin of the forehead and scalp becomes folded and wrinkled. The incomplete form lacks only the cutis verticis gyrata of the scalp while the “forme fruste” presents without obvious periosteal changes. The pathological mechanism of PDP remains unknown although the role of fibroblast activation has also recently been suggested [12]. The incomplete form of PDP, primary osteoarthropathy without pachydermia, was mapped to chromosome 4q33-q34 [13]. Gene mutations in HPGD, encoding 15-hydroxyprostaglandin dehydrogenase, the main enzyme of prostaglandin degradation were identified [13]. It has been suggested that the clinical features of clubbing of the digits and bone changes are due to elevated PGE2 [13]. However, the mechanism by which the pachydermia of PDP occurs has yet to be elucidated [12]. The case we present is most consistent with the complete form of the syndrome.

There have been a few cases in the literature when patients such as the above described were initially considered to have acromegaly and were later diagnosed with pachydermoperiostosis [14-17]. Additionally, there has been one prior case report of a patient presenting simultaneously with a pituitary adenoma and features of pachydermoperiostosis [18]. The patient was subsequently found to have acromegaly diagnosed with elevated insulin growth factor-1 levels and impaired glucose tolerance testing in addition to pachydermoperiostosis. Our patient had normal growth hormone and insulin growth factor-1 levels with a mildly elevated prolactin level. The patient's pituitary adenoma was most likely an incidentaloma found on MRI and not a growth hormone tumor of acromegaly or a prolactinoma given the laboratory findings. A 2004 meta-analysis found the overall prevalence of incidental pituitary adenomas to be 14.4% in autopsies and 22.5% in radiologic studies [19].

The treatment of pachydermoperiostosis includes management to relieve symptoms of arthritis such as nonsteroidal anti-inflammatory agents and corticosteroids. The treatment of CVG has traditionally included adequate hygiene with appropriate cleaning between skin folds. Surgical options include serial excision and skin grafting, local

flap and tissue expansion and one-stage tissue expansion followed by reconstruction [1,20]. In the case of secondary CVG, treatment of the underlying disorder such as myxedema or acromegaly can help resolve the lesions. A recent study into the medical management of the skin lesions of pachydermoperiostosis showed successful treatment in three patients using botulinum toxin type A [8].

Although pachydermoperiostosis and acromegaly are quite rare, it is important to differentiate the two entities because of the prognostic and therapeutic implications. Acromegaly may be treated with the removal of the pituitary tumor if possible or agents such as somatostatin analogs like octreotide. Pachydermoperiostosis is an inherited disorder and removal of our patient's incidentaloma would have proved unnecessary and ineffective.

### Conflicts of Interest

The authors have no relevant conflicts of interest to disclose.

### References

1. El-Husseiny M, Yarrow J, Moiem N (2010) Primary cutis gyrata: Review of literature and a successful new surgical approach. *Eur J Plast Surg* 33: 153-157.
2. Diven DG, Tanus T, Raimor SS (1991) Cutis verticis gyrata. *Int J Dermatol* 30: 710-712.
3. Chen ZY, Ho WH (2006) Cutis verticis gyrata. *Acta Neurol Taiwan* 15: 149-150.
4. Al-Bedaia M, Al-Khenaizan AS (2008) Acromegaly presenting as cutis verticis gyrata. *Int J Dermatol* 47: 164.
5. O'Reilly FM, Slaney I, O' Loughlin S (1997) Acromegaly and cutis verticis gyrata. *J R Soc Med* 90: 79.
6. Corbalán-Velez R, Pérez-Ferriols A, Aliaga-Bouiche A (1999) Cutis verticis gyrata secondary to hypothyroid myxedema. *Int J Dermatol* 38: 781-783.
7. Woollons A, Darley CR, Lee PJ, Brenton DP, Sonksen PH, et al. (2000) Cutis verticis gyrata of the scalp in a patient with autosomal dominant insulin resistance syndrome. *Clin Exp Dermatol* 25: 125-128.
8. Ghosn S, Uthman I, Dahdah M, Kibbi AG, Rubeiz N (2010) Treatment of pachydermoperiostosis pachydermia with botulinum toxin type A. *J Am Acad Dermatol* 63: 1036-1041.
9. Thappa DM, Sethuraman G, Kumar GR, Elangovan S (2000) Primary Pachydermoperiostosis: A case report. *J Dermatol* 27: 106-109.
10. Bhaskaranand K, Shetty RR, Bhat AK (2001) Pachydermoperiostosis: Three case reports. *J Orthop Surg (Hong Kong)* 9: 61-66.
11. Guerini MB, Barbato MT, Sa NB, Nunes DH, Zeni PR (2011) Pachydermoperiostosis – the complete form of the syndrome. *An Bras Dermatol* 86: 582-584.
12. Kabashima K, Sakabe J, Yoshiki R, Tabata Y, Kohno K, et al. (2010) Involvement of Wnt signaling in dermal fibroblasts. *Am J Pathol* 176: 721-732.
13. Uppal S, Diggle CP, Carr IM, Fishwick CW, Ahmed M, et al. (2008) Mutations in 15-hydroxyprostaglandin dehydrogenase cause primary hypertrophic osteoarthropathy. *Nat Genet* 40: 789-793.
14. Donnelly S, Sugrue D (1991) It looks like acromegaly but it is not. *Ir J Med Sci* 160: 8-9.
15. Harbison JB, Nice CM Jr (1971) Familial pachydermoperiostosis presenting as acromegaly-like syndrome. *Am J Roentgenol Radium Ther Nucl Med* 112: 532-536.
16. Mahy IR, Wiggins J (1992) Pachydermoperiostosis mimicking acromegaly. *J R Soc Med* 85: 46-47.
17. Singh GR, Menon PS (1995) Pachydermoperiostosis in a 13 year-old boy presenting as an acromegaly-like syndrome. *J Pediatr Endocrinol Metab* 8: 51-54.
18. Shimizu C, Kubo M, Kijima H, Uematsu R, Sawamura Y, et al. (1999) A rare case of acromegaly associated with pachydermoperiostosis. *J Endocrinol Invest* 22: 386-389.

19. Ezzat S, Asa SL, Couldwell WT, Barr CE, Dodge WE, et al. (2004) The prevalence of pituitary adenomas: a systematic review. *Cancer* 101: 613-619.
20. Radwanski HN, Almeida MW, Pitanguy I (2009) Primary essential cutis verticis gyrata: a case report. *J Plast Reconstr Aesthet Surg* 62: e430-433.