

## Operative Management of Fracture Shaft Humerus by Plate Osteosynthesis and Locked Intramedullary Nail: A Comparative Study

Salem Bajuifer, Mohamed Hassan Shaalan\* and Ali Alamuodi

Orthopaedic Department, Sligo University Hospital, Ireland

\*Corresponding author: Mohamed Hassan Shaalan, Orthopaedic Department, Sligo University Hospital, Ireland, E-mail: shalan\_6@yahoo.com

Received date: October 01, 2018; Accepted date: November 12, 2018; Published date: November 19, 2018

Copyright: © 2018 Bajuifer S, et al. This is an open-access article distributed under the terms of the Creative Commons Attribution License; which permits unrestricted use; distribution; and reproduction in any medium; provided the original author and source are credited.

### Abstract

**Background:** Treatment of diaphyseal fracture humerus is still challenging, non-surgical treatment is still widely accepted by many surgeons either by brace or cast, and there is no gold standard surgical treatment. The classic treatment was plate and screws osteosynthesis, locked intramedullary nail fixation either antegrade or retrograde introduced and in the last decade is increasingly used.

**Methods:** This study includes 100 patients nursed at the Department of Orthopedic Surgery in Alnoor Specialized Hospital, Holy Makkah, Saudi Arabia. Total 50 fractures had been treated by plate fixation and other 50 patients by locked humerus nail. Union, functional outcome, the need for additional surgery and possible complications were compared between the locked humerus nail and plate osteosynthesis groups. Exclusion criteria include patients with open fractures preoperative nerve palsy, known patients with pre-injury shoulder pain or restriction of shoulder range of motion and fractures due to pre-existing bone pathology.

**Results:** No remarkable difference regarding functional outcome was noted between the two groups. There were two cases of postoperative radial nerve palsy in the plate osteosynthesis group, versus zero in the locked humeral nail group (significant difference). Significantly two cases with restrictive pain and/or functional hindrance in the shoulder were recorded in the IMN group. Problems with plate osteosynthesis material occurred as often in the PSF group as in the IMN group. One of the patients developed wound infection after plate osteosynthesis. A significantly less number of complications were seen in the IMN group than in the PSF group. A reoperation was necessary for 6% of the PSF patients and 4% of the IMN patients (non-significant difference). In this retrospective study, IMN achieved better results than PSF of humeral midshaft fractures and was associated with less postoperative complications.

**Conclusion:** The nailing of humeral shaft fractures should be considered as a good option in treatment for all surgical indications.

**Keywords:** Humerus; Diaphysis; Intramedullary nail; Plates; Screws

### Introduction

The diaphysis or shaft can be defined as that part of the humerus situated between the superior margin of pectoralis major tendon insertion and 2 cm above the olecranon fossa. Müller et al., defined the humeral shaft by defining first the extent of the proximal and distal segments of the bone. The proximal and distal segments of the humerus are each defined by a square whose sides are the same length as the widest part of the epiphysis. Around 5-10% of all long bone fractures happen in the humerus [1]. Humeral diaphyseal fractures represent around 20% of all humeral fractures [2].

The humeral shaft serves as the inclusion and origin site for a few major muscles of the upper extremity. These play a vital job in the biomechanical results of various fracture patterns. Muscles inserting on the shaft incorporate the deltoid, pectoralis real, teres major, latissimus dorsi, and coracobrachialis; those originating on the pole include the brachialis, brachioradialis, and the medial and lateral heads of the triceps brachii [3].

The blood supply to the humeral shaft is provided predominantly by the nutrient artery, a branch off of the brachial artery which penetrates at the proximal third of the humerus on the medial side of the bone. The periosteum and the encompassing muscle bed additionally provides vascularity, to a lesser degree. Regarding important neurologic structures, the middle, ulnar, and radial nerves all lie in closeness to the humeral shaft [4,5].

Intramedullary nail and plate are the 2 most generally utilized surgical treatments. Both methodologies have certain biomechanical and physiologic advantages and disadvantages. Intramedullary nailing of humeral shaft fractures is a load-sharing implant that permits preservation of periosteal blood supply and limits disruption of fracture biology. Plate fixation permits direct visualization, anatomic decrease, and rigid fracture fixation of the fracture and facilitates the identification, exploration, and protection of the radial nerve. There is no consensus regarding whether intramedullary nail or plate is the ideal treatment method [6]. Use of this plate, however, requires extensive dissection and is complicated by the closeness of the radial nerve and the risk of mechanical failure in osteopenic bone [7].

## Patients and Methods

Between 2010 and 2014, 100 patients with a humeral shaft fracture requiring surgical stabilization were tentatively randomized to experience fixation by either a DCP or locked IMN at a specialized hospital. The fractures were situated from 3 cm distal to the surgical neck 2 cm to 3 cm proximal to the olecranon fossa. The signs for operation included: polytrauma, instability and early failure of conservative treatment. Each patient was skeletally mature. We excluded patients with preoperative nerve palsy, open fractures, known patients with preinjury shoulder pain or limitations, pathological fractures, non-cooperative patients, because of a decreased cognitive condition caused by head trauma or with advanced dementia were

excluded. Patients were selected randomly whose fracture settled by DCP had to plate through an anterolateral or posterior approach. The length of the plate was subject to the pattern of the fracture, comminution, and at the discretion of the surgeon. Russell-Taylor locked humeral IMNs (Smith and Nephew) were utilized. Reaming was done just if necessary for insertion of the IMN of 6.7 mm to 9 mm distance across. Our protocol indicated antegrade insertion. Total 50 patients in each group were operated most of the road traffic accident was the cause of fractures with age range in PSF group 42, male: female ratio was 6:1, and in the second group age range was 36 years, male: female ratio was 11:1 (Table 1).

	PSF	IMN	Total
<b>AO-classification</b>			
<b>Total</b>	<b>50</b>	<b>50</b>	<b>100</b>
<b>Type A : simple (non-Type A: simple (non-comminuted) fractures</b>	<b>25</b>	<b>23</b>	<b>48</b>
A1: Spiral fractures	5	3	8
A2: Oblique fractures	11	13	24
A3: Transverse fractures	9	7	16
<b>Type B: Fractures with butterfly fragment</b>	<b>22</b>	<b>20</b>	<b>42</b>
B1: Spiral fractures	11	5	16
B2: Bending wedge fractures	6	8	14
B3: Wedge fractures with more than one fragment	5	7	12
<b>Type C: Comminuted fractures</b>	<b>3</b>	<b>7</b>	<b>10</b>
C1: Double spiral fractures	3	3	6
C2: Segmental fractures	0	5	5
C3: Complex fractures	0	0	0

**Table 1:** Fractures were classified as per AO classification.

All patients received general anaesthesia, for patients treated with plate fixation position was supine and the surgical approach was anterolateral approach, for the patients treated with intramedullary

nail position was semi sitting and the approach was lateral small incision with small incision in the rotator cuff 1 cm in the coronal plain, which should be repaired (Table 2).

	PSF	IMN
<b>Number of Patients</b>	50	50
<b>Male</b>	43	46
<b>Female</b>	7	4
<b>Age in years (range)</b>	42 (20-68)	36 (19-56)

**Table 2:** Patient's details in both the groups.

Union, functional result, possible complexities and the requirement for additional surgery were compared at between the IMN and PSF group. Union was characterized as fracture healing within a time of 6 months. Delayed union was characterized as healing between 6

months and 1 year. "Non-union" referred to fractures that were not healed within one year and required re-osteosynthesis.

Practical result was reviewed as excellent, good, fair or poor. Excellent healing implied that complete functional recovery was

accomplished. The result was rated as good if there was a suboptimal recovery without an effect on work and regular activities. The functional result was evaluated as fair when patients experienced functional impairment with every day exercises and work. Poor recovery implied that day by day or work exercises had to be abandoned because of functional impairment. Complications that were compared included: the occurrence of iatrogenic fractures, hardware failure, morbidity of shoulder or elbow, radial nerve palsy, the manifestation of infections and compartment syndrome. We likewise looked at the requirement for additional surgery. The results were statistically assessed.

## Results

Union was obtained by 3-6 months with group PSF except for three patients which was 6%, for the second group IMN union was obtained by 3-5 months, the reoperation rate was 6% for group PSF two for revision of the plate and one grafting, one for removal of plate and screws with debridement after the fracture united, reoperation rate for the group IMN was 4% in the form of removal of the nail after complete union due to shoulder pain with restriction of abduction due to prominence of the nail tip at the greater tuberosity, one patient after 6 months and second patient after 9 months after that patients obtained full range of motion of the shoulder (Table 3).

	Total		PSF		IMN	
	n	%	n	%	n	%
<b>Union</b>	97	97	47	94	50	100
<b>Delayed union</b>	1	1	1	2	0	0
<b>Non union</b>	2	2	2	4	0	0

**Table 3:** Time to union.

No critical distinction in useful recovery was seen between the 2 groups (Table 4). Overall, the functional recuperation was excellent in 72%, good in 22%, fair in 0% and poor in 6% of patients.

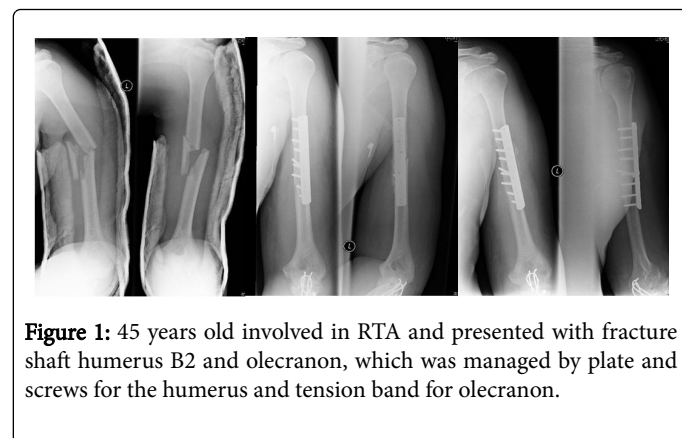
	Total		PSF		IMN	
	n	%	n	%	n	%
<b>Excellent</b>	72	72	34	68	38	76
<b>Good</b>	22	22	12	24	10	20
<b>Fair</b>	0	0	0	0	0	0
<b>Poor</b>	6	6	4	8	2	4

**Table 4:** Functional recovery.

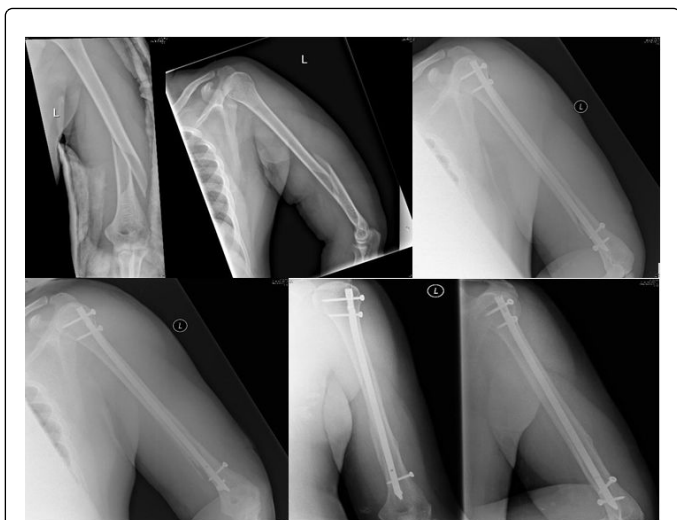One patient developed radial nerve palsy postoperative after plate and screw fixation which was gradually functionally recovered over a period of 5 months; there were 2 patients with protective pain and/or functional obstruction in the shoulder in the IMN group. Overall, a remarkably more complication rate was seen in the group of PSF than IMN group.

A reoperation was compulsory in 6% of the PSF patients and 4% of the IMN patients (no significant difference).

## Cases (Figures 1 and 2)



**Figure 1:** 45 years old involved in RTA and presented with fracture shaft humerus B2 and olecranon, which was managed by plate and screws for the humerus and tension band for olecranon.



**Figure 2:** 3 years old male patient involved in RTA , presented with fracture left humerus A1 which was fixed by IMN, intact neurovascular pre and postoperative.

## Discussion

When fixation of fracture shaft humerus is indicated the plate and screw fixation is the most popular than the intramedullary nail fixation in spite of no significant major differences in the term of union rate, union time, with least postoperative complications than plate and screw fixation. The functional outcome in both groups was excellent in 72%, good in 22% and poor in 6%. The union rate was 97% in PSF group while 100% in IMN group. The cause of shoulder pain with IMN is because of prominent nail tip and this was found in two patients, both were fully recovered after nail removal.

One patient developed radial nerve palsy in the group of PSF postoperatively and fully recovered over a period of 5 months, two patients with non-union need revision of surgery with bone grafting, one patient developed infection late postoperative and managed by removal of the plate and screws, debridement after full union.

We reviewed what was published recently in the literature and we will mention some of these opinions. Rommens et al., reflectively looked into DCP fixation of the humerus and after that tentatively looked into IMN fixation. They accomplished better outcomes with a retrograde IMN than with an antegrade IMN or DCP fixation; they recorded that 90% of their patient's recovered regained excellent function in the shoulder and elbow, and found that just 5% required secondary surgery. Unfortunately, functional assessments were qualitative and their signs for essential primary surgery more extensive than is for the most part accepted [8].

Flinkkila observed that shoulder scores and isometric strength show no difference after nailing and plating but flexion was better after

plating so antegrade nailing if performed properly is not responsible for shoulder joint dysfunction. Martinez found functional results and the ROM of the shoulder and elbow to be similar with nailing and plating while treating non-united fractures [9].

Demirel experienced 92% excellent or satisfactory recovery of shoulder joint function after nailing. He consider damage to rotator cuff with inadequate repair, distinguished nail head or locking screws, axillary nerve injury, and intra-operative comminution of the humeral head for poor recovery of shoulder working [10].

## Conclusion

Humeral shaft fracture can be managed successfully with plate and screws or intramedullary nail, both of them are good options, each procedure has its own complications. No significant differences between PSF and IMN as regard union rate and functional recovery. Redo surgery, non-union, implant failure and radial nerve palsy are of higher incidence with PSF than IMN. IMN is considered biological fixation preserving fracture haematoma with no periosteal stripping and more cosmetic than PSF. In order to reduce the incidence of shoulder pain avoid prominent tip of the nail through the greater tuberosity, repair of the incised rotator cuff, encourage early range of motion. IMN is technically demanding than PSF with less blood loss and shorter operative time.

## References

1. Müller ME, Nazarian S, Koch P (1990) The comprehensive classification of fractures of long bones. Springer, New York.
2. Rose SH, Melton LJ, Morrey BF, Ilstrup DM, Riggs BL (1982) Epidemiological features of humeral fractures. *Clin Orthop* 168: 24-30.
3. Walker M, Palumbo B, Badman B, Brooks J, Van Gelderen J, et al. (2011) Humeral shaft fractures: a review. *J Shoulder Elbow Surg* 20: 1-12.
4. Hoppenfeld S, deBoer P (2003) Surgical exposures in orthopaedics: the anatomic approach. Philadelphia: Lippincott Williams and Wilkins.
5. McCormack RG, Brien D, Buckley RE, McKee MD, Powell J, et al. (2000) Fixation of fractures of the shaft of the humerus by dynamic compression plate or intramedullary nail. A prospective, randomised trial. *J Bone Joint Surg Br* 82: 336-339.
6. Singiseti K, Ambedkar M (2010) Nailing versus plating in humerus shaft fractures: a prospective comparative study. *Int Orthop* 34: 571-576.
7. Ward EF, Savoie FH, Hughes JL (1992) Fractures of the diaphyseal humerus. In Browner BD, Jupiter JB, Levine AM, Trafton PG, eds. *Skeletal trauma*. Vol 2. Philadelphia, etc: WB Saunders Co. 1177-1193.
8. Rommens PM, Verbruggen J, Broos PL (1995) Retrograde locked nailing of humeral shaft fractures: A review of 39 patients. *J Bone Joint Surg Br* 77-B: 84-9.
9. Flinkkila T, Hyvonen P, Siira P, Hamalainen M (2004) Recovery of shoulder joint function after humeral shaft fracture: a comparative study between ante grade intramedullary nailing and plate fixation. *Arch Orthop Trauma Surg* 124: 537-41.
10. Demirel M, Turhan E, Dereboy F, Ozturk A (2005) Interlocking nailing of humeral shaft fractures: a retrospective study of 114 patients. *Indian J Med Sci* 59: 436-42.