

Occult Multifocal Thyroid Papillary Carcinoma with Cystic Lymph Nodes Metastases

Bekir Ucan^{1*}, Muhammed Kizilgul¹, Mustafa Ozbek¹, Mustafa Caliskan¹, Güleser Saylam² and Erman Cakal³

¹Department of Endocrinology and Metabolism, Diskapi Teaching and Research Hospital, Ankara, Turkey

²Department of Otolaryngology, Diskapi Teaching and Research Hospital, Ankara, Turkey

³Department of Endocrinology and Metabolism, Ankara University, School of Medicine, Ankara, Turkey

Abstract

Background: Papillary thyroid microcarcinoma presenting as cystic lymphadenopathy as a first and sole sign has rarely been reported. When the nodal metastasis is cystic, with no apparent suspicious thyroid mass on ultrasound (US) it may be misdiagnosed as benign cystic masses. An accurate pre-operative diagnosis is essential since the management of these two conditions is different.

Case report: A 32-year-old woman was referred to our endocrinology outpatient clinic for evaluation of a neck mass. Ultrasonography (USG) showed 3 lymph nodes, the largest one being 6 × 19 × 22 mm (conglomerate lymphadenopathy) in size with a cystic component divided by septa, a complex echo, microcalcifications and undistinguishable echogenic hilum, in the right side adjacent to the carotid artery. However, the thyroid USG has not revealed any abnormality. USG-guided fine-needle aspiration cytology of the cystic lymph node was performed, and cytomorphological findings confirmed a papillary carcinoma derived from the thyroid gland. The patient underwent total thyroidectomy with right lateral and central lymph node dissection. Postoperative histopathology evaluation revealed 3 papillary microcarcinomas in the right lobe, the largest one being 0.4 cm in size and, 2 metastatic lymph nodes.

Conclusion: Ultrasound-guided FNA is a critical step in lymph node metastases. If lymph node FNA cytology and/or needle wash specimens confirm thyroid cancer metastases, total thyroidectomy with central lymph node dissection would be appropriate even if ultrasound did not detect any lesion in the thyroid gland as in the presented case.

Introduction

Papillary thyroid microcarcinoma (PTM) is the most common thyroid malignancy, constituting 50-90% of the differentiated thyroid carcinoma cases. PTM is defined by the World Health Organization (WHO) as papillary thyroid cancer with a diameter of 1.0 cm or smaller [1]. The most common site of metastases for papillary thyroid cancer is the cervical lymph nodes. Cystic degeneration can be observed in approximately 40% of cervical lymph node metastases. While it is not difficult to diagnose solid metastases, lymph node metastases can often be misdiagnosed as benign cystic masses [2,3]. Papillary microcancers of the thyroid glands could potentially cause large-scale cystic lymph node metastases. In some cases, these metastases can be observed as the first unique finding of the microcarcinoma in the thyroid gland [4]. Thyroid papillary cancer metastases can be determined after postoperative histopathological evaluation of cysts that have been subjected to excision for diagnosis. This situation may require secondary surgery and results in loss of time and money. Early diagnosis of metastasis is therefore clinically crucial, as it enables more successful surgery and radioactive iodine treatment. In the following case report, we present a patient with a PTM, who presented with a complicated cystic lesion in the neck.

Case Report

A 32-year-old female patient presented, with a lump in her neck, to our hospital's otorhinolaryngology clinic. Her social and family histories were unremarkable, and she denied smoking or use of any drugs. Physical examination revealed no abnormality other than the presence of right cervical lymph nodes. Neck ultrasonography (USG) showed no abnormality in the thyroid gland, but multiple enlarged lymph nodes were seen on the right cervical side. Computed tomography (CT) of the neck revealed normal thyroid gland as well as the parotid and submandibular glands. In biochemical examination, thyroid stimulating hormone (3.67 mIU/L), free T4 (1.07 ng/dL), anti-

thyroglobulin antibody (24 IU/mL), calcitonin (1.92 pg/mL) and CEA (1.1 mg/L) were normal but anti-thyroid peroxidase antibody was high (619.4 IU/mL) (Table 1). The sizes of the right and left lobes of the thyroid gland were measured as 14 × 12 × 53 mm and 13 × 13 × 38 mm in a detailed thyroid USG performed by our clinic. The parenchyma was seen as slightly heterogeneous. Thyroid real-time ultrasound elastography was performed using a 13 MHz linear transducer (Hitachi® EUB 7000 HV, Japan), by an experienced clinician (EC). Thyroid USG revealed no tumoral mass (Figure 1). Neck USG revealed a 4 × 4 × 7 mm lymphadenopathy without an echogenic hilum, in the left inferior thyroid lodge, a complicated 6 × 19 × 22 mm mass lesion (conglomerate lymphadenopathy) (Figure 2), on the right side adjacent to carotid artery, which had a cystic component divided by septa, a complex echo and microcalcifications and a 9 × 10 × 10 mm lymphadenopathy

Test	Evaluation before surgery	Normal Range
TSH	3.67	0.55-4.78 mIU/L
FreeT4	1.07	0.74-1.52 ng/dL
Anti-TPO	619.4	0-40 IU/mL
Calcitonin	1.92	< 2 pg/mL
CEA	1.1	< 4.6 ng/mL

Table 1: Laboratory data.

*Corresponding author: Bekir Ucan, Diskapi Hospital, İrfan Bastug Caddesi, Ankara, Turkey, Tel: +90 533 940 46 76; E-mail: uzm.dr.bekir@hotmail.com.tr

Received September 20, 2017; Accepted October 26, 2017; Published October 30, 2017

Citation: Ucan B, Kizilgul M, Ozbek M, Caliskan M, Saylam G, et al. (2017) Occult Multifocal Thyroid Papillary Carcinoma with Cystic Lymph Nodes Metastases. Endocrinol Metab Syndr 6: 276. doi:10.4172/2161-1017.1000276

Copyright: © 2017 Ucan B, et al. This is an open-access article distributed under the terms of the Creative Commons Attribution License, which permits unrestricted use, distribution, and reproduction in any medium, provided the original author and source are credited.

including non-echogenic hilum and microcalcifications. An I¹³¹ thyroid scintigraphy was performed to understand whether the patient's lesions were due to thyroid metastasis. In the thyroid scintigraphy, I¹³¹ uptake was not seen in the tissue at the lower right jugular region. First thyroid fine needle aspiration cytology (FNAB) of the cystic component in the right inferior jugular region was reported as suspicious cytology. Therefore, FNAB has performed again, and the result reported as "malignant cytology. Cytomorphological findings of the tumor confirmed a papillary carcinoma derived from the thyroid gland. At this point, the endocrinology-surgery council decided to perform a total thyroidectomy with central and right lateral cervical lymph node dissection. The postoperative histopathology evaluation revealed 3 papillary microcarcinomas in the right lobe, the largest one being 0.4 cm in size (Figures 3 and 4). Moreover, 1 metastatic lymph node in the central compartment, one metastatic lymph node at level IIA, non-tumoral lymph nodes at level III and non-tumoral lymph nodes at level IV were detected. Radioactive iodine (RAI) ablation therapy was performed to the patient. Her last thyroglobulin level was <0.20 ng/mL. Radioiodine whole-body scintigraphy (WBS) after RAI ablation was normal. Currently, she is in remission and undergoes follow-up care at our outpatient clinic.

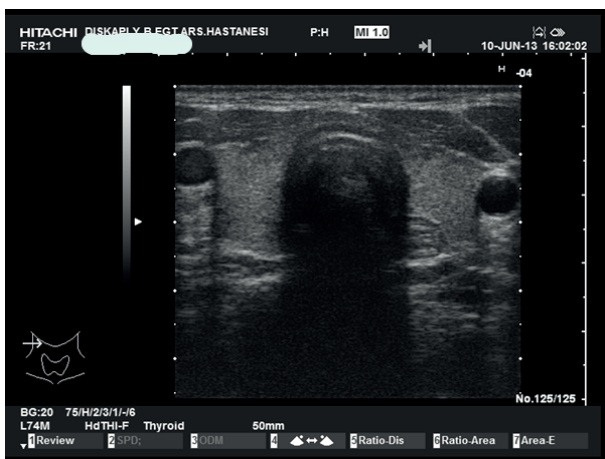


Figure 1: Normal thyroid ultrasonography.

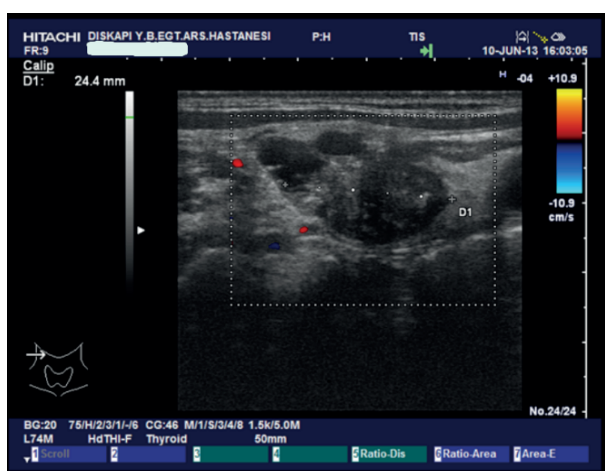


Figure 2: A heterogenous cystic lymph node with features of 6 × 19 × 22 mm in diameter and calcifications was demonstrated in the right inferior cervical region.

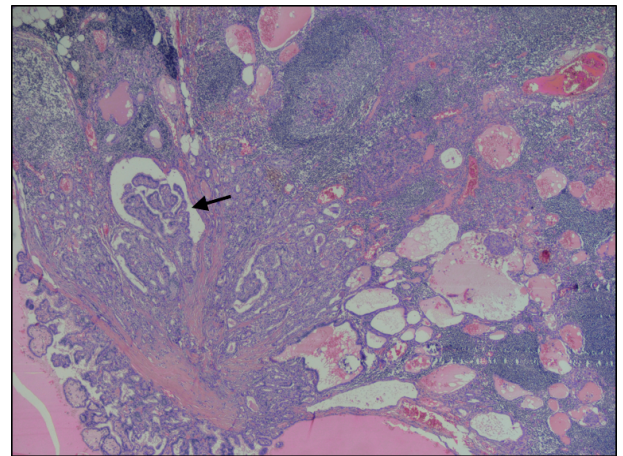


Figure 3: Hematoxylin and eosin stained sections of the tumor. Black arrow shows thyroid papillary cancer cells.

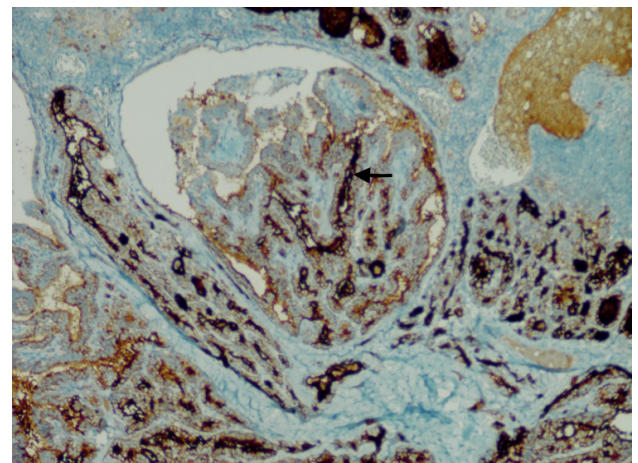


Figure 4: Thyroidectomy specimen demonstrated heterogeneous positive immunoreactivity to thyroglobulin (Black arrow).

Discussion

Metastatic lymph nodes in the head and neck regions are seen as solid masses. Cystic lymph node metastases are rarely observed and develop as a result of subcortical liquefaction necrosis. They often arise from squamous cell cancers, metastases of thyroid papillary cancers or primary bronchogenic types of cancer. Papillary microcarcinomas or occult papillary tumors are presented for the first time as cervical metastases are extremely rare [4-5]. A lateral cystic cervical mass identified in a person under the age of forty, without any risk factors for thyroid cancer, should be considered to be originated from the thyroid gland.

There are different results regarding the incidence of cystic metastases of the thyroid papillary cancers in the literature. One study reported that approximately 10% of lateral-located cervical cyst cases in patients who had undergone surgery for thyroid cancer were found to be papillary cancer metastasis [6]. There was no nodule detected in the thyroid gland by our careful analysis despite the presence of a cystic lymph nodule in the cervical region. In the literature review, cystic metastases of the thyroid papillary cancer were rarely seen, and

there were very few cases with no apparent suspicious thyroid mass. Verge reported seven cases similar to our case [4]. In all cases, thyroid tumors were not palpable on physical examination and other diagnostic procedures were not able to show any abnormality in the thyroid gland.

Neck USG is one of the most frequently used imaging methods to evaluate masses in the neck. The sensitivity of neck USG in assessing the pathologies of lymph nodes is approximately 97% while its specificity is 32% [7]. This specificity rate increases to 93% when applied together with FNAB. In USG, solitary lateral cervical cystic masses may frequently be misdiagnosed as bronchial cysts and a simple excision is being implemented to these masses. The differential diagnosis of thyroid papillary cancer metastasis as a rare cause should be kept in mind before these interventions are applied to these patients. One study reported that microcalcification and cystic degeneration in cervical lymph nodes are highly suggestive of metastases [8]. In our case, the presence of cystic degeneration and micro-macrocalcifications arose suspicion that the mass could be malignant. The cells appearing as thyrocyte in FNAB gave rise to the thought that the source of the cervical mass might be the thyroid gland. Since there are microscopic findings related the thyroid in the FNAB, thyroglobulin in washout fluid from lymph node was not performed. Since the appearance of cervical lymph nodes is highly suggestive of metastases, the second biopsy was performed after first FNAB revealed a suspicious cytology. Cytomorphological findings of the tumor confirmed a papillary carcinoma derived from the thyroid gland in the repeated biopsy.

Ultrasonography sometimes cannot be able to detect microcancers. Nasopharyngeal cancer should be considered in the differential diagnoses of these forms of suspicious lymph nodes. In these patients, nasopharyngeal cancer should be ruled out to prevent tumor seeding after diagnostic fine needle aspiration biopsy. If lymph node fine-needle aspiration cytology confirms thyroid cancer metastases, total thyroidectomy should be performed even in the absence of any lesion in the thyroid gland. Ultrasonography was not able to detect any thyroid lesion in our case. Postoperative pathological evaluation of tissue samples revealed three lesions smaller than 5 mm. Even though these patients normally are considered to have an excellent prognosis, some multifocal microcancer may have significant lymph node metastases. Total thyroidectomy with central lymph node dissection should be performed in these patients as in the case reported by Tastekin [9].

Surgical removal of the cystic lymphadenopathy with intraoperative pathology evaluation to confirm the diagnosis followed by lymph node dissection and total or subtotal thyroidectomy could be a different treatment option [4].

All seven patients reported by Verge J, were subsequently treated

with ^{131}I and were in remission at a follow-up period of one to seven years [4]. Currently, our patient is in remission and undergoes follow-up care at our outpatient clinic.

As a result of our findings, it should be kept in mind that a lateral cervical cystic mass identified in young patients may be due to cystic lymph node metastasis of thyroid papillary microcarcinoma. Even if ultrasonography was not able to reveal any thyroid pathology, papillary microcarcinoma should be taken into consideration as the source.

Conclusion

Cervical lymph node with cystic degeneration in a young patient might be suggestive of metastatic papillary thyroid carcinoma. After a diagnosis of thyroid cancer, total thyroidectomy with central lymph node dissection followed by radioactive iodine therapy provides a favorable prognosis.

Conflict of Interests

The authors declare that there is no conflict of interests regarding the publication of this paper.

References

1. Noguchi S, Yamashita H, Uchino S, Watanabe S (2008) Papillary microcarcinoma. *World J Surg* 32: 747-753.
2. King AD, Ahuja AT, To EW, Tse GM, Metreweli C (2000) Staging papillary carcinoma of the thyroid: magnetic resonance imaging vs. ultrasound of the neck. *Clin Radiol* 55: 222-226.
3. Ahuja A, Ng CF, King W, Metreweli C (1998) Solitary cystic nodal metastasis from occult papillary carcinoma of the thyroid mimicking a branchial cyst: a potential pitfall. *Clin Radiol* 53: 61-63.
4. Verge J, Guixa J, Alejo M, Basas C, Quer X, et al. (1999) Cervical cystic lymph node metastasis as first manifestation of occult papillary thyroid carcinoma: Report of seven cases. *Head Neck* 21: 370-374.
5. Hwang CF, Wu CM, Su CY, Cheng L (1992) A long-standing cystic lymph node metastasis from occult thyroid carcinoma-report of a case. *J Laryngol Otol* 106: 932-934.
6. Seven H, Gurkan A, Cinar U, Vural C, Turgut S (2004) Incidence of occult thyroid carcinoma metastasis in lateral cervical cysts. *Am J Otolaryngol* 25: 11-17.
7. Kessler A, Rappaport Y, Blank A, Marmor S, Weiss J, et al. (2003) Cystic appearance of cervical lymph nodes is characteristic of metastatic papillary thyroid carcinoma. *J Clin Ultrasound* 31: 21-25.
8. Rosário PW, Tavares WC, Borges MA, Santos JB, Calsolari MR (2014) Ultrasonographic differentiation of cervical lymph nodes in patients with papillary thyroid carcinoma after thyroidectomy and radioiodine ablation: a prospective study. *Endocr Pract* 20: 293-298.
9. Tastekin E, Can N, Ayturk S, Celik M, Ustun F, et al. (2016) Clinically Undetectable Occult Thyroid Papillary Carcinoma Presenting with Cervical Lymph Node Metastasis. *Acta Endo (Buc)* 12: 72-76.