

## Objective Evaluation of Zonular Weakness: Measurement of Lens Movement at the Start of Capsulorhexis Using Extracted Porcine Eyes

Yukari Yaguchi<sup>1,2</sup>, Shigeo Yaguchi<sup>3\*</sup>, Saori Yaguchi<sup>2,4</sup>, Tadahiko Kozawa<sup>3</sup>, Yuichiro Tanaka<sup>3</sup>, Kazuno Negishi<sup>2</sup> and Kazuo Tsubota<sup>2</sup>

<sup>1</sup>Department of Ophthalmology, Tokyo Dental College, Ichikawa General Hospital, Chiba, Japan

<sup>2</sup>Department of Ophthalmology, Keio University School of Medicine, Tokyo, Japan

<sup>3</sup>Kozawa Eye Hospital and Diabetes Center, Mito, Japan

<sup>4</sup>Department of Ophthalmology, Tokyo Dental College Suidobashi Hospital, Tokyo, Japan

\*Corresponding author: Shigeo Yaguchi, Kozawa Eye Hospital and Diabetes Center 246, Yoshizawa-Cho, Mito-City, Ibaraki Pref, 310-0845, Japan, Tel: +81-29-246-2111; Fax: +81-29-304-5111; E-mail: yaguchis@hotmail.co.jp, [yaguchi@kozawa-ganka.or.jp](mailto:yaguchi@kozawa-ganka.or.jp)

Received date: March 14, 2016; Accepted date: April 22, 2016; Published date: April 24, 2016

Copyright: © 2016 Yaguchi Y, et al. This is an open-access article distributed under the terms of the Creative Commons Attribution License, which permits unrestricted use, distribution, and reproduction in any medium, provided the original author and source are credited.

### Abstract

**Objective:** To evaluate the degree of zonular weakness based on lens movement at the start of capsulorhexis using extracted porcine eyes.

**Methods:** Zonular dehiscence of 18°, 36°, and 54° was created and alternated with healthy areas into five zones to create a model simulation of weakness of the zonule of Zinn corresponding to dehiscence of 90°, 180°, and 270°. During continuous curvilinear capsulorhexis (CCC), an image displaying the anterior capsule grasped by a cystotome and another displaying the initial tear were captured, and the two images were superimposed to measure the movement distance of the cortical opacities created using a hook. Porcine eyes with no dehiscence were used as the control group.

**Results:** Compared with a distance of 0.44 ± 0.13 mm in the control group, the cortical opacity movement distances in the weakness group with dehiscence corresponding to 90°, 180°, and 270° were 0.68 ± 0.27, 1.01 ± 0.22, and 1.32 ± 0.35 mm, respectively. Significant differences were observed between the control, 90°, 180°, and 270° dehiscence groups (P<0.001).

**Conclusion:** This study revealed numerical data for the degree of weakness of the zonule of Zinn in porcine eyes. Clinical application of this method may be useful for establishing surgical procedures and prognoses for cataract surgery in patients with weakness of the zonule of Zinn.

**Keywords:** Objective classification; Zonular weakness; Capsulorhexis; Porcine eye

### Introduction

During cataract surgery using phacoemulsification and aspiration (PEA), if the zonule of Zinn is healthy and appropriately supports the lens, then fragmentation and emulsification of the lens nucleus using ultrasound followed by in-the-bag intraocular lens (IOL) fixation can be safely performed. However, in cases of weakness of the zonule or partial dehiscence, the lens capsule moves along with the lens nucleus, often making it difficult to effectively perform nucleus rotation within the capsule, nucleus division, and removal of nuclear fragments from inside the capsule. Forcing these manipulations can cause zonular dehiscence and posterior capsule rupture, increasing the risk of complications, such as nucleus drop and vitreous loss. In patients with weakness of the zonule, even if PEA and in-the-bag IOL fixation are safely performed to complete the surgery, capsule contraction syndrome (CCS), occluded pupil, and in-the-bag dislocation can occur postoperatively [1-3]. Weakness of the zonule can be caused by various factors, including aging, pseudoexfoliation syndrome (PE), Marfan syndrome, retinitis pigmentosa, post-laser iridotomy, atopic dermatitis, and external injury [2,4-8]. Of these, PE is the most common cause of

weakness of the zonule [9]. In 1987, Skuta et al. reported that during extracapsular cataract extraction in patients with PE, excessive lens movement during capsulotomy is four times more likely to cause zonular dehiscence than that in patients without PE [10]. During PEA, which is currently the mainstream surgical procedure for cataracts, weakness of the zonule is also suspected if puncture of the anterior capsule is difficult due to lens movement when performing CCC, which often makes subsequent PEA difficult. Properly ascertaining the condition of the zonule is crucial to cataract surgery and is a factor that influences whether the surgery can be conducted safely.

Here we focused on lens movement at the commencement of CCC as an indicator of weakness of the zonule. We previously found that classifying the weakness of the zonule on the basis of the degree of movement is useful in the selection of the surgical procedure and during decision making regarding the use of capsular fixation devices during PEA. However, classification of the weakness of the zonule is subjective, as lens movement is determined by visual observation, and the degree to which this reflects zonular weakness is unknown [11]. In the present study, we report a method of measuring the lens movement distance using zonular weakness models created from extracted porcine eyes. We also investigated the relationship between the lens movement distance and degree of weakness of the zonule in terms of dehiscence.

## Experimental Method

### Creating a model of weakness of the zonule of Zinn

Using freshly extracted porcine eyes, we first displaced the anterior chamber using an ophthalmic viscoelastic device (OVD; Healon; Abbott Medical Optics, Santa Ana, CA, USA), inserted a diathermy CCC probe (OS3; Oertli Instruments, Berneck, Switzerland) into the side port, coagulated and dissected the iris root using the diathermy, and then completely removed the iris. The conditions employed for coagulation and dissection were DIA, 8 W, 50  $\Omega$ , 500 Hz, and we used the height frequency cut capsule mode. Next, we created partial zonular dehiscence alternating with healthy areas to create a simulated model of weakness of the zonule. The areas of zonular dehiscence were set at 90°, 180°, and 270°, with 18° of dehiscence alternated with 54°

healthy areas in five areas, 36° dehiscence alternated with 36° healthy areas in five areas, and 54° dehiscence alternated with 18° healthy areas in five areas, respectively. The method of creating zonular dehiscence involved using a specially manufactured marker to indicate the areas of dehiscence and to mark the corneal limbus, after which the tip of the probe was placed in the gap between the lens equator and the ciliary process. Diathermy was then used to coagulate and dissect the zonule to create the dehiscence (Figure 1), which was created under the same conditions as those for the iris dissection. Zonular dehiscence was created at 90°, 180°, and 270° and these models were designated to the weakness group. These were compared with no dehiscence was created (control group). Pressure was applied to the anterior surface of the lens using a Sinsky hook to create a cortical opacity, which served as a visual marker.



**Figure 1:** Induction of zonular weakness (180° dehiscence) models. After marking 36° intervals on the corneal limbus (\*), a diathermy probe was inserted into the anterior chamber (left). The tip was inserted between the lens equator and the ciliary process to sever the zonule of Zinn (right). The arrows indicate where the equator is exposed.


### First puncture of the anterior capsule

The first puncture of the anterior capsule upon commencement of CCC was performed with either a cystotome or a capsule forceps using a 27-gauge needle bent at a right angle 0.2 mm from the tip and a capsulorhexis forceps (FR2268S; Eye Technology, Rayleigh, Essex, UK), respectively. After filling the anterior chamber with the OVD, the cystotome or capsule forceps were inserted from the side port at a 4 o'clock direction from the site of operation and commenced from a site approximately 3 mm from the equator in a 10 o'clock direction. The method for the first puncture was to grasp the surface of the anterior capsule with the needle tip in a hooking motion and then pull back in parallel to the equator to tear the anterior capsule. For each eye, punctures were made at 2-4 different sites, and the lens movement distance was measured for each puncture.

### Measuring the lens movement distance with the overlay method

Video footage from the dissection of the anterior capsules was captured using Windows Live Movie Maker and played frame-by-

frame with an interval of 0.033 s. Two still images were created: when the anterior capsule was grasped and when the puncture was made. Illustration software (Illustrator<sup>®</sup>CC 2015; Adobe, San Jose, CA, USA) was used to trace the cortical opacity, needle, corneal limbus contour, and conjunctival pigments in the still images with dotted lines (Figure 2A) and solid lines (Figure 2B). The dotted lines from Figure 2A were superimposed over the solid lines of Figure 2B while using the corneal limbus contour and conjunctival pigments to align the images. The movement distance of the cortical opacity and needle are represented as the misalignment between the dotted and solid lines (Figure 2C). The superimposed images were imported into Microsoft Office Excel (free application) to measure the movement distance of the cortical opacity (Figure 2D). Then, the cortical opacity movement distance from when the anterior capsule was grasped to when the first puncture was made (i.e., the lens movement distance) was measured.



**Figure 2:** Measurement of lens movement distance using the overlay method. The images show weakness in the form of a 180° dehiscence. Still images were captured when the anterior capsule was grasped (A) and when the first tear was created (B); then, the cortical opacity, needle, pupil contour, and conjunctival pigmentation were each traced using dotted (A) and solid (B) lines. The dotted lines from (A) were superimposed onto (B), and proper positioning was adjusted by the pupil and pigmentation. The difference between the dotted and solid lines represents the lens movement distance (C). The needle thickness (red line) was matched at 0.4 mm to measure the movement distance (white line) (D).

### Statistical methods

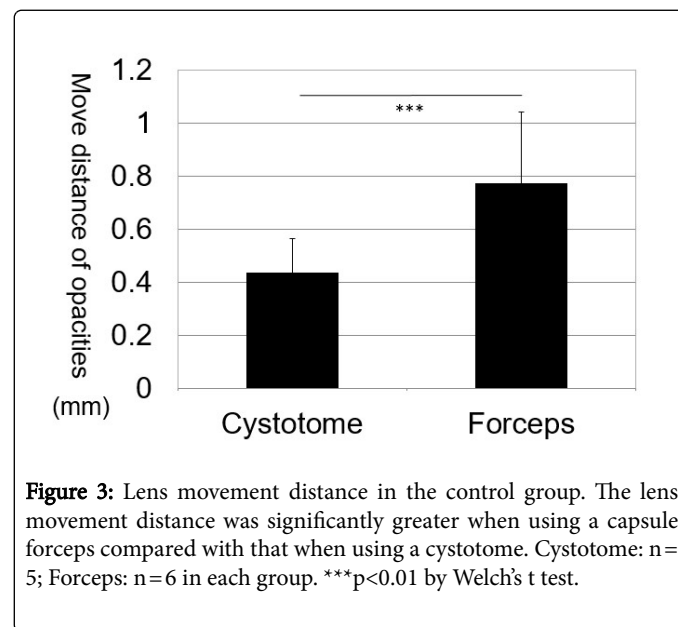
The Welch's t test was used to compare the lens movement distance between cystotome and capsule forceps.

The Kruskal-Wallis test was used to compare the lens movement distance between the groups of zonular weakness groups, and the Dunn's Multiple Comparison Test was used for further pairwise comparisons.

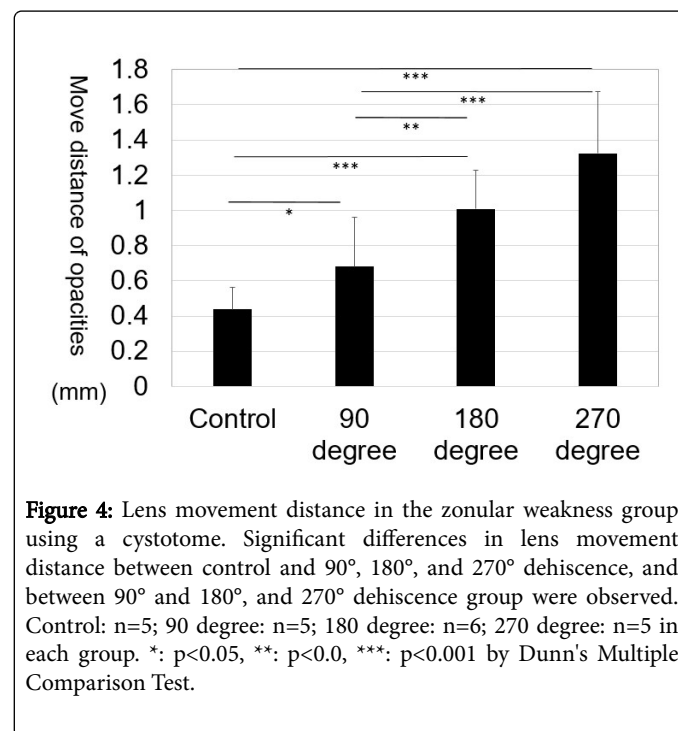
### Results

We compared the lens movement distance upon commencement of CCC within the control group. A significant difference was observed in the lens movement distance when using the cystotome ( $0.44 \pm 0.13$  mm) compared with when using the capsule forceps ( $0.77 \pm 0.27$  mm;  $P < 0.001$ ) (Figure 3). Next, we compare the lens movement distance in the control and weakness groups for the different levels of dehiscence in the eyes for which the cystotome had been used. The lens movement distances were  $0.44 \pm 0.13$  mm,  $0.68 \pm 0.28$  mm,  $1.01 \pm 0.22$  mm, and  $1.32 \pm 0.35$  mm at control, 90°, 180°, and 270° dehiscence, indicating significant differences between 4 groups ( $p < 0.001$ ). Pairwise comparisons show that significant difference between control and 90° ( $p < 0.05$ ), control and 180° ( $p < 0.001$ ), and control and 270° ( $p < 0.001$ ), 90° and 180° ( $p < 0.01$ ), and 90° and 270° ( $p < 0.001$ ) (Figure 4). Further, the movement distances with the capsule forceps were  $0.77 \pm 0.27$ ,  $1.05 \pm 0.20$ ,  $1.27 \pm 0.34$ , and  $2.28 \pm 1.33$  mm at control, 90°, 180°, and 270° dehiscence, indicating significant differences between 4 groups ( $p < 0.001$ ). Pairwise comparisons show that significant difference

between control and 90° ( $p < 0.01$ ), control and 180° ( $p < 0.001$ ), and control and 270° ( $p < 0.001$ ), and 90° and 270° ( $p < 0.001$ ) (Figure 5). There is a tendency that the lens movement distances with cystotome and capsule forceps became longer, as the degree of dehiscence increased.



**Figure 3:** Lens movement distance in the control group. The lens movement distance was significantly greater when using a capsule forceps compared with that when using a cystotome. Cystotome: n=5; Forceps: n=6 in each group. \*\*\* $p < 0.01$  by Welch's t test.

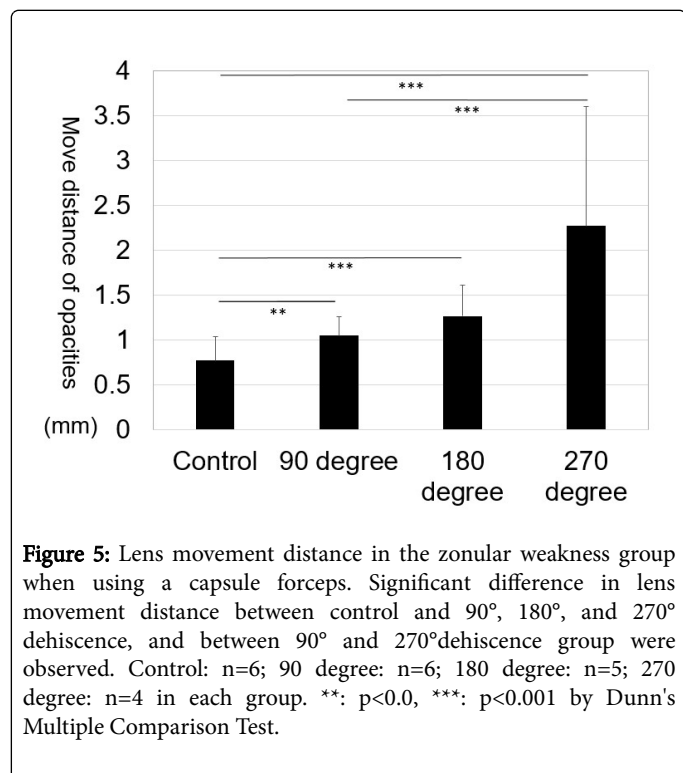


**Figure 4:** Lens movement distance in the zonular weakness group using a cystotome. Significant differences in lens movement distance between control and 90°, 180°, and 270° dehiscence, and between 90° and 180°, and 90° and 270° dehiscence group were observed. Control: n=5; 90 degree: n=5; 180 degree: n=6; 270 degree: n=5 in each group. \*:  $p < 0.05$ , \*\*:  $p < 0.01$ , \*\*\*:  $p < 0.001$  by Dunn's Multiple Comparison Test.

### Discussion

The zonule of Zinn comprises fine fibrous threads connecting the ciliary body with the lens. These fibers support the lens and convey changes accompanying the contraction and relaxation of the ciliary body to the lens, thereby controlling the lens. The fibers of the zonule, known as microfibrils, have a diameter of 10 nm, a tubular structure

and are arranged in bunches of filaments. These fibers possess characteristics similar to those of elastin fibers and are highly resilient. It is difficult to clinically determine the resilience or strength of the zonule in human eyes, but experiments using domestic rabbits have approximated that eight times of the intraocular pressure in a normal eye (155 mmHg) is required to make dehiscence by pushing posteriorly [12]. When performing CCC, if the zonule is healthy, the lens either moves barely or not at all due to its high resilience and strength; however, weakness may be indicated if there is significant movement and the first puncture is difficult to make [13,14].



**Figure 5:** Lens movement distance in the zonular weakness group when using a capsule forceps. Significant difference in lens movement distance between control and 90°, 180°, and 270° dehiscence, and between 90° and 270°dehiscence group were observed. Control: n=6; 90 degree: n=6; 180 degree: n=5; 270 degree: n=4 in each group. \*\*: p<0.0, \*\*\*: p<0.001 by Dunn's Multiple Comparison Test.

We believe that lens movement during CCC is an important finding that indicates the presence of zonular weakness. A classification system was previously reported for the weakness of the zonule based on the degree of lens movement upon commencement of CCC: normal (N), little-to-no movement; weak (W), some movement; and very weak (VW), strong movement. Iris retractors and capsule expanders can be used to safely perform PEA by fixing the corneal limbus to the CCC margin to stabilize the lens capsule, and the usage frequency of these devices has been compared among these groups [1, 15-17]. The results revealed that an iris retractor and capsule expander were used in 0.16% of cases in group N, 27.5% in group W, and 92.7% in group VW, indicating a higher rate of usage with stronger lens movement. These results suggest that this classification system could be used as a guide for deciding whether to use these devices to stabilize the capsule. Moreover, increases in the proportions of intracapsular cataract extractions and IOL scleral fixations corresponding with increases in the classification grade severity suggest that this classification system accurately reflects the degree of weakness.

In the present study, we created partial zonular dehiscence in extracted porcine eyes and used them as models of weakness of the zonule during CCC to investigate the direct relationship between lens movement and the area of dehiscence. We used the overlay method to

measure the movement distance, superimposing a still image from the moment the anterior capsule was grasped onto another image depicting the moment of the first tear. The lens movement distance upon commencement of CCC was shown to strongly correlate with the area of zonular dehiscence, validating the use of this measurement method in clinical cases to determine the degree of weakness of the zonule. Although the differences between the zonule in human eyes and our porcine eye model prevent our results from being directly applied in clinical settings, N samples are considered too broadly correspond to the control group, W samples to the 90°-180° dehiscence group, and VW samples to the 270° dehiscence group. In particular, strong lens movement when using forceps in the 270° dehiscence group at times prevented the creation of a tear. The inability to create a tear due to lens movement is also experienced in the clinical setting and corresponds to the VW group. In these cases, the anterior chamber is filled with Healon 5° (Abbott Medical Optics), which restrains the lens, and thus enables the creation of the puncture with the cystotome.

A limitation of the present study is that the zonular weakness models in the porcine eyes that we used do not accurately represent the zonule in human eyes. The fibers of the zonule weaken as a result of changes due to aging. Compared with the density of the zonular fibers in young individuals, those in the elderly become fine, lose density, and dehisce easily. In patients with PE, countless granular flakes can be seen on the zonule [4]. Weakness of the zonule is caused by the prevalence of lysosomes during desquamation; hydrolases in the lysosomes break down the zonule, which causes thinning of the zonular fibers and results in interspersed areas of dehiscence. Adherence of desquamated material and changes in dehiscence can be observed using ultrasound biomicroscopy [18]. Ritch et al. demonstrated that the results of ultrasound biomicroscopy match those of surgical and clinical reports, making them useful for surgical planning and determining PE severity, which cannot be ascertained with a slit lamp [19]. Zonular fibers are firmly attached to the surface of the lens chamber and the pigment epithelial cells of the ciliary body; however, this attachment weakens in PE, which is thought to be the cause of zonular weakening [20]. This state of weakness of the zonule in human eyes is difficult to reproduce in porcine eyes [18]. In the current study, we created partial zonular dehiscence alternating with healthy areas in five zones to form a simulated model of weakness. The zonule is colorless and transparent, making gross observation of its structure difficult. We dissected the iris to enable direct observation of the lens equator and ciliary process and used this as a guide to decide on the area of dehiscence to create. Using diathermy designed for CCC, we coagulated the zonule between the lens equator and the ciliary process and used a blunt needle with the tip bent at a right angle to confirm whether the zonule had completely separated from the lens equator or dehisced. Although we were concerned that the adjacency of the CCC site to dehiscent or healthy areas could influence lens movement distance, the results showed that there was no effect if the site was separated from the capsule equator by  $\geq 3$  mm. In the future, we believe that studies using models of weakness of the zonule with more than five areas of dehiscence are necessary.

Moreover, certain properties of the lens capsule differ between porcine and human eyes. Compared with an adult human eye, the lens capsule in a porcine eye is more resilient and also shows stronger resistance to dissection. Therefore, we expect these measurement values in clinical surgery cases to be shorter.

When measuring the lens movement distance, cortical opacity is used as an indicator to determine how far the zonule of Zinn has

stretched (i.e., the degree of weakness of the zonule). Before measuring the lens movement distance in the zonular weakness group, we confirmed that there was no statistical difference in the lens movement distance, when measured by cortical opacities within 1-3 mm from the needle tip (Data not shown). Therefore, we decided to use cortical opacities within 1-3 mm from the needle tip as indicators for measuring the movement distance.

Finally, the lens movement distance varies depending on the CCC method. When using a cystotome, numerous factors influence the outcome, including the length and angle of the tip and the degree of pressure applied when compressing the anterior chamber. In the current study, after filling the anterior chamber, we performed CCC with a cystotome created with a short, right-angle bend in the tip of a 27-gauge needle. First, we applied gentle pressure to the surface of the anterior capsule, ensuring that the tip was not swallowed up by the anterior capsule. Next, preserving the anterior capsule, we pulled the tip of the needle parallel with the equator and made an initial tear. We captured still images of the preservation of the anterior capsule and the moment the tear was created and used these for the measurements. Although we could have bent the needle at a 30° angle and used the flat part instead of a scalpel to directly dissect the anterior capsule, we wanted to be careful not to perform a dissection. A single operator performed the procedures under these standard conditions, and thus, we believe that there was a significant difference among the areas of dehiscence as shown by the movement distance measurements. When the capsule forceps was used, the measured movement distance was longer. We consider this to be due to the tip of the needle being slightly more blunt compared with that of a cystotome.

Future challenges include the quantification of the weakness of the zonule in clinical cases. The measurement of the movement distance is applicable to actual surgery on human eyes. When applied clinically, this may be a useful quantitative evaluation method for weakness of the zonule. Diseases and conditions, such as PE and retinitis pigmentosa, and post-laser iridotomy can cause weakness of the zonule; however, the degree of weakness varies between individual cases, and the zonule is quite often healthy. The use of the quantification method reported in this study will enable the proportions and distribution of degrees of weakness for each disease to be numerically expressed and could be useful for not only selecting surgical procedures but also investigating the relationship with postoperative CCS and IOL dislocation.

In conclusion, we created partial, alternating zonular dehiscence in extracted porcine eyes as a model of weakness of the zonule of Zinn, using them to perform CCC and devising an overlay method to measure the lens movement distance upon commencement of CCC. Upon investigating the relationship between the movement distance and the area of dehiscence (i.e., the degree of weakness of the zonule), the movement distance increased with an increase in the area of dehiscence, indicating the ability to numerically express the degree of weakness of the zonule. Applying this method in a clinical setting may assist in the selection of a surgical method for cataract surgery in cases with weakness of the zonule of Zinn and in the determination of postoperative prognosis.

## References

1. Tsinopoulos I, Symeonidis C, Frangou E, Dimitrakos SA (2008) Capsule contraction syndrome in eight cases of hydrophobic one-piece intraocular lens implantation. *Clin Exp Optom* 91: 469-472.
2. Venkatesh R, Tan CS, Veena K, Ravindran RD (2008) Severe anterior capsular phimosis following acrylic intraocular lens implantation in a patient with pseudoexfoliation. *Ophthalmic Surg Lasers Imaging* 39: 228-229.
3. Davis D, Brubaker J, Espandar L, Stringham J, Crandall A, et al. (2009) Late in-the-bag spontaneous intraocular lens dislocation: evaluation of 86 consecutive cases. *Ophthalmology* 116: 664-670.
4. Bron AJ (1997) *The Ciliary Zonule: Wolff's Anatomy of the Eye and Orbit*. Chapman & Hall, London.
5. Raitta C, Setälä K (1986) Intraocular lens implantation in exfoliation syndrome and capsular glaucoma. *Acta Ophthalmol (Copenh)* 64: 130-133.
6. Ladewig MS, Robinson PN, Neumann LM, Holz FG, Foerster MH (2006) Ocular manifestations and surgical results in patients with Marfan syndrome. *Ophthalmologie* 103: 777-782.
7. Mackool RJ (2009) Argon laser iridotomy and crystalline lens dislocation. *J Cataract Refract Surg* 35: 1323.
8. Peter NM, Nath R, Tranos PG, Teimory M (2005) Bilateral lens subluxation associated with atopic eczema. *Eur J Ophthalmol* 15: 409-411.
9. Canavan YM, Archer DB (1982) Anterior segment consequences of blunt ocular injury. *Br J Ophthalmol* 66: 549-555.
10. Skuta GL, Parrish RK 2nd, Hodapp E, Forster RK, Rockwood EJ (1987) Zonular dialysis during extracapsular cataract extraction in pseudoexfoliation syndrome. *Arch Ophthalmol* 105: 632-634.
11. Yaguchi S, Yaguchi S, Asano Y, Aoki S, Hamakawa M, et al. (2015) Categorization and surgical techniques of weak zonule based on findings at capsulorhexis during cataract surgery. *J Clin Exp Ophthalmol* 6: 407.
12. Ross R, Bornstein P (1969) The elastic fiber. I. The separation and partial characterization of its macromolecular components. *J Cell Biol* 40: 366-381.
13. Isao S, Ohki K, Machi N (1991) Attempt to the measurement of the tension of Zonular fibers—Influence to the lens suspensory apparatus when the lens was vertically displaced by pushing posteriorly. *Nippon Ganka Kaishi* 95: 1037-1043.
14. Hoffman RS, Snyder ME, Devgan U, Allen QB, Yeoh R, et al. (2013) ASCRS Cataract Clinical Committee; Challenging/Complicated Cataract Surgery Subcommittee: Management of the subluxated crystalline lens. *J Cataract Refract Surg* 39: 1904-1915.
15. Merriam JC, Zheng L (1997) Iris hooks for phacoemulsification of the subluxated lens. *J Cataract Refract Surg* 23: 1295-1297.
16. Yaguchi S (2004) Capsule expander. *IOL&RS*; 18: 82-83.
17. Nishimura E, Yaguchi S, Nishihara H, Ayaki M, Kozawa T (2006) Capsular stabilization device to preserve lens capsule integrity during phacoemulsification with a weak zonule. *J Cataract Refract Surg* 32: 392-395.
18. Schlötzer-Schrehardt U, Naumann GO (1994) A histopathologic study of zonular instability in pseudoexfoliation syndrome. *Am J Ophthalmol* 118: 730-743.
19. Inazumi K, Takahashi D, Taniguchi T, Yamamoto T (2002) Ultrasound biomicroscopic classification of zonules in exfoliation syndrome. *Jpn J Ophthalmol* 46: 502-509.
20. Ritch R, Vessani RM, Tran HV, Ishikawa H, Tello C, et al. (2007) Ultrasound biomicroscopic assessment of zonular appearance in exfoliation syndrome. *Acta Ophthalmol Scand* 85: 495-499.