

Nutraceutical Properties and Safety Evaluation of Fruits and Arrope of *Geoffroea decorticans* (Chañar)

Reynoso MA^{1*}, Sánchez Riera A¹ and Vera NR²

¹Cátedra de Farmacodinamia. Facultad de Bioquímica, Química y Farmacia, Universidad Nacional de Tucumán, Ayacucho 471, 4000, Tucumán, Argentina

²Cátedra de Farmacoquímica. Facultad de Bioquímica, Química y Farmacia, Universidad Nacional de Tucumán, Ayacucho 471, 4000, Tucumán, Argentina

*Corresponding author: Reynoso MA, Cátedra de Farmacodinamia. Facultad de Bioquímica, Química y Farmacia, Universidad Nacional de Tucumán, Ayacucho 471, 4000, Tucumán, Argentina, Tel: 54 381 424-7752; Fax: 54 0381 4293071; E-mail: mareynosofbqf@hotmail.com

Received date: Mar 01, 2016; Accepted date: Mar 25, 2016; Published date: Mar 31, 2016

Copyright: © 2016 Reynoso MA, et al. This is an open-access article distributed under the terms of the Creative Commons Attribution License, which permits unrestricted use, distribution, and reproduction in any medium, provided the original author and source are credited.

Abstract

Context: *Geoffroea decorticans* (chañar) fruits and its derivate product (arrope) have been traditionally used as food and in folk medicine for the treatment of a wide variety of diseases including bronchopulmonary disorder.

Objective: The objective of this study is to evaluate the antitussive, expectorant and anti-inflammatory effects and safety of aqueous extract (AE) and arrope (Ar) of chañar.

Materials and methods: The anti-inflammatory activity of AE and Ar was evaluated through carrageenan induced edema and cotton pellet-induced granuloma formation in rats. The antitussive activity was evaluated using model against ammonia induced cough in rats. The expectorant activity was evaluated by volume of phenol red in rat's tracheas. The tested doses of extracts were of 250, 500 and 1000 mg/kg, (p.o.). For the safety evaluation of AE and Ar, was conducted the subchronic toxicity test in rats (1 g/kg and 2 g/kg, p.o.).

Results: The results showed that AE (1000 mg/Kg) significantly reduced the edema (100%) induced by carrageenan 3 h post-dosing and granuloma formation (47.76%) induced by cotton pellets. In the ammonia liquor induced cough and the amount of phenol red secretion, AE and Ar of chañar (1000 mg/kg) significantly enhanced the latent period of cough, inhibited the cough frequency and significantly enhance tracheal phenol red compared with that negative control. The result of toxicity assays suggested that AE and Ar did not induce or cause any damage to the liver and kidney of the rats and can be considered nontoxic for these animals at tested doses.

Discussion and conclusion: This study has shown that the AE and Ar possess antitussive and expectorant significant effect. Also AE possess significant anti-inflammatory effects, both extracts were nontoxic. These findings seem to justify use of the plant in traditional medicine and are proposed, the chañar fruits as an excellent nutraceutical.

Keywords: Antitussive; Expectorant; Anti-inflammatory; Sub chronic toxicity; Nutraceutical

Introduction

Cough and inflammation are one of more common symptoms associated with many respiratory diseases such as asthma, chronic bronchitis, and pneumonia and lung cancer. Control of cough remains a major unmet medical need and, although the centrally acting opioids have remained the antitussive drug of choice for decades, they possess many unwanted side effects such as sedation and gastrointestinal symptoms [1].

Therefore, there is a growing demand for the search of medicine in the treatment of cough and respiratory diseases. In the traditional medicine of Argentina, many medicine herbs are used for hundreds of years to treat respiratory diseases such as bronchial inflammatory, pneumonia, expectorant and cough [2,3].

Geoffroea decorticans (chañar) is a tree which belongs to the Fabaceae family. The fruit extract and derivate products (arrope) constitute an interesting example of ethnopharmacology [4]. This

species is widely found distributed in the center and north of Argentine, north of Chile, south of Peru and Bolivia. Its fruits and its products are commonly used for both culinary and medicinal purposes [5].

Under dry conditions, the fruits can be stored for one year before consumption. The fruits and seeds are used raw, roasted, boiled and / or fermented (beverage). The chañar flour was used as ingredient for soups and to make so-called chañar breads by rural communities [6].

The "arrope", sweet like honey, is traditionally prepared for both culinary and medicinal purposes [7,8]. Some works have suggested that the barks, leaves, flowers and fruits are employed in traditional medicine as anti-asthmatic, emollient and antitussive, among other uses [2,9,10]. Of the fruits, infusion and decoction were used as an expectorant, the decoction also is used as a remedy for whooping cough and it is also said to fight flatulence. The arrope is recommended as the best cough syrup [11].

The word arrope is part of the language and daily life in rural areas. This typical sweet Northwest appeal an ancient tradition, made without

sugar, the arrope is preserved many months without refrigeration, hence the importance of its study, since it is the habitual form of consumption for the relief of cough.

A nutraceutical is a food that provides health benefits, including the prevention and / or treatment of diseases. Recently it was demonstrated that the aqueous extract and arrope of *Geoffroea decorticans* fruits display a potent antinociceptive effect in rats, partly through an opioid mediated mechanism.

The preliminary acute toxicity test showed that the aqueous extract and the arrope can both be considered safe without any observable adverse effects [5]. Chañar fruits flour and arrope were recommended as functional food to their high level of sugar, fiber, polyphenolic compounds and antioxidant activity [5].

Costamagna et al. [6] showed that the ripe fruits flour contains a complex mixture of polyphenols (phenolic acids and flavonoids) that present relevant functional properties, suggesting that a diet including chañar fruits flour or chañar fruits, may be preventive against diseases that are associated with oxidative stress, inflammatory mediators and metabolic syndrome.

This study was undertaken to investigate medicinal properties of chañar relating to antitussive, expectorant and anti-inflammatory activities in vivo. In addition was conducted evaluation of subchronic toxicity in vivo of the aqueous extract and arrope from *Geoffroea decorticans* fruits, long term studies are essential to determine a range of bioactivities to a no observed adverse effect level (NOAEL) [12] and support the use of the fruits of chañar as a nutraceutical.

Materials and Methods

Plant material

The plant materials used in this study consists on fruits of *Geoffroea decorticans* (chañar) collected during season of maturation of December–January (2011 - 2012) in Icaño, in the province of Santiago del Estero, Argentina. The specimen was identified by Lic. Nora Muruaga using morphological, anatomical and histochemical techniques. A voucher specimen LIL n°612255 was deposited in the herbarium of Fundación Miguel Lillo, Tucumán, Argentina.

Preparation of aqueous extract

Traditional medicine may use different methods for extracting the active compounds. The extraction of the fruits was with boiled distilled water during 20 min (infusion), for obtaining the aqueous extract. The extract were filtered through Whatman paper no. 1 and centrifuged at 10,000 rpm, the supernatant was evaporated to dryness. The dry extract was stored in sterile Eppendorf at 4°C until used.

Preparation of arrope

The chañar fruits were washed and boiled in water over medium heat, they were stirred with a wooden spoon from the time that the pulp begins to fall apart. They were boiled until a thick and creamy liquid syrup was formed. It was later filtered through a fine mesh [13].

Animals

Male Wistar rats (weighing 190 g - 240 g) used for this study were obtained from the Bioterio de la Facultad de Bioquímica, Química y

Farmacia, Instituto de Biología (INSIBIO), Universidad Nacional de Tucumán.

The rats were first left for 7 days to acclimatize to laboratory conditions. All animals were kept under normal laboratory conditions of humidity, temperature (25°C ± 1°C) and light (12 h dark / light cycle), and allowed free access to food and water ad libitum.

The studies were conducted in accordance with the internationally accepted principles for laboratory animal use and care (EEC Directive of 1986; 86 / 609 / EEC). The experimental protocols were duly approved by the CICUAL (Comité Institucional para el Cuidado y Uso de Animales de Laboratorio) de la Universidad Nacional de Tucumán, under the current research Project.

Carrageenan-induced hind paw edema in rats

Paw edema was induced in rats by carrageenan injection 0.1 ml of 1.5% (w/v) into the sub plantar region of the right hind paw of the rats according to the method described by Winter et al. [14]. All rats (six per group) were given free access to food and water after the sub plantar injections. Control group rats received saline solution [0.9% (w/v) NaCl] (2 ml/kg) and the reference group received 100 mg/Kg ibuprofen, orally.

The test groups of rats were treated orally with dose of 250, 500 and 1000 mg / kg of the aqueous extract and arrope 30 min before the carrageenan injection. The paw volume was measured before administering carrageenan (Vo) and 1, 2, 3, 4 and 6 h aier (Vt).

Inflammation was calculated as the increase in volume (ml) of the paw after treatment subtracted of the basal volume. Results were expressed as percentage of inhibition of edema, calculated according to the following formula [15].

$$[(Vt - Vo) / Vo] \times 100$$

Cotton pellet-induced granuloma formation

Male rats weighing 180 g - 200 g were randomly divided into seven groups of six rats each. Two sterilized cotton pellets (20 mg) were implanted subcutaneously, one on each side of the abdomen in all groups, under light ether anesthesia. Rats in groups I (control group) received vehicle. Rats in groups II and III received ibuprofen and meprednisone, at the dose of 100 mg/kg/day and 5 mg/kg/day, respectively.

Rats in groups IV to IX received ethanol extract, aqueous extract and arrope at the doses of 250, 500 and 1000 mg / kg/day respectively. Each test substance was administered for 7 days.

On the eighth day, each rat was sacrificed and the implanted pellets as well as the thymus were dissected out and determined for their wet and dry weights (dried at 60°C for 18 h). The granuloma and transudative weights and the percent inhibition of granuloma formulation of the test compounds were calculated [16].

Antitussive effects against ammonia induced coughing

Rats male weighing 210 g - 240 g was divided randomly, 6 rats per group. The negative control of animals was treated with saline solution [0.9% (w/v) NaCl] (2 ml/kg) orally, and other groups received single daily dose of extract (250, 500 and 1000 mg/kg) and codeine phosphate syrup (3 mg/kg) oral for three days respectively.

Antitussive activity was investigated on a classical cough model induced by ammonia liquor (Shang et al. [17] and Liu et al. [18], with slight modifications), 30 minutes after oral administration of the test compounds, each rat was placed in a 1000 ml special glass chamber and exposed to 0.3 ml 25% NH_4OH produced by a nebulizer for 45 sec.

During the ammonia exposure, the animal was continuously monitored by a trained observer. The cough frequency and latent period of cough were recorded for six minutes. The antitussive activity was assessed as the percentage of inhibition of the number of coughs in terms of that in control groups by using the following equation: %Inhibition = $[(C0 - Ct) / C0 \times 100\%]$

(C0: the number of coughs of Control, Ct: the number of coughs of the treatment groups)

Expectorant activity of extracts

Rats (210 g - 240 g) were divided into 6 groups (n = 6). The control group received saline solution [0.9% (w/v) NaCl] (2 ml/kg) and other groups received single daily dose of extract (500 mg/kg and 1000 mg/kg) and Bromhexine syrup (12 mg/kg) oral for three days respectively. One hour after the last drug administration, 5% of phenol red in saline solution (500 mg/kg) is injected for intraperitoneal via.

After 30 min, the rats were killed. The trachea was dissected free from adjacent organs and removed from the thyroid cartilage to the main stem bronchi and then put into 4.0 ml of saline solution, 1 ml of this wash solution was measured and mixed with 0.5 ml NaOH (1 mol/L). The optical density (OD) values were measured on a spectrophotometer with the wavelength of 546 nm. The excretion of phenol red was determined according to the standard curve (Liu et al. [18] with slight modifications).

Sub chronic toxicity study in rats

Male Wistar rats, weighing 210 g - 240 g, were housed in 5 groups of 6 animals each under the same conditions.

- Group I received sterile normal saline
- Groups II received aqueous extract (1 g/kg bw/day)
- Groups III received aqueous extract (2 g/kg bw/day)
- Groups IV received arrope (1 g/kg bw/day)
- Groups V received arrope (2 g/kg bw/day)

Then baseline readings of their weights were recorded. The aqueous extract and arrope of chañar, dispersed in sterile normal saline (0.9% NaCl solution as vehicle) was administered orally, daily for 13 weeks [19]. The dose 1 g/kg is equivalent to the dose used by traditional medicine and corresponding to the dose with antinociceptive activity [5].

At the end of the 13 weeks experiment, all the animals were anaesthetized with intraperitoneal injection of Ketamina / Acepromacina, and blood samples were collected via cardiac puncture and transferred into non-heparinised and EDTA-containing tubes for both biochemical and haematological analyses, respectively.

The sacrificed rats were then dissected. Lung, spleen, heart, liver, pancreas and kidneys, were observed macroscopically in situ, based on the position, color, shape, size, weight and consistency of the organs.

Relative organ weight

The excised organs were weighed individually. The index of each organ to its body weight ratio (relative organ weight) was calculated as (weight of organ / body weight of rats on the day of sacrifice) \times 100 [20]. The balance employed was purchased from Mettler-Toledo Group, Model Dragon 204 (Ohaus Corporation, Navigator N2B110, Switzerland, d = 0.1 g).

General behavior and mortality

Before treatment, rats were individually handled and carefully examined for abnormal behavior and appearance. All rats were observed at least once in a day for mortality or morbidity, changes in posture, changes in skin, fur, eyes, mucous membranes and behaviors. Changes in gait were assessed weekly by allowing the rat to walk freely. Individual body weight and glycemia data were obtained, weekly during the treatment period.

Blood haematological and biochemical parameters

The haematological analyses were performed using an automatic haematological analyzer (Wiener lab. Counter 19). The parameters determined included: red blood cell count (RBC), white blood cell count (WBC), platelets count, hemoglobin, and hematocrit.

The blood chemistry tests were performed on an auto-analyzer (Metrolab 2300 plus, is an analyzer clinical random access) were determined: alanine aminotransferase (ALT), gamma glutamyltransferase (GGT), bilirubin (BIL), urea, creatinine (CREA), albumin (ALB), total protein (PROT), glucose (GLU).

Statistical analysis

Data obtained from animal experiments were expressed as the mean and standard error of the mean (mean \pm S.E.M.). Statistical differences between the treated and the control groups were evaluated by ANOVA and Dunnett's tests. The criterion for statistical significance was $p < 0.05$.

Results

Carrageenan-induced rat paw edema

In the carrageenan-induced edema test, the average right back paw volumes by the extracts and standard drug are shown in Table 1. For the control group, the injection of the phlogistic agent caused localized edema starting at 1.0 h after injection.

The swelling increased progressively to a maximum volume of $2.20 \text{ ml} \pm 0.10 \text{ ml}$ at 4.0 h after the carrageenan injection. Rats pre-treated with the aqueous extract of chañar had significant reduction of the edema 3.0 h post-dosing (100%), at 1000 mg/kg. This behavior is similar to the standard, ibuprofen (100 mg/kg, po) (96.77%). The arrope, did not show activity in this test.

Groups (n = 6)	Dose (mg/Kg)	Volume of paw edema in ml					
		0 h	1 h	2 h	3 h	4 h	6 h
Control	SS	1.40 ± 0.10	1.70 ± 0.05	1.85 ± 0.10	1.90 ± 0.05	2.20 ± 0.10	1.90 ± 0.20
Ibuprofen	100	1.40 ± 0.05	1.45 ± 0.15 (*)	1.40 ± 0.10 (*)	1.40 ± 0.10 (*)	1.45 ± 0.15 (*)	1.45 ± 0.05 (*)
Aqueous extract	250	1.40 ± 0.10	1.65 ± 0.15	1.75 ± 0.10	1.75 ± 0.15	2.00 ± 0.10	1.85 ± 0.15
	500	1.40 ± 0.10	1.60 ± 0.05 (*)	1.65 ± 0.10 (*)	1.55 ± 0.15 (*)	1.80 ± 0.15 (*)	1.75 ± 0.10 (*)
	1000	1.40 ± 0.10	1.45 ± 0.05 (*)	1.50 ± 0.10 (*)	1.40 ± 0.00 (*)	1.63 ± 0.03 (*)	1.60 ± 0.15 (*)
Arrope	250	1.40 ± 0.05	1.65 ± 0.15	1.85 ± .15	1.85 ± 0.10	2.15 ± 0.15	1.90 ± 0.15
	500	1.40 ± 0.05	1.65 ± 0.10	1.80 ± 0.10	1.80 ± 0.15	2.10 ± 0.20	1.85 ± 0.10
	1000	1.40 ± 0.10	1.65 ± 0.10	1.80 ± 0.10	1.75 ± 0.10 (*)	2.00 ± 0.05 (*)	1.80 ± 0.25

Table 1: Effect of aqueous extract and arrope of *G. decorticans* on edema carrageenan-induced rat paw. SS saline solution, values are expressed in mean ± SEM. (n = 6), ^aTime after carrageenan injection (h), ^{*}Statistically significant from control group: p < 0.05.

Cotton pellet-induced granuloma formation

Ibuprofen and meprednisone at a dose of 100 mg/kg/d and 5 mg/kg/d, and aqueous extract at the dose of 500 mg/kg/d and 1000 mg/kg/d, significantly reduced transudative and granuloma weights as shown by their granuloma inhibition of 45.56%, 57.10%, 24.41% and 47.76% respectively (Table 2).

It was also found that the dry thymus weight were not significantly different among groups (control, ibuprofen, aqueous extract and arrope), except in the meprednisone group which revealed a significant decrease from those of control group. The arrope did not show activity in this test.

Cotton pellet-induced granuloma formation					
Groups (n = 6)	Dose (mg/kg/d)	Transudative weight (mg)	Granuloma weight (mg)	Granuloma inhibition (%)	dry Thymus weight (mg/100 g BW)
Control	SS	594.35 ± 25.60	156.70 ± 3.30	--	30.49 ± 2.06
Ibuprofen	100	178.90 ± 15.50 (*)	76.20 ± 2.80 (*)	45.56	33.24 ± 5.40
Meprednisone	5	165.10 ± 14.85 (*)	55.80 ± 9.00 (*)	57.1	22.61 ± 3.95 (*)
Aqueous extract	250	581.50 ± 20.15	144.50 ± 13.25 (*)	7.78	31.50 ± 8.05
	500	400.95 ± 15.10 (*)	118.45 ± 6.50 (*)	24.41	30.95 ± 4.50
	1000	291.00 ± 14.85 (*)	81.85 ± 12.15 (*)	47.76	28.33 ± 3.20
Arrope	250	593.00 ± 10.25	155.45 ± 12.15	0.8	31.80 ± 4.05
	500	592.35 ± 1350	153.50 ± 11.50	2.04	31.15 ± 2.50
	1000	585.02 ± 25.25	148.53 ± 10.65	5.21	29.69 ± 7.10

Table 2: Effect of *Geoffroea decorticans* on cotton pellet-induced granuloma formation in rats. Values are expressed as mean ± S.E.M. (n = 6). TrW: Transudative Weight, GrW: Granuloma Weight, GI: Granuloma Inhibition, BW: Body Weight, TW: Thymus Weight. ^{*}Significantly different from the control group, p < 0.05, SS (Saline Solution).

Effects of AE and Ar on the ammonia liquor induced cough

In order to evaluate the antitussive effects of AE and Ar of chañar, the model of ammonia induced cough in rats was adopted and the results were shown in Figure 1. Codeine (3 mg/kg), AE (1000 mg/kg) and Ar (1000 mg/Kg) significantly enhanced the latent period of cough (624.74%, 70.47% and 128.02% respectively) and inhibited the cough frequency of rat (75.00%, 62.60% and 79.19% respectively), compared with that of negative control (p < 0.05).

Effects of AE and Ar on the amount of phenol red secretion

An experiment to compare the expectorant activity of AE and Ar of chañar was performed and the results were shown in Figure 2.

Compared with the negative control, treatment of rats with Bromhexine (12 mg/kg), AE (1000 mg/kg) and Ar (1000 mg/kg) significantly increased the secretion of phenol red, by 89.17%, 32.06% and 85.50% respectively (p < 0.05).

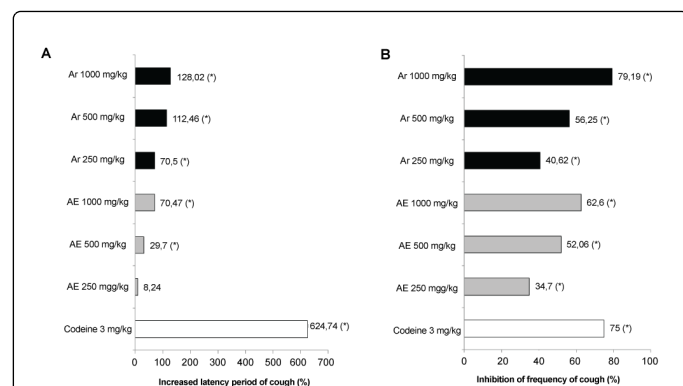


Figure 1: Effects of aqueous extract (AE) and arrope (Ar) of *G. decorticans* on the ammonia liquor induced cough. (A) Increased latency period (%) and (B) Inhibition of frequency of cough (%) in rats. Rats were treated with AE and Ar (250, 500 and 1000 mg/kg). Codeine phosphate (3 mg/kg) was taken as a positive control. Values were expressed as mean \pm SE (n = 6), (*) p < 0.05 compared with the control group.

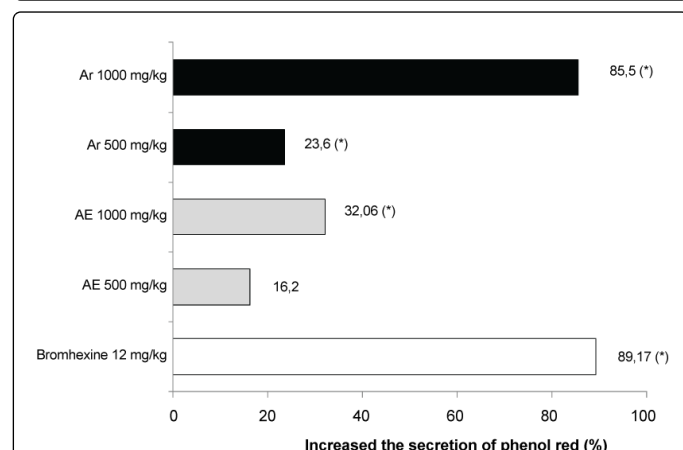


Figure 2: Effects of aqueous extract (AE) and arrope (Ar) of *G. decorticans* on the amount of phenol red secretion in percentage in rats. Rats were treated with AE and Ar (250, 500 and 1000 mg/kg). Bromhexine (12 mg/kg) was taken as a positive control. Values were expressed as mean \pm SE (n = 6), (*) p < 0.05 compared with the control group.

Sub chronic toxicity studies in rats

Effect of aqueous extract and arrope of *Geoffroea decorticans* on the general behavior of rats: Daily oral administration of *G. decorticans* aqueous extract and arrope for 91 consecutive days did not induce any obvious symptom of toxicity in rats even with the highest doses tested of 1000 mg/kg b.w. and 2000 mg/kg b.w. daily. There were no differences or significant changes in general behavior, body weight, food intake between the treated rats and those of the control group. Both the control and treated rats appeared uniformly healthy at the end and throughout the period of study. No deaths occurred at any of the doses administered. There was no significant effect on relative weights of liver, heart, spleen, kidneys, lung and pancreas between the

treated and control rats. No treatment related gross pathology was observed. No significant changes were detected in the body weight ratio of the animals (Table 3).

Organ	body weight ratio% ^a				
	Control	AE1 gr/Kg	AE2 gr/Kg	Ar1 g/Kg	Ar2 g/Kg
Kidneys	0.19	0.2	0.19	0.21	0.21
Liver	0.74	0.73	0.67	0.84	0.65
Lung	0.14	0.13	0.12	0.13	0.16
Heart	0.1	0.09	0.08	0.11	0.09
Pancreas	0.11	0.08	0.1	0.08	0.12
Spleen	0.04	0.06	0.05	0.06	0.05

Table 3: Percentage of body weight ratio of rats chronically dosed aqueous extract (AE) and arrope (Ar) of *Geoffroea decorticans*. ^aThe index of each organ to its body weight ratio (relative organ weight) was calculated as: (weight of organ / body weight of rats on the day of sacrifice) \times 100% No significant differences compared with the control group were observed.

Effect on the haematological and biochemical parameters: The haematological parameters, hematocrit, hemoglobin concentration, platelets, red and white blood cells in the treated rats did not differ significantly (P > 0.05) from that of the control group (Table 4) and all the values remained within normal clinic limits throughout the experimental period.

Plasma biochemical data at end of study are presented in Table 5. No significant changes were observed in the biochemical parameters (urea, CREA, BIL, ALT, GGT, GLU, PROT and ALB) measured between the treated and control groups, at the dose of 1 g/kg and 2 g/kg (p < 0.05).

All the haematological and biochemical parameters tested were within normal clinic values throughout the period of treatment.

Discussion

The arrope and fruits of *Geoffroea decorticans* have been historically used in ethnomedicine, of rural communities' northwest argentina, to treat respiratory diseases by several hundred years. The traditional knowledge and reports its popular use to relieve cough and bronchial diseases [2,21], led us to evaluate anti-inflammatory, antitussive and expectorant effects, and determine its safety.

The anti-inflammatory effect of *Geoffroea decorticans* extracts and arrope were investigated in the present study. The carrageenan test was selected because of its sensitivity in detecting orally active anti-inflammatory agents particularly in the acute phase of inflammation [22,23]. The intraplantar injection of carrageenan in rats leads to paw edema. Its first phase (0 h - 3 h after injection of carrageenan) results from the concomitant release of mediators: histamine, serotonin and kinins on the vascular permeability. The second phase is correlated with the elevated production of prostaglandins, oxygen-derived free radicals, and production of inducible cyclo-oxygenase [24]. Oral administration of the aqueous extract of *G. decorticans* fruits suppressed the oedematous response after 1 h and this effect continued up to 6 h. The observed effect was similar to that of Ibuprofen.

Haematological parameters	Control	AE1 gr/Kg	AE2 gr/Kg	Ar1 g/Kg	Ar2 g/Kg
RBC (10^6 mm^3)	8.35 \pm 0.13	7.70 \pm 0.07	8.07 \pm 0.22	7.80 \pm 0.05	8.81 \pm 0.15
WBC (10^3 mm^3)	5.40 \pm 0.30	5.20 \pm 0.36	5.90 \pm 0.10	4.90 \pm 0.03	4.75 \pm 0.40
Haematocrit (%)	51.86 \pm 4.86	48.50 \pm 0.50	50.15 \pm 1.90	49.00 \pm 1.10	52.57 \pm 1.77
Platelet (10^6 mm^3)	1.03 \pm 0.03	0.97 \pm 0.05	1.10 \pm 0.10	0.99 \pm 0.15	1.08 \pm 0.10
Hemoglobin (gr %)	16.70 \pm 1.30	14.00 \pm 0.05	16.25 \pm 1.00	14.50 \pm 0.05	16.50 \pm 0.55

Table 4: Effects of *Geoffroea decorticans* aqueous extract (AE) and arrope (Ar) in haematological blood parameters of rats. Values are expressed in mean \pm SEM. (n = 6). No significant differences compared with the control group were observed.

The inflammatory granuloma is a typical feature of chronic inflammatory reaction [25]. The cotton pellet granuloma method has been widely used to assess the transudative, exudative and a proliferative phase of chronic inflammation. The fluid adsorbed by the pellet greatly influences the wet weight of the granuloma, whereas the dry weight correlate well with the amount of granulomatous tissue formed. Most of the NSAIDs like ibuprofen possess only slight inhibition on the granuloma formation. The steroidal drug on the contrary, exhibits profound reduction of the granuloma. The aqueous extract of chañar, at dose of 500 mg/kg and 1000 mg/kg, elicited significant inhibitory activity on the wet weight of granuloma. This suggests an inhibitory effect of the extract on vascular permeability. When assessment was made on the dry weight of granuloma, which projects the effect of test substances on the proliferative phase of inflammation, it was found that the aqueous extract at the different dose used appeared to be effective in inhibition of granuloma formation.

The aqueous extract was able to reduce the paw edema and the inflammatory cell infiltration in a chronic inflammation. These results suggest that the anti-inflammatory activity may be mediated by the inhibition of prostaglandin biosynthesis, similar at result obtained by Costamagna et al. [6] demonstrated that in vitro anti-inflammatory activity is due to the inhibit of three pro-inflammatory enzymes, COX, LOX and sPLA2. These findings, together with the antinociceptive and antioxidant activity demonstrated by Reynoso et al. [5] suggest that the fruits consumption may contribute to the reduction of inflammation and could prevent or relieve diseases, where inflammatory processes are involved. However, the chañar arrope showed no anti-inflammatory activity in both inflammation models used. These results suggest that the process of preparation of arrope may affect the structure of the compounds responsible for the anti-inflammatory activity observed in the aqueous extract.

Biochemical parameters	Control	AE1 gr/Kg	AE2 gr/Kg	Ar1 g/Kg	Ar2 g/Kg
Urea (gr/l)	0.47 \pm 0.03	0.50 \pm 0.01	0.55 \pm 0.05	0.45 \pm 0.09	0.52 \pm 0.10
Creatinine (mg/l)	6.53 \pm 0.57	7.10 \pm 0.50	7.90 \pm 1.00	6.85 \pm 0.50	8.05 \pm 0.85
GGT (mU/ml)	14.00 \pm 2.50	15.55 \pm 1.00	17.00 \pm 1.00	18.00 \pm 2.50	19.50 \pm 4.50
ALT (UI/l)	49.50 \pm 1.45	51.00 \pm 3.50	55.30 \pm 2.50	53.50 \pm 7.50	59.67 \pm 5.60
Bilirrubin (mg%)	0.57 \pm 0.05	0.60 \pm 0.05	0.65 \pm 0.10	0.70 \pm 0.05	0.75 \pm 0.50
Protein (gr/dl)	6.70 \pm 0.50	6.00 \pm 0.50	6.25 \pm 0.05	5.70 \pm 0.20	6.60 \pm 0.40
Albumin (gr/dl)	4.15 \pm 0.15	4.00 \pm 0.20	3.95 \pm 0.15	3.90 \pm 0.10	4.03 \pm 0.23
Glucose (mg/dl)	88.00 \pm 7.50	90.50 \pm 0.50	92.00 \pm 3.00	89.50 \pm 3.50	97.00 \pm 1.00

Table 5: Effects of aqueous extract (AE) and arrope (Ar) of *Geoffroea decorticans* on biochemical blood parameters of rats. Values are expressed in mean \pm SEM. (n = 6). No significant differences compared with the control group were observed.

Previous studies found the presence of high content of carbohydrates, such as quercetin and apigenin flavonoids and other phenolic constituents [10,11] in chañar fruits. Other authors establishing relations between expectorant, antitussive, anti-inflammatory properties and inhibitory effects on asthma and flavonoid content [26-29]. Additionally, Costamagna relates antioxidant and anti-inflammatory activities in vitro with the phenolic content of chañar fruits flour.

The present studies demonstrate a potent antitussive effect for both extracts, the AE and Ar (1000 mg/Kg) showed significant antitussive effect, through the increase of latent period of cough and inhibition of the cough frequency, similar to a known antitussive, codeine. Opioids, such as morphine and codeine are generally considered to be the most potent and effective antitussive drugs available and believed to inhibit cough through suppression of a cough center in the central nervous system. Previous studies [5] also showed that the antinociceptive effect is due to opioid properties of this plant. Therefore the existence of

opioid effect could be responsible for its antitussive effects. However the exact mechanism(s) of these effects could be clarified in further studies.

Additionally, both extracts enhanced phenol red secretion into the airway similar to bromhexine, as positive control, which indicates that the expectorant action may be related to its ability to increase tracheobronchial mucus secretion, thus, may decrease of viscosity of mucus [21].

Despite its widespread uses, the potential toxicity of this plant must be investigated thoroughly to provide information on the safety of this specie. In previous studies of acute toxicity [5] and mutagenic effect in bacterial systems [11] it was demonstrated that the aqueous extract and arrope were safety. Therefore, the present study was conducted to identify potential chronic toxic effect and established a non-observed effect level with prolonged administration in rats. In the chronic toxicity assay of repeated doses, the rats were treated orally with aqueous extract and arrope at different doses (1 g/Kg and 2 g/Kg body weight) daily during 13 weeks. According to Teo et al. [30] slight changes in body weight gain and internal organ weight will be detected if the rats were exposed to potential toxic substances. Organ to body weight ratio (relative organ weight) is another indicator used to evaluate toxicity in rats [20]. The weight of the damage organs will either increase (swell) or decrease and ultimately alter their organ to body weight ratio, when compared to their respective controls. From the results, however, the body weight of treated and control rats were similar with no significant differences detected. There were no obvious signs of toxicity, including changes in behavior, locomotion, respiration, piloerection, diarrhea, convulsions and hyperexcitability. In addition no significant differences were observed in gross anatomy, weight, size or color by macroscopic examination of the internal organs between the treated and control groups, therefore not needing of histopathological studies [27,31]. According to Adeneye et al. [32] claimed that the hematopoietic system in animals can be served as an important index in the physiological and pathological status for both animals and humans. Toxic material will tend to cause changes to the haematological parameters. Therefore, several and important haematological parameters were selected and included in this study to evaluate the toxicity of aqueous extract and arrope. From the results obtained and analyzed statistically between the rats fed with aqueous extract, arrope and the control group no significant differences were observed in any of the selected parameters. Analyses of several biochemistry parameters were included. According with Kaneko et al. [33] when the cells were exposed to toxic substances will cause a certain degree of damage to the cells and causing cellular injury. Hence, the cellular permeability is altered and releases the biochemical substances into the blood stream. These substances such as transaminase enzymes (ALT, GGT) are mostly found in the cytoplasm of many organs such liver. Therefore, these biochemistry parameters were selected in such a way that an increase in the transaminase and total bilirubin levels in blood samples directly indicated hepatic toxicity [30] while the changes in the levels of creatinin, urea, sodium, potassium chloride indicate kidney toxicity [31-33]. From the results obtained and analyzed statistically between the rats fed with aqueous extract, arrope and the control group no significant differences were observed in any of the selected parameters.

These data suggested that the aqueous extract and arrope can be considered not toxic for these animals at tested doses.

These results are the important evidence for validation the traditional use of *Geoffroea decorticans* fruits in the treatment of respiratory diseases including bronchopulmonary disorder [34,35].

Conclusion

This study demonstrated significant expectorant, antitussive and anti-inflammatory effects of *Geoffroea decorticans* fruits in animal models. These effects are the important pharmacological evidences for the traditional use of chañar as an antitussive remedy.

Further investigations are in progress to explain the active components and the mechanism of action for the observed activities.

Acknowledgement

The authors thank CIUNT Consejo de Investigaciones de la Universidad Nacional de Tucumán for their grants.

References

1. Pang W, Lin S, Dai Q, Zhang H, Hu J (2011) Antitussive activity of *Pseudostellaria heterophylla* (Miq.) Pax extracts and improvement in lung function via adjustment of multi-cytokine levels. *Molecules* 16: 3360-3370.
2. Scarpa GF (2004) Medicinal plants used by the Criollos of Northwestern Argentine Chaco. *J Ethnopharmacol* 91: 115-135.
3. Goleniowski ME, Bongiovanni GA, Palacio L, Nuñez CO, Cantero JJ (2006) Medicinal plants from the "Sierra de Comechingones", Argentina. *J Ethnopharmacol* 107: 324-341.
4. Quiroga EN, Sampietro DA, Sgariglia MA, Soberón JR, Vattuone MA (2009) Antimycotic activity of 5'-prenylisoflavanones of the plant *Geoffroea decorticans*, against *Aspergillus* species. *Int J Food Microbiol* 132: 42-46.
5. Reynoso MA, Vera N, Aristimuño ME, Daud A, Sánchez Riera A (2013) Antinociceptive activity of fruits extracts and "arrope" of *Geoffroea decorticans* (chañar). *J Ethnopharmacol* 145: 355-362.
6. Costamagna MS, Zampini IC, Alberto MR, Cuello S, Torres S, et al. (2016) Polyphenols rich fraction from *Geoffroea decorticans* fruits flour affects key enzymes involved in metabolic syndrome, oxidative stress and inflammatory process. *Food Chem* 190: 392-402.
7. Becker R (1983) Nutritional quality of the fruit from the chañar tree (*Geoffroea decorticans*). *Ecol Food Nutr* 13: 91-97.
8. Villagran C, Castro V (2004) Ciencia Indígena de los Andes del Norte de Chile. Biodiversidad (Editorial Universitaria), pp: 98.
9. Amorin JL (1988) Guía taxonómica con plantas de interés farmacéutico. Colegio Oficial de Farmacéuticos y Bioquímicos de Capital Federal. Argentina pp: 19.
10. Silva R, López de Ruiz RE, Ruiz SO (1999) Estudio Fitoquímico de Frutos de *Geoffroea decorticans* (Gill. ex Hook et Arn.) Burk. Leguminosae (Fabaceae). *Acta Farm Bonaer* 18: 217-9.
11. Costamagna MS, Ordoñez RM, Zampini IC, Sayago JE, Isla MI (2013) Nutritional and antioxidant properties of *Geoffroea decorticans*, an Argentinean fruit, and derived products (flour, arrope, decoction and hydroalcoholic beverage). *Food Res Int* 54: 160-168.
12. Dorato MA, Engelhardt JA (2005) The no-observed-adverse-effect-level in drug safety evaluations: use, issues, and definition(s). *Regul Toxicol Pharmacol* 42: 265-274.
13. Figueroa G, Dantas M (2006) Recolección, procesamiento y consumo de frutos silvestres en el noroeste semiárido argentino, casos actuales con implicancias arqueológicas. *La Zaranda de Ideas* 2: 35-50.
14. Winter CA, Risley EA, Nuss GW (1962) Carrageenin-induced edema in hind paw of the rat as an assay for anti-inflammatory drugs. *Proc Soc Exp Biol Med* 111: 544-547.

15. García D, Fernández A, Sáenz T, Ahumada C (1996) Anti-inflammatory effects of different extracts and harpagoside isolated from *Scrophularia frutescens* L. Farmaco 51: 443-446.
16. Pingsusaen P, Kunanusorn P, Khonsung P, Chiranthanut N, Panthong A, et al. (2015) Investigation of anti-inflammatory, antinociceptive and antipyretic activities of *Stahlianthus involucratus* rhizome ethanol extract. J Ethnopharmacol 162: 199-206.
17. Shang JH, Cai XH, Zhao YL, Feng T, Luo XD (2010) Pharmacological evaluation of *Alstonia scholaris*: anti-tussive, anti-asthmatic and expectorant activities. J Ethnopharmacol 129: 293-298.
18. Liu LH, Wang LS, Liu XM (2009) Comparison of antitussive, expectorant and antiasthmatic activities of different extracts from *Ficus microcarpa*. J Med Plants Res 3: 596-599.
19. Mukinda JT, Syce JA (2007) Acute and chronic toxicity of the aqueous extract of *Artemisia afra* in rodents. J Ethnopharmacol 112: 138-144.
20. Rosidah, Yam MF, Sadikun A, Ahmad M, Akowuah GA, et al. (2009) Toxicology evaluation of standardized methanol extract of *Gynura procumbens*. J Ethnopharmacol 123: 244-249.
21. Lin BQ, Li PB, Wang YG, Peng W, Wu Z, et al. (2008) The expectorant activity of naringenin. Pulm Pharmacol Ther 21: 259-263.
22. Di Rosa M, Giroud JP, Willoughby DA (1971) Studies on the mediators of the acute inflammatory response induced in rats in different sites by carrageenan and turpentine. J Pathol 104: 15-29.
23. Di Rosa M (1972) Biological properties of carrageenan. J Pharm Pharmacol 24: 89-102.
24. Panthong A, Kanjanapothi D, Taesotikul T, Phankummoon A, Panthong K, et al. (2004) Anti-inflammatory activity of methanolic extracts from *Ventilago harmandiana* Pierre. J Ethnopharmacol 91: 237-242.
25. Kumar K, Ganesh M, Baskar S, Srinivasan K, Kanagasabai R, et al. (2006) Evaluation of Anti-inflammatory activity and toxicity studies of *Chloroxylon sweitenia* in Rats. Anc Sci Life 25: 33-43.
26. Lin BQ, Li PB, Wang YG, Peng W, Wu Z, et al. (2008) The expectorant activity of naringenin. Pulm Pharmacol Ther 21: 259-263.
27. Liu M, Yang C, Zou W, Guan X, Zheng W, et al. (2011) Toxicokinetics of naringin, a putative antitussive, after 184 day repeated oral administration in rats. Environ Toxicol Pharmacol 31: 485-489.
28. Ribeiro M, Barateiro A, Vila-Real H, Fernandes A, Brites D (2009) Anti-inflammatory effect of naringin and naringenin on TNF- α secretion in cultured cortical astrocytes after stimulation with LPS. New Biotechnology 25: S10-S11.
29. Shi Y, Dai J, Liu H, Li RR, Sun PL, et al. (2009) Naringenin inhibits allergen-induced airway inflammation and airway responsiveness and inhibits NF-kappaB activity in a murine model of asthma. Can J Physiol Pharmacol 87: 729-735.
30. Teo S, Stirling D, Thomas S, Hoberman A, Kiorpes A, et al. (2002) A 90-day oral gavage toxicity study of D-methylphenidate and D,L-methylphenidate in Sprague-Dawley rats. Toxicology 179: 183-196.
31. Brazil (2004) Agência Nacional de Vigilância Sanitária. Resolução – Guia para a realização de estudos de toxicidade pré-clínica de fitoterápicos, de 16/03/2004. Diário Oficial da República Federativa do Brasil, Poder Executivo, Brasília, DF.
32. Adeneye AA, Ajagbonna OP, Adeleke TI, Bello SO (2006) Preliminary toxicity and phytochemical studies of the stem bark aqueous extract of *Musanga cecropioides* in rats. J Ethnopharmacol 105: 374-379.
33. Kaneko JJ, Harvey JW, Bruss ML (1997) Clinical Biochemistry of Domestic Animals. Academic Press, San Diego, USA pp: 932.
34. Costa-Silva JH, Lima CR, Silva EJ, Araújo AV, Fraga MC, et al. (2008) Acute and subacute toxicity of the *Carapa guianensis* Aublet (Meliaceae) seed oil. J Ethnopharmacol 116: 495-500.
35. Rebecca MA, Ishii-Iwamoto EL, Grespan R, Cuman RK, Caparroz-Assef SM, et al. (2002) Toxicological studies on *Stryphnodendron adstringens*. J Ethnopharmacol 83: 101-104.