

Neurocysticercosis Presenting as Bipolar Disorder and Chronic Papilledema: A Rare Case Report and Review

Mona Sune¹, Pradeep Sune¹, Mala Kamble¹, Pravin Tidake¹, Rashmin Gandhi⁴, Prem Subramanian^{2,3} and Rakesh Juneja^{1*}

¹ Department of Ophthalmology, Acharya Vinoba Bhave Rural Hospital, Sawangi, Wardha, India

² Neuro-ophthalmology Division, The Wilmer Eye Institute, Johns Hopkins University School of Medicine, Baltimore, Maryland, USA

³ Department of Surgery, Uniformed Services University of the Health Sciences, Bethesda, Maryland, USA

⁴ Department of Neuro-Ophthalmology, Center for Sight, Superspeciality Eye Hospitals, Hyderabad, India

*Corresponding author: Rakesh Juneja, Resident in Ophthalmology, JNMC, DMIMS University, Sawangi (Meghe), Wardha, 442004, Maharashtra, India. E-mail: dr_rakeshjuneja555@yahoo.com

Received date: April 20, 2013, Accepted date: July 31, 2014, Published date: August 07, 2014

Copyright: © 2014 Sune M, et al. This is an open-access article distributed under the terms of the Creative Commons Attribution License, which permits unrestricted use, distribution, and reproduction in any medium, provided the original author and source are credited.

Abstract

A 40 year old female presented with mania, abnormal behaviour, headache & gradual progressive diminution of vision & history of pork consumption. Anterior segment examination OU was normal. Fundus of both eyes showed B/L established papilledema. Visual Acuity was 20/125 both eyes. CT & MRI with contrast revealed multiple well defined rounded CSF density cysts with a central mural nodule representing a scolex showing ring enhancement and perilesional edema. The largest lesion was 7.7×9 mm and multiple lesions were noted in both cerebral hemisphere and internal capsular regions, right cerebellar hemisphere and pons suggestive of disseminated neurocysticercosis. B-scan revealed disc edema and increased optic nerve diameter by more than 5 mm in both eyes confirming papilledema. She was prescribed albendazole, praziquantel, steroids, mannitol, acetazolamide and lithium. With this treatment her mania and headache resolved and her vision in both eyes improved to 20/40. Fundus examination after 3 months showed resolving papilledema. CT & MRI now showed marked decrease in number and regression in size of cyst and lesions. Bipolar disorder (mania & abnormal behavior) can be the first presenting sign of neurocysticercosis and papilledema. The probable explanation for maniac presentation in neurocysticercosis is due to some changes in neurotransmitter level. Papilledema was due to raised ICP suggested by perilesional edema in CT scan & MRI, and disc edema with increased optic nerve diameter in both eyes by more than 5 mm in B-scan.

Keywords: Neurocysticercosis; Papilledema; Bipolar disorder

Introduction

Cysticercosis results in severe morbidity and mortality in both developing (in which it is endemic) and developed nations (due to immigration) and is a major public health problem [1,2]. It is the most common parasitic infection of the human CNS and is caused by the larval form of the tapeworm *Taenia solium*, for which humans are the definitive hosts and pigs are the intermediate hosts [1,3].

The clinical manifestations of neurocysticercosis vary according to the number, size, topography, and stage of lesion as well as host's immune response. Although many cases remain asymptomatic, they may present with seizures, headache, increased intracranial pressure (ICP), stroke, neuropsychiatric symptoms, and ophthalmological and endocrinological manifestations [4]. If untreated, the cysts can increase in size causing ocular manifestations and blindness in 3-5 years. Eye damage and intense inflammatory reaction may occur in response to parasitic lysis after therapy [5]. Bipolar disorder is an unusual presentation of neurocysticercosis. We herein describe a rare case of multiple neurocysticercosis in a 40 year old hypertensive female associated with bipolar disorder and chronic papilledema with symptomatic improvement and cyst regression after treatment.

Case Report

A 40 year old female with well-controlled systemic hypertension experienced a 2 month gradual onset of abnormal behavior with restlessness, irritability, agitation, elevated mood and disturbed sleep. She complained of several days of intermittent headache, gradually progressive blurred vision, nausea, fever and neck pain for 2 days. She gives history of pork consumption. There was no history of seizures, and her family and personal history were noncontributory. General physical examination was unremarkable. Complete blood count, renal function, and liver function tests were within normal limits. She was provisionally diagnosed with bipolar disorder and was prescribed lithium. Her psychotic symptoms improved over a period of 4 weeks but headache persisted. General physical examination was unremarkable.

Thus, CT head was performed which revealed multiple well defined rounded CSF density cysts with a central mural nodule representing a scolex showing ring enhancement with contrast (Figure 1a). The largest lesion was 7.7×9 mm, and multiple lesions were noted in both cerebral hemisphere and internal capsular regions, right cerebellar hemisphere, and pons suggestive of disseminated neurocysticercosis. Brain MRI with contrast confirmed neurocysticercosis in the colloidal-vesicular stage. She was prescribed albendazole 400 mg three times a day, praziquantel 100 mg/kg three doses at two hour interval followed by steroids 6 hours later.

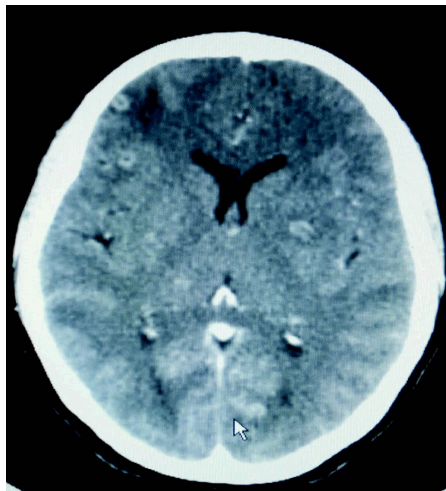


Figure 1a: CT scan picture showing diffuse parenchymatous neurocysticercosis in the form of with largest lesion measuring 7.7×9 mm.

She was referred to the ophthalmology department for evaluation of worsening blurred vision and headache. On examination her visual acuity was 20/125 OU. Anterior segments were unremarkable. Fundus examination revealed chronic-appearing papilledema in both eyes (Figure 1b and 1c). Ophthalmic B-scan ultrasound of both eyes revealed disc elevation and increased optic nerve sheath diameter by >5 mm, indicating elevated ICP (Figure 1d and 1e). She was treated with intravenous mannitol 100 ml three times a day and oral acetazolamide 250 mg three times a day. Subsequent fundus examination after 3 months revealed signs of resolving papilledema (Figure 2a and 2b). Her vision has improved to 20/40 OU. CT head now showed a marked decrease in number of cysts and regression in size of largest lesions (Figure 2c). Her headache and psychiatric symptoms also improved with continued antiparasitic treatment.

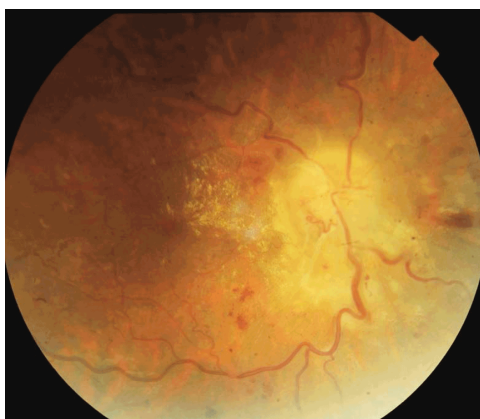


Figure 1b: Fundus Picture showing established papilledema in the form of disc edema, peripapillary haemorrhages, venous dilatation & tortuosity with few peripapillary exudates.

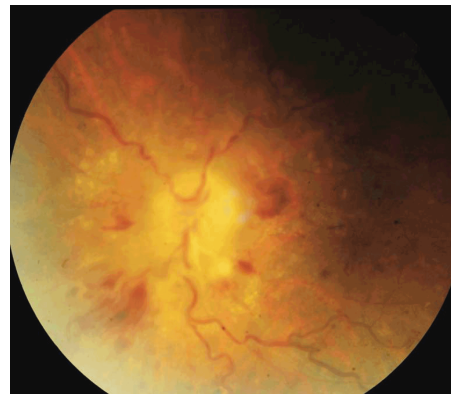


Figure 1c: Fundus Picture showing established papilledema in the form of disc edema, peripapillary haemorrhages, venous dilatation & tortuosity with few peripapillary exudates.

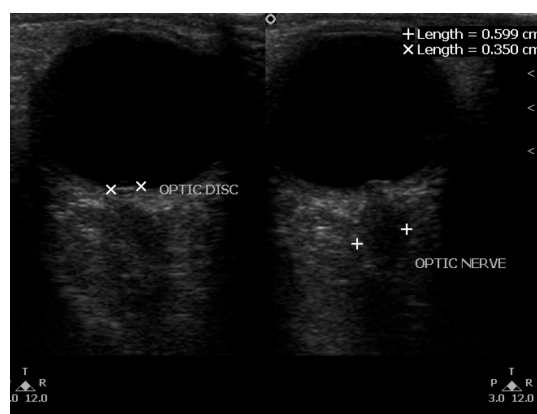


Figure 1d: Ophthalmic B-scan ultrasound showing increased optic nerve diameter >5 mm OU suggestive of Papilledema.

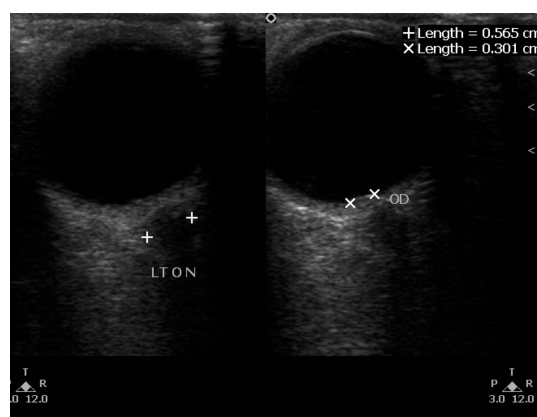


Figure 1e: Ophthalmic B-scan ultrasound showing increased optic nerve diameter >5 mm OU suggestive of Papilledema.

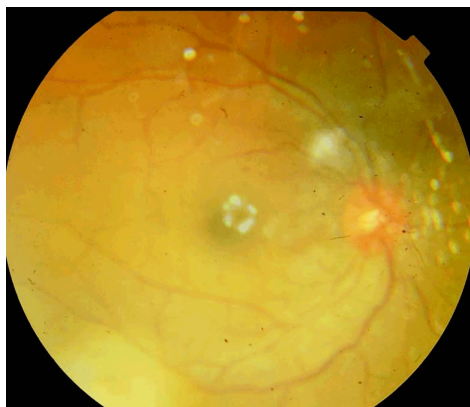

Figure 2a: Fundus Picture showing resolved papilledema in the form of absence of disc edema, peripapillary haemorrhages, exudates.

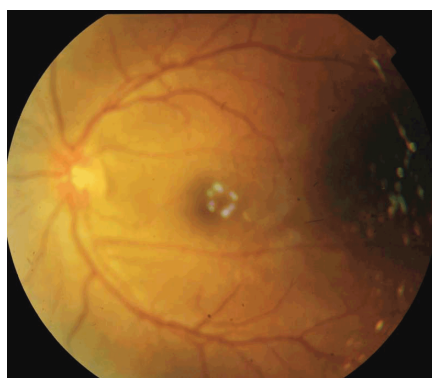


Figure 2b: Fundus Picture showing resolved papilledema in the form of absence of disc edema, peripapillary haemorrhages, exudates.

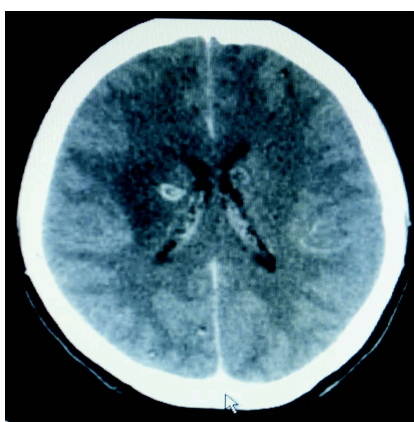

Figure 2c: CT scan picture post treatment during follow up visit after 3 months showing decrease in size of largest lesion measuring 6×6 mm and decrease in number of cysts.

Discussion

Neurocysticercosis is a pleomorphic disease with varied manifestations depending on the number, size and topography of the lesions and the intensity of the immune host response to the parasite. Seizures are the most common clinical manifestation, while headache and focal neurological deficits may occur in 20-40% of affected patients [6]. Confusion, ataxia, and psychosis are seen in fewer than 10% of cases.

Because our patient's initial symptoms (behavioral changes) were not a common manifestation of neurocysticercosis, her disease went unrecognized until persistent headache prompted neuroimaging to be performed. Her other symptoms of headache and blurred vision were also less characteristic of typical neurocysticercosis. Our patient presented with hypomania for 2 months, headache and fundus examination revealed chronic papilledema, and was finally diagnosed as having neurocysticercosis.

Stepien et al. observed mental changes in 28 percent of neurocysticercosis cases [7]. The most frequent symptoms were loss of orientation and hallucination; less frequent symptoms were euphoria, confusion, agitation, impairment of memory and slowing in mental process. A schizophrenic illness has been described as the presenting sign of neurocysticercosis [8], and in a case with a similar presentation to ours, a 25 year old man was diagnosed with psychosis but was not found to have innumerable cerebral cystic lesions until a generalized tonic-clonic seizure prompted cranial CT imaging [9]. In studies from the pre-imaging era, increased ICP often accompanied the described psychiatric symptoms [10], but it is unclear if this observation was specific to the proposed subtype of disease or represented typically late identification of the cases. In our case we found symptoms of hypomania early in the disease course with signs and symptoms of increased ICP not occurring until later. Our patient showed no evidence of obstructive hydrocephalus with cerebral edema as the most likely cause of her papilledema, unlike a recently reported case of neurocysticercosis in which diplopia and headache were described [11]. Small case series have suggested that mania is the most common mood disorder in neurocysticercosis; however, a larger prospective study of psychiatric disorders in 38 patients with neurocysticercosis showed that depression was most prevalent (12/23 patients with psychiatric disease, or 52%) [12].

Our patient presented with a functional psychiatric illness with no evidence of structural disease like seizures. Antipsychotic drugs were of limited help and only when praziquantel was added did significant improvement occur. Although we cannot completely rule out the possibility of purely psychiatric illness, definitive evidence (CT scan) of neurocysticercosis and the clinical response observed after addition of praziquantel further suggest that the psychiatric symptoms may be due to neurocysticercosis. While it is possible that mania may result from altered neurotransmitter levels in this condition, definitive proof of the mechanism is not available [13].

Symptomatic treatment forms the basis of neurocysticercosis therapy. Currently, albendazole is the drug of choice for antiparasitic therapy (15 mg/kg/day for 7 days with oral steroids) although a single day praziquantel regimen seems equally effective (25 mg/kg, three doses at two hour intervals followed by steroids 6 hours later) [14]. Multiple lesions or subarachnoid cysticercosis require a longer course. Surgery is limited to ventriculo-peritoneal shunting to relieve obstructive hydrocephalus and excision of isolated, surgically favorable single cysts [15]. Chronic depression should be treated with

appropriate psychiatric referral. Nonetheless, in severe neurocysticercosis (massive infection with intracranial hypertension, space-occupying lesion, intraventricular cyst) psychiatric treatment should follow neurological and neurosurgical procedures [9].

Contributorship Statement of Authors

Dr. Mona Sune: Data acquisition & Provided critical review and revision of the manuscript for crucial intellectual content.

Dr. Pradeep Sune: Data acquisition & Provided critical review and revision of the manuscript for crucial intellectual content.

Dr. Mala Kamble: Provided critical review and revision of the manuscript for crucial intellectual content.

Dr. Pravin Tidake: Data Acquisition.

Dr. Rashmin Gandhi: Provided critical review and revision of the manuscript for crucial intellectual content.

Dr. Prem Subramanian: Provided critical review and revision of the manuscript for crucial intellectual content.

Dr. Rakesh Juneja: Data acquisition.

Study Approval

The study was conducted at Acharya Vinoba Bhave Rural Hospital during January 2012 to April 2012. It was submitted to and approved by Institutional Ethical Committee, Acharya Vinoba Bhave Rural Hospital, Datta Meghe Institute of Medical Sciences, Wardha, India.

Acknowledgement:

We thank Dr. Ved Prakash Mishra, Chief Advisor, DMIMS, Sagarji Meghe, Secretary DMIMS, Dr. Shashank Banait, Associate Professor, DMIMS, Dr. Sandeep Shrivastava, Dean, JNMC, Wardha for their suggestions, inputs and more importantly granting us the permission for conducting the study in DMIMS Institute.

References

1. Bern C, Garcia HH, Evans C, Gonzalez AE, Verastegui M, et al. (1999) Magnitude of the disease burden from neurocysticercosis in a developing country. *Clin Infect Dis* 29: 1203-1209.
2. Santos R, Chavarria M, Aguirre AE (1984) Failure of medical treatment in two cases of of intraocular cysticercosis. *Am J Ophthalmol* 97: 249-250.
3. Sharma T, Sinha S, Shah N, Gopal L, Shanmugam MP, et al. (2003) Intraocular cysticercosis: clinical characteristics and visual outcome after vitreoretinal surgery. *Ophthalmology* 110: 996-1004.
4. Del Brutto OH, Rajshekhar V, White AC Jr, Tsang VC, Nash TE, et al. (2001) Proposed diagnostic criteria for neurocysticercosis. *Neurology* 57: 177-183.
5. Das D, Deka S, Islam S (2010) Neuro and intraocular cysticercosis: A clinicopathological case report. *Eye and Brain* 2: 39-42.
6. Del Brutto OH (2012) Neurocysticercosis: a review. *ScientificWorldJournal* 2012: 159821.
7. STEPIEN L (1962) Cerebral cysticercosis in Poland. Clinical symptoms and operative results in 132 cases. *J Neurosurg* 19: 505-513.
8. Bhatia B, Mishra S, Srivastava AS (1994) Neurocysticercosis presenting as schizophrenia: a case report. *Indian J Psychiatry* 36: 187-189.
9. Mahajan SK, Machhan PC, Sood BR, Kumar S, Sharma DD, et al. (2004) Neurocysticercosis presenting with psychosis. *J Assoc Physicians India* 52: 663-665.
10. Stepien L, Chorobski J (1949) Cysticercosis cerebri and its operative treatment. *Arch Neurol Psychiatry* 61: 499-527.
11. Venna N, Coyle CM, González RG, Hedley-Whyte ET (2012) Case records of the Massachusetts General Hospital. Case 15-2012. A 48-year-old woman with diplopia, headaches, and papilledema. *N Engl J Med* 366: 1924-1934.
12. Forlenza OV, Filho AH, Nobrega JP, dos Ramos Machado L, de Barros NG, et al. (1997) Psychiatric manifestations of neurocysticercosis: a study of 38 patients from a neurology clinic in Brazil. *J Neurol Neurosurg Psychiatry* 62: 612-616.
13. Mishra BN, Swain SP (2004) Psychiatric morbidity following neurocysticercosis. *Indian J Psychiatry* 46: 267-268.
14. López-Gómez M, Castro N, Jung H, Sotelo J, Corona T (2001) Optimization of the single-day praziquantel therapy for neurocysticercosis. *Neurology* 57: 1929-1930.
15. Matushita H, Pinto FC, Cardeal DD, Teixeira MJ (2011) Hydrocephalus in neurocysticercosis. *Childs Nerv Syst* 27: 1709-1721.