

Endogenous Fungal Endophthalmitis Developing in a Myasthenia Gravis Individual Treated with High Dose Methylprednisolone

Jia-lin Wang and Yu-ling Liu*

Peking University Eye Center, Peking University Third Hospital, Peking University, Beijing 100191 P.R. China

Abstract

Background: To report a successful treatment case of endogenous fungal endophthalmitis caused by corticosteroid impulse therapy and the cultures are always negative for fungi.

Methods: Systemic antifungal treatment and full ophthalmic examination including B-scan ultrasonography, fundus photograph and indocyanine green angiography.

Results: The visual acuity recovered from 0.2 to 0.8. B-scan ultrasonography revealed the largest irregular apophysis which disappeared finally. Both fundus photograph and indocyanine green angiography showed the chorioretinal lesions disappearing.

Conclusion: Endogenous fungal endophthalmitis caused by corticosteroid impulse therapy is noteworthy and under this situation antifungal treatment should be considered even if the culture is negative for fungi.

Keywords: Endogenous fungal endophthalmitis; Corticosteroid impulse therapy; Systemic antifungal treatment

Introduction

Endogenous fungal endophthalmitis (EFE) is a rare but serious complication of fungal sepsis and the incidence has increased in the past half century because of the advent of antibiotics and indwelling catheters [1]. The most common cause of culture-proven EFE is *Candida* species [2]. Although a particular therapeutic regimen has not been prospectively established, treatment options can include intraocular, systemic antifungal treatment and vitrectomy. However, fungal endophthalmitis caused by the corticosteroid impulse therapy is less reported. Here, we report, the successful management of fungal endophthalmitis in a patient with multiple diseases and unstable systemic status with oral voriconazole, but cerebral spinal fluid (CSF) and sputum cultures are always negative for fungi.

Case Report

A 40-year-old Chinese female from Beijing presented with pain, diminution of vision in the right eye in October 9, 2010 and limited outreach, intraocular about 40° in the right eye and bilateral proptosis measuring 10 mm on the left eye, 13 mm on the right eye for 12 months. She had multiple underlying medical problems, which included myasthenia gravis (IIb), diabetes mellitus and hypothyroidism. Because her limb was progressively powerless for ten month, she had been treated with high dose of methyl prednisolone pulse therapy (1000 mg i.v.gtt) for one week in September 19, 2010. After that she had cough, expectoration and low grade fever for 20 days, but no symptomatic chill, nausea, diarrhea and vomiting. An extensive physical examination and laboratory work-up had been made by her internist and was found to be negative for bacterial infections or neoplastic disease. Examinations also included X-ray, enhanced MRI of brain, Color Doppler Ultrasound, serologic tests and so on.

The visual acuity was 0.8 in the right eye and 1.0 in the left eye in July 2010. However, her visual acuity deteriorated to 0.2 in the right eye in October 9, 2010. The conjunctiva was congested in the right eye. The clinical manifestation of anterior segment was unremarkable. B-scan ultrasonography confirmed that there was an irregular apophysis at the posterior pole and temporal vitreous chamber, ranging about

13.2 mm × 10.8 mm, upheaval about 6.8 mm, with no compression. Montage color fundus photograph showed macular subretinal mass, retinal surface covered with gray exudates from one to several disc diameters in size, accompanied by localized retinal detachment and peripheral choroidal detachment in the right eye in October 18, 2010 (Figure 1A). Fluorescein angiography disclosed hypofluorescence of the chorioretinal lesions in the early stage and with the time elapse the fluorescence leakage of the central lesions gradually enhanced. The inferonasal peripheral vascular was distorted. Indocyanine green angiography (ICG) showed hypofluorescence in the corresponding lesion sites (Figure 2A). Her haemoglobin was 112 g/L with a white cell count of $2.87 \times 10^9/L$, the percent of neutrophile granulocyte was 72.8%, her erythrocyte sedimentation rate was 37 mm/1h, her C-reactive protein was 56.80 mg/L and her HIV, PPD test was negative. G test was positive (β -D-glucan was 27 pg), but CSF and sputum cultures were negative for bacteria and fungi. A chest CT showed undetermined lung exudates. Chest X-ray showed obsolete tuberculosis in the right upper lung. The enhanced MRI of brain disclosed that the right occipital had a hyperintense in the rear cingulated area of the splenium of the corpus callosum.

After consultation with many departments, specialists deemed that disease progressed so fast that there was a small risk of cancer. Immunosuppression was also taken into account. The patient was treated with intravenous voriconazole (200 mg Q12H), oral methylprednisolone (8 mg Qd8), pyridostigmine bromide (60 mg Bid), levothyroxin sodium (25 ug Qod) and iH biosynthetic human insulin injection (8 IU Qd) in October 30, 2010 for 20 days, and with clear

***Corresponding author:** Yu-ling Liu, Peking University Eye Center, Peking University Third Hospital, 49 North Garden Road, Haidian District, Beijing 100191, P.R. China, Tel/Fax: +86-10-82802791; E-mail: yulingliu@medmail.com.cn

Received June 27, 2012; Accepted July 20, 2012; Published July 25, 2012

Citation: Wang JI, Liu YI (2012) Endogenous Fungal Endophthalmitis Developing in a Myasthenia Gravis Individual Treated with High Dose Methylprednisolone. J Clin Exp Ophthalmol 3:234. doi:10.4172/2155-9570.1000234

Copyright: © 2012 Wang JI, et al. This is an open-access article distributed under the terms of the Creative Commons Attribution License, which permits unrestricted use, distribution, and reproduction in any medium, provided the original author and source are credited.

improvement of her general condition we changed the therapeutic regimen to oral voriconazole (200 mg Q12H) for 7 months. The symptom of eye pain alleviated and her visual acuity was 0.8 in the right eye. B-scan ultrasonography revealed the irregular apophysis disappeared finally. Most of the chorioretinal lesions regressed (Figure 1B, 2B). Cultures were also negative for fungi.

Discussion

Endogenous fungal endophthalmitis is less common, and it usually results from the hematogenous spread of fungi to the eye or, less commonly, spreading from the central nervous system to the eye via the optic nerve [1]. Fungus goes into the choroid around the optic nerve through teriae ciliares posteriors breves by damaging the retinohoroidal, and then spreads to the vitreous and anterior segment. Endogenous fungal endophthalmitis patients, acutely present with rapid onset of pain and severe visual loss. The central macula is often involved. A confluent, yellowish macular infiltrate begins in the choroid and subretinal space. An inferior gravitational layering of inflammatory exudates may occur in either or both the subhyaloid and subretinal space [3].

We describe a patient with undergoing high-dose steroid pulse therapy for myasthenia gravis secondary to systemic fungal infections. It is not clear that corticosteroid use increases the risk of fungemia and fungal endophthalmitis. Some reports described fungal endophthalmitis in immunocompromised patients, while several reports showed a weak association between immunosuppression and fungal endophthalmitis. In this context, corticosteroid impulse therapy increased the risk of fungal endophthalmitis.

The diagnosis of fungal endophthalmitis is difficult and may often relay on direct examination of ocular specimens or fungal cultures. The patient refused to be taken ocular specimens, and the cultures were always negative for fungi. Report shows the fungal cultures are 50% positive [4]. Although the pathogen was unremarkable, her G test was positive (β -D-glucan was 27 pg). In patients susceptible to opportunistic infection, β -D-glucan ≥ 20 pg (90%) was considered to be a predisposing factor for the development of endogenous fungal endophthalmitis [5]. Patient with long-term use of immunosuppressive agent did not have typical clinical symptoms of fungal septicaemia. CT showed a shadow in the right upper lung, the shadow had increased with a rapid progress in 3 weeks. Brain MRI also showed the progress of hyperintense lesion in the brain. Both the chest CT and brain MRI prompted that the lesions were more like infection. But antibiotic

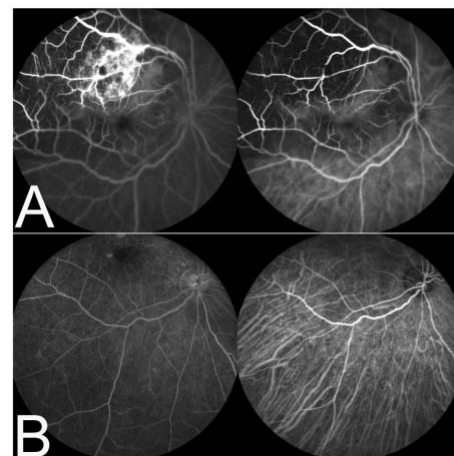


Figure 2: Indocyanine green angiography of the right eye at presentation.

- A.** ICG showing hypofluorescence of the chorioretinal lesions in the early stage, with the time elapse the fluorescence leakage of the central lesions gradually enhanced and the inferonasal peripheral vascular distorted in October 18, 2010.
- B.** ICG showing the hypofluorescence had vanished in February 18, 2011.

therapy did not help. Montage color fundus photograph revealed the chorioretinal lesions disappeared (Figure 1) and indocyanine green angiography had come to similar conclusion (Figure 2). Antifungal agents may be effective in the diagnosis.

The best treatment for endogenous fungal endophthalmitis is unclear. Systemic antifungal treatment is usually proposed, but the precise role of intraocular antifungal is currently unknown [6,7]. We treated the patient with systemic voriconazole treatment, which has a broad-spectrum of action against *Aspergillus sp*, *Blastomyces dermatitidis*, *Candida sp*, *Paecilomyces lilacinus*, *Coccidioides immitis*, *Cryptococcus neoformans*, *Histoplasma capsulatum*, *Penicillium sp*, *Scedosporium sp*, *Curvularia sp*, and others [8]. Voriconazole is mainly used for the treatment of immunosuppressive patients with progressive, potentially life-threatening infection. Report shows voriconazole is as effective as the regimen of amphotericin B followed by fluconazole in the treatment of candidaemia in nonneutropenic patients, and with fewer toxic effects [9]. Considering the patient's brain lesions, voriconazole can cross the blood brain barrier, but amphotericin B can't do that. Therefore, we prefer voriconazole instead of amphotericin B in the treatment of fungal septicaemia. Fortunately, despite the pathogenic diagnosis being unclear, the result is remarkable.

We present this case to increase awareness to the diagnosis of fungal endophthalmitis in immunosuppressive patients even though the culture is negative for fungi and alert the clinician to the possibility of systemic voriconazole treatment when making the decision for empirical therapy in suspected.

References

- Samir N, D'Amico DJ (1996) Endogenous fungal endophthalmitis. Int Ophthalmol Clin 36: 147-162.
- Essman TF, Flynn HW Jr, Smiddy WE, Brod RD, Murray TG, et al. (1997) Treatment outcomes in a 10-year study of endogenous fungal endophthalmitis. Ophthalmic Surg Lasers 28:185-194.
- Weishaar PD, Flynn HW Jr, Murray TG, Davis JL, Ban CC, et al. (1998) Endogenous aspergillus endophthalmitis : clinical features and treatment outcomes. Ophthalmology 105:57-65.

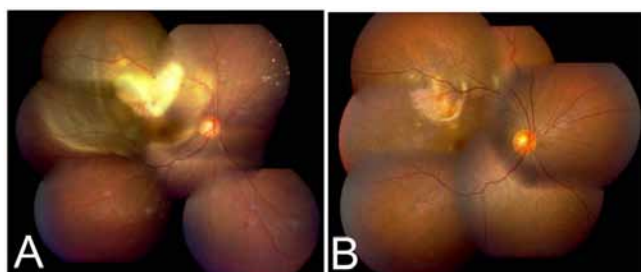


Figure 1: Montage color fundus photograph of the right eye.

- A.** Montage color fundus photograph showing macular subretinal mass, retinal's surface with gray exudates from one to several disc diameters in size, accompanied by localized retinal detachment and peripheral choroidal detachment in the right eye in October 18, 2010.
- B.** Montage color fundus photograph showing that the multifocal, gray chorioretinal lesions had disappeared in February 18, 2011.

4. Boon ME, Barlow Y, Marres EM, Milios J (1998) Microwave-stimulated Jones-Marres method for staining fungi in brain tissue of immunocompromised patients. *Methods* 15: 141-149.
5. Tanaka M, Kobayashi Y, Takebayashi H, Kiyokawa M, Qiu H (2001) Analysis of predisposing clinical and laboratory findings for the development of endogenous fungal endophthalmitis: a retrospective 12-year study of 79 eyes of 46 patients. *Retina* 21: 203-209.
6. Foos RY, Zakka KA, Coccidioidomycosis. (1996) In: Pepose JS, Holland GN, Wilhelmus KR, eds. *Ocular Infection and Immunity*. St Louis: Mosby-Yearbook Inc, 1430-1436.
7. Moororthy RS, Rao NA, Sidikaro Y, Foos RY (1994) Coccidioidomycosis iridocyclitis. *Ophthalmology* 101:1923-1928.
8. Breit SM, Hariprasad SM, Mieler WF, Shah GK, Mills MD, et al. (2004) Management of endogenous fungal endophthalmitis with voriconazole and caspofungin. *Am J Ophthalmol* 130: 135-140.
9. Kullberg BJ, Sobel JD, Ruhnke M, Pappas PG, Viscoli C, et al. (2005) Voriconazole versus a regimen of amphotericin B followed by fluconazole for candidaemia in non-neutropenic patients: a randomised non-inferiority trial. *Lancet* 366: 1435-1442.