

## Mesenchymal Hamartoma of the Liver Mimicking Hydatid Cyst

Erman Atas<sup>1</sup>, Metin Demirkaya<sup>1\*</sup>, Vural Kesik<sup>1</sup>, Necati Balamtekin<sup>2</sup> and Murat Kocaoglu<sup>3</sup>

<sup>1</sup>Gülhane Military Medical School, Department of Pediatric Oncology, Ankara, Turkey

<sup>2</sup>Gülhane Military Medical School, Department of Pediatric Gastroenterology, Ankara, Turkey

<sup>3</sup>Gülhane Military Medical School, Department of Radiology, Ankara, Turkey

### Abstract

Mesenchymal hamartomas are the second most common benign tumor of the liver in the pediatric age group. Cystic mesenchymal hamartoma of the liver must be distinguished from other liver tumors such as infantile haemangioendothelioma, hepatoblastoma and biliary rhabdomyosarcoma are all described and there can be considerable overlap in their radiological appearance. Some children with cystic mesenchymal hamartoma have been inappropriately treated for presumed hydatid disease. We report a 2-year-old boy with mesenchymal hamartoma mimicking hydatid cyst.

**Keywords:** Mesenchymal hamartoma; Liver; Children; Hydatid disease

### Introduction

Mesenchymal hamartomas are the second most common benign tumor of the liver in the pediatric age group, and represents about 6% of all primary hepatic tumors [1]. The most common manifestation is abdominal enlargement with a palpable mass and/or distension [2]. Patients are generally asymptomatic and diagnosed accidentally. It can occur from newborn to 10 years with a median age of 10 months [3]. The tumor is mainly cystic but occasionally a solid component is observed.

The diagnosis of large cystic hepatic masses in children is often difficult. Cystic mesenchymal hamartoma of the liver (MHL) must be distinguished from other liver masses such as hydatid cyst, infantile haemangioendothelioma, hepatoblastoma and biliary rhabdomyosarcoma which can be considerable overlap in their radiological appearance [4]. Both lesions can represent with a cystic component with a septated wall and concomitant solid component. Cyst hydatid is a common parasitic disease frequently involving the liver that is endemic in certain parts of the world (52%–77%) [5]. Some children with cystic mesenchymal hamartoma have been inappropriately treated for presumed hydatid disease [6,7]. Thus, the disease should be evaluated in differential diagnosis of a patient with liver mass.

Herein, we report a 2-year-old boy with mesenchymal hamartoma mimicking hydatid cyst radiologically after ultrasonography and tomography.

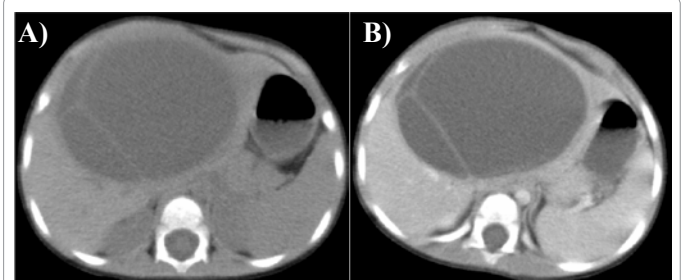
### Case Report

A 2-year-old boy was admitted with head trauma to emergency department. On physical examination there was a mass in the liver region and prominent superficial veins. On history the mass was noticed by his family six months ago beginning with a small protuberance. The mass was firm, smooth surfaced, immobile and approximately 10 cms in diameter. Laboratory tests including complete blood count, prothrombin time, activated partial thromboplastin time, bilirubin,  $\beta$ -hCG,  $\alpha$ -fetoprotein (AFP) and B and C hepatitis serology were normal. Liver enzymes were moderately elevated [aspartate amino transferase (AST) : 249 U/L (N:10-40), alanine aminotransferase (ALT) : 146 U/L, (N:10-40), and gamma glutamyl transferase (GGT) : 140 U/L (N:10-49) ]. On abdominal ultrasonography (USG), a cystic lesion

that was 11x9 cm in diameter with smooth margins and septations were observed at the left lobe of liver. The patient has a history of a contact with a dog nine months ago. ELISA serology for Echinococcus was negative. Abdominal computed tomography (CT) and magnetic resonance imaging (MRI) showed a well-defined and septated left liver lobe mass. The mass has low density on CT, low T1 and high T2 signal intensities with septal enhancement (Figure 1A, B). The rim of the cyst was hypointense and hyperintense on T1 and T2 weighted MRI, respectively (Figure 2A, B, C). No calcification was observed. The patient underwent surgery (Figure 3). The mass contained moderate fluid collection. Histopathological findings, loose mesenchymal tissue and branched, tortuous bile ducts were the key diagnostic features. These pathologic findings of the mass was consistent with mesenchymal hamartoma. The patient was now good in condition for 6 months.

### Discussion

Mesenchymal hamartoma is a rare benign tumor with heterogeneous



**Figure 1:** Pre (A) and post contrast (B) axial CT scans show a well-defined, multi-septated left liver lobe cyst. The cyst wall and septae are isodense to the liver parenchyma with contrast enhancement.

**\*Corresponding author:** Metin Demirkaya, Gülhane Military Medical School, Department of Pediatric Oncology, 06018, Etlik, Ankara, Turkey, Tel: 00 90 312 3041925; Fax: 00 90 312 3044381; E-mail: demirkayametin@hotmail.com

**Received** February 07, 2012; **Accepted** March 26, 2012; **Published** March 28, 2012

**Citation:** Atas E, Demirkaya M, Kesik V, Balamtekin N, Kocaoglu M (2012) Mesenchymal Hamartoma of the Liver Mimicking Hydatid Cyst. *Pediatr Therapeut* 2:120. doi:10.4172/2161-0665.1000120

**Copyright:** © 2012 Atas E, et al. This is an open-access article distributed under the terms of the Creative Commons Attribution License, which permits unrestricted use, distribution, and reproduction in any medium, provided the original author and source are credited.

presentation such as solid, cystic and mixed variants with varying degrees of vascularity [7,8]. The cystic ones are characterized by an admixture of epithelial structures in a loose connective tissue stroma with fluid accumulation [9,10]. The most common manifestation is abdominal enlargement with a palpable mass and/or distension. The patients are usually asymptomatic and incidentally diagnosed like our patient when they present with right upper quadrant mass, respiratory distress, fever or unrelated symptoms [2,3]. Although liver function tests usually remain within normal limits, liver enzymes were moderately elevated [11]. Our case was presented with elevated liver enzymes.

On CT scan, it presents as a complex mass containing areas of low attenuation separated by solid septae and stroma which enhance with intravenous contrast administration [12]. There are no typical findings on CT and USG. Mesenchymal hamartoma can show a wide radiologic spectrum from a multiseptated cystic tumor to a mixed solid and cystic tumor, and a solid tumor [13]. Thus, MHL is often misdiagnosed because of its diversified image. In our case, the lesion was presented with findings similar to hydatid cyst. It is unable to differentiate MHL from a hydatid cyst due to the predominant cystic nature and solid component. MHL is occasionally misdiagnosed because of its diversified image. Thus, MRI was used for differential diagnosis [9]. As a general perspective as in our case lesions of mesenchymal predominance

are hypointense on T1W. Cystic predominant lesions are of variable intensity on T1W and hyperintense on T2W images [12].

Hydatid disease continues to be endemic in the Mediterranean countries, the Middle and Far East, and South America, but it has a worldwide distribution because of travel and migration. The detection of specific antigens and immune complexes of the cyst with ELISA yields a positive result in more than 90% of patients [14,15]. Ultrasonography is a noninvasive and sensitive imaging technique, which is also cost-effective, widely used in diagnosis. The specificity of USG reaches up to 90% [14]. The cases with negative ELISA test has to be evaluated with further radiologic investigation like CT or MRI. On non-contrast enhanced CT scans, hydatid cyst wall is relatively hyperdense to the liver parenchyma without contrast enhancement. In addition, T2 hypointensity of the cyst wall has been considered typical for hydatid cyst [16]. None of these features was present in our case.

Hydatid cyst is a common health problem in developing countries. Although simple radiologic tests like USG is sufficient in most cases, CT and MRI come into the choice for the ones with negative serologic tests for *Echinococcus* and diverse ultrasonographic findings. Cystic mesenchymal hamartoma is the major hepatic lesion under 5 years in the differential diagnosis.

#### References

- Weinberg AG, Finegold MJ (1983) Primary hepatic tumors of childhood. *Hum Pathol* 14: 512-537.
- Yen JB, Kong MS, Lin JN (2003) Hepatic mesenchymal hamartoma. *J Paediatr Child Health* 39: 632-634.
- Stocker JT, Ishak KG (1983) Mesenchymal hamartoma of the liver: report of 30 cases and review of the literature. *Pediatr Pathol* 1: 245-267.
- Kaufman RA (1992) Is cystic mesenchymal hamartoma of the liver similar to infantile hemangioendothelioma and cavernous hemangioma on dynamic computed tomography? *Pediatr Radiol* 22: 582-583.
- Morris D, Richards K (1992) Hydatid disease. Oxford: Butterworth-Heinemann.
- Smith SL, Ramli NM, Somers JM (2001) Cystic mesenchymal hamartoma mimicking hepatic hydatid disease. *Clin Radiol* 56: 599-601.
- Karpelowsky JS, Pansini A, Lazarus C, Rode H, Millar AJ (2008) Difficulties in the management of mesenchymal hamartomas. *Pediatr Surg Int* 24: 1171-1175.
- Cetin M, Demirpolat G, Elmas N, Yüce G, Cetingül N, et al. (2002) Stromal predominant type mesenchymal hamartoma of liver: CT and MR features. *Comput Med Imaging Graph* 26: 167-169.
- Ye BB, Hu B, Wang LJ, Liu HS, Zou Y, et al. (2005) Mesenchymal hamartoma of liver: magnetic resonance imaging and histopathologic correlation. *World J Gastroenterol* 11: 5807-5810.
- Srouji MN, Chatten J, Schulman WM, Ziegler MM, Koop CE (1978) Mesenchymal hamartoma of the liver in infants. *Cancer* 42: 2483-2489.
- Stringer MD, Alizai NK (2005) Mesenchymal hamartoma of the liver: a systematic review. *J Pediatr Surg* 40: 1681-1690.
- Dwivedi MK (2001) Mesenchymal hamartoma. *Indian J Radiol Imaging* 11: 41-42.
- Kim SH, Kim WS, Cheon JE, Yoon HK, Kang GH, et al. (2007) Radiological spectrum of hepatic mesenchymal hamartoma in children. *Korean J Radiol* 8: 498-505.
- Sayek I, Tirnaksiz MB, Dogan R (2004) Cystic hydatid disease: current trends in diagnosis and management. *Surg Today* 34: 987-996.
- Carmena D, Benito A, Eraso E (2006) Antigens for the immunodiagnosis of *Echinococcus granulosus* infection: An update. *Acta Trop* 98: 74-86.
- Pedrosa I, Saiz A, Arrazola J, Ferreirós J, Pedrosa CS (2000) Hydatid disease: radiologic and pathologic features and complications. *Radiographics* 20: 795-817.

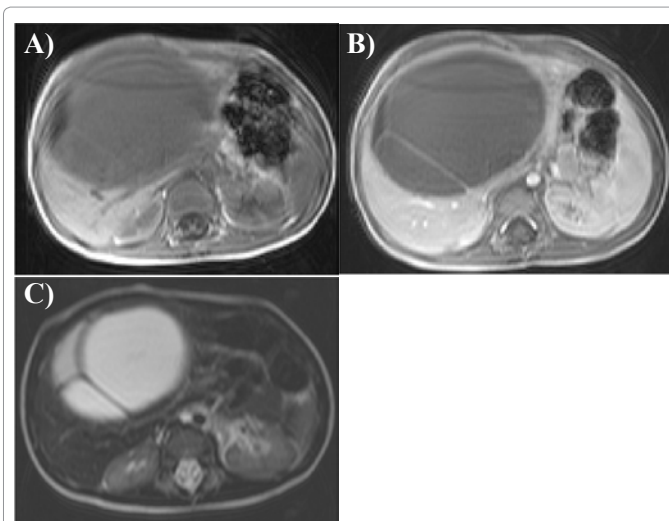


Figure 2: Axial MR scans at the level of upper abdomen reveal a low T1 (A), high T2 (C) cyst with rim and septal enhancement on postcontrast T1 image (B).

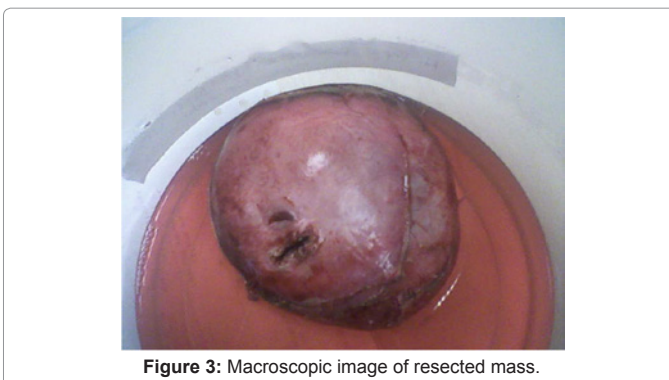

Figure 3: Macroscopic image of resected mass.