

Malignant Pheochromocytoma: A Case Report

Sajjad Ahmad, Kishwar Ali, Humera Latif and Ishtiaq Ali Khan*

Ayub Medical College, Abbottabad, Pakistan

*Corresponding author: Ishtiaq Ali Khan, Assistant professor of surgery, Ayub Medical College, Abbottabad, Pakistan, Tel: 0923459605748; Email: drishtiaq71@yahoo.com

Received date: July 23, 2014, Accepted date: August 22, 2014, Published date: August 29, 2014

Copyright: © 2014 Khan IA, et al. This is an open-access article distributed under the terms of the Creative Commons Attribution License, which permits unrestricted use, distribution, and reproduction in any medium, provided the original author and source are credited.

Abstract

Pheochromocytoma is a tumor of adrenal medulla, derived from catecholamine producing chromaffin cells. Majority of the patients present with headache, palpitations and sweating. It is diagnosed by 24 hour urinary VMA (Vinyl Mendelic Acid) measurements and localization is done by MRI and 123I MIBG scanning. Treatment is essentially surgical with adequate preoperative blood pressure control. Undiagnosed patients can suffer catastrophic consequences while undergoing surgery for some other condition. Ten percent of these tumors are malignant with metastasis to liver, bone and lymph nodes. We present a case of malignant Pheochromocytoma whose VMA level was within normal limits however perioperative findings and histopathology proved it to be malignant.

Keywords: Malignant Pheochromocytoma; Catecholamines; Hypertension; Paragangliomas

Introduction

Pheochromocytoma is a functioning tumor of adrenal medulla, derived from catecholamine producing chromaffin cells [1]. Derived from the Greek phrase meaning dusky and chroma meaning colour, the tumor is characterized by a syndrome resulting from excess catecholamine production [1]. The condition was first described in 1886 by Frankel and in 1926. It was first time successfully removed surgically by Roux in Lousanne [1]. It is known as the “ten percent tumor” as ten percent of tumors are inherited, ten percent are extra adrenal, ten percent are malignant, ten percent are bilateral and ten percent occur in children [2]. The prevalence of Pheochromocytoma in patient with hypertension is 0.1-0.6 %. Ninety percent of patients presenting with a combination of headache, palpitations and sweating have Pheochromocytoma [2].

Diagnosis is established by 24 hour urinary VMA levels [3]. MRI is preferred for localization because contrast media used in CT scan can provoke paroxysms. 123I MIBG (Meta iodo benzyl guanidine) scan will identify ninety percent of primary tumors and is essential for the detection of multiple extra adrenal tumors and metastasis [2].

Laparoscopic resection is nowadays a routine treatment of Pheochromocytoma. If tumor is larger than 8-10 cm or radiological signs of malignancy are detected, an open approach is considered [2]. Preoperatively it is vital to control blood pressure because anesthetic induction or minimal manipulation of adrenal or extra adrenal tumors during surgery may cause dangerous fluctuations in blood pressure [4]. The agent of choice is long acting alpha adrenergic blocker, phenoxybenzamine. Beta blockade with propranolol is instituted 3-4 days prior to surgery. Beta blockade should not be used without prior alpha blockade, as unopposed vasoconstriction can lead to potentially catastrophic hypertension [4].

Post-operative intensive care monitoring should be done for 24 hours as hypovolaemia and hypoglycaemia may occur [5]. Lifelong yearly biochemical tests should be performed to identify recurrent,

metastatic or metachronous tumors [5]. In undiagnosed patients with Pheochromocytoma, death may ensue from Myocardial infarction, cerebrovascular accidents during or immediately after even a minor surgical operation [1].

Case Report

A 65 years old female presented in surgical outpatient department of Ayub Teaching Hospital with complaints of upper abdominal pain, headache, palpitations and sweating since 2 months. She was admitted for workup. On detailed inquiry she had upper abdominal pain off/on radiating to back. The pain was not associated with food intake or other gastrointestinal symptoms, jaundice, fever or cardio respiratory problems. She was also complaining of paroxysmal headache, palpitations and sweating associated with dizziness. Her systemic inquiry was unremarkable. No significant past history was given.

On examination her pulse was 95 beats per minute, regular, good volume and blood pressure was 190/110 mm of Hg. On abdominal examination a 10×10 cm mass was palpable in the right hypochondrium and lumbar region. The mass was immobile, mildly tender, with ill-defined margins and smooth surface without any bruit. All baseline investigations were within normal limits.

Pheochromocytoma was clinically suspected, therefore 24 hourly urinary VMA levels were performed which were normal. Ultrasound abdomen showed 11.7×11.6×12.4 cm size solid, well demarcated (encapsulated) mass at upper pole of right kidney. Spiral CT scan of abdomen showed huge solid mass measuring 13×11×14 cm in right supra renal space as shown in (Figure 1). Remaining abdominal viscera were normal on scan. IVU (Intravenous urography) displayed right large renal mass at upper pole causing downward displacement of calyces with normal excretion.

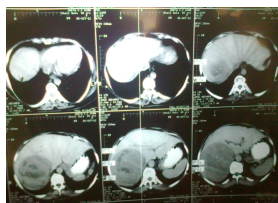


Figure 1: Right side pheochromocytoma

Surgical exploration of the mass was decided. Preoperatively blood pressure was controlled with alpha blockers and beta blockers were added one week before surgery. Her surgery was planned after full preparation and discussion with the anesthetist. On exploration a mass of about 10×10 cm was found at right suprarenal area that has invaded the right kidney. Para aortic lymph nodes were not enlarged and liver appeared normal. Total mass excision has been performed along with right nephrectomy (Figure 2). The whole specimen was sent for histopathology. Patient's condition during surgery and post operatively was stable. Biopsy of the specimen revealed that the tumor composed of adrenal tissue suggestive of Pheochromocytoma. The lesions was focally infiltrating into renal parenchyma. Vascular invasion was also seen. All resected margins were tumor free.

Post-operative bone scan was performed which was normal. She was referred to oncology for adjuvant chemoradiotherapy.

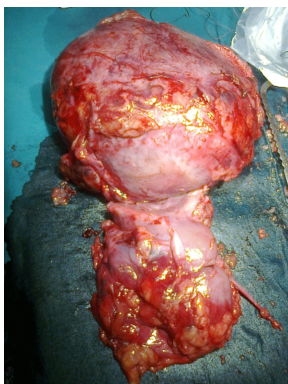


Figure 2: Specimen of right sided pheochromocytoma with kidney

Discussion

Pheochromocytoma is tumors of the adrenal medulla and of chromaffin tissues in the other parts of body (paragangliomas). They secrete epinephrine or nor epinephrine, resulting in sustained or episodic hypertension and other symptoms of catecholamine excess [6].

Pheochromocytoma is found in less than 0.1% of patients with hypertension and accounts for about 5% of adrenal tumors incidentally discovered by CT scanning. Most Pheochromocytomas occur sporadically, but they may be associated with various familial syndromes such as multiple endocrine neoplasia (MEN) 2A (medullary thyroid carcinoma, Pheochromocytoma, and hyperparathyroidism), MEN 2B (medullary thyroid carcinoma,

Pheochromocytoma, mucosal neuromas, marfanoid habitus, and ganglioneuromatosis), von Recklinghausen disease, von Hippel-Lindau disease [5].

Essentials of diagnosis for Pheochromocytoma are hypertension, frequently sustained, with or without paroxysms, episodic headache, excessive sweating, palpitation, and visual blurring, postural tachycardia and hypotension, elevated urinary catecholamines or their metabolites, hyper metabolism and hyperglycemia [3,6]. Our patient had paroxysmal hypertension, headache, sweating and dizziness but her urinary VMA levels were normal.

Urinary output of metanephrines and/or free catecholamines is elevated in more than ninety five percent of patients with pheochromocytoma. However many drugs and diet can interfere with the results of VMA6. Chen and Yin-Yu [7] reported a case of pheochromocytoma with hypertension having normal urinary VMA levels but the tumor was benign and in our case the tumor was malignant.

Approximately ten percent of pheochromocytomas are malignant. This rate is high in extra adrenal tumors (paragangliomas). The diagnosis of malignancy implies metastasis of chromaffin tissue, most commonly to bone, lymph nodes and liver [2,8,9]. Cytological findings cannot be used to determine whether a Pheochromocytoma is malignant or benign. The veins and capsules may also be invaded even in clinically benign tumors. Malignancy can only be diagnosed in the presence of metastases or invasion into surrounding tissues [6]. In our case the tumor was invading the kidney.

About eight percent of patient with an apparently benign Pheochromocytoma subsequently develops metastasis [2]. Surgical excision is the only chance for cure. Even in patients with metastatic disease, tumor debulking can be considered to reduce the tumor burden and to control the catecholamine excess [2]. Symptomatic treatment can be obtained with alpha blockers. Mitotane can be used as adjuvant or palliative treatment [2]. Treatment with ¹³¹I MIBG or combination chemotherapy has resulted in a partial response in thirty percent and an improvement of symptoms in eighty percent of patients. Five year survival rate is less than fifty percent in malignant pheochromocytoma [2].

In conclusion pheochromocytoma is a rare but clinically important disorder because of its high morbidity and mortality. Surgical removal is the mainstay of treatment. Even in case of normal biochemical studies, the tumor should be removed.

Limitation

Thyroid profile of the patient should have been checked to exclude MEN's syndrome that has not been performed.

References

1. Wheeler MH, Sadler GP (2002) disorders of the adrenal glands. In: Cuschieri SA, Steele RJ, Moossa AR, editors. *Essential surgical practice*. (4th edn) UK: Arnold Ltd, 131-36.
2. Rothmund M (2008) Adrenal glands and other endocrine disorders. In: Williams NS, Bulstrode CJK, O'Connell PR, editors. *Bailey and Love's short practice of surgery*. (25th edn) UK: Edward Arnold Ltd, 813-14.
3. Pacak K (2011) Phaeochromocytoma: a catecholamine and oxidative stress disorder. See comment in PubMed Commons below *Endocr Regul* 45: 65-90.

-
4. Zuber SM, Kantorovich V, Pacak K (2011) Hypertension in pheochromocytoma: characteristics and treatment. *Endocrinol Metab Clin North Am* 40: 295-311, vii.
 5. Därr R, Lenders JW, Hofbauer LC, Naumann B, Bornstein SR, et al. (2012) Pheochromocytoma - update on disease management. *Ther Adv Endocrinol Metab* 3: 11-26.
 6. Duh QY, Liu C, Tyrrell JB, Adrenals. In: Doherty GM, *Current Diagnosis and treatment: surgery*. (13thedn) USA: McGraw Hill companies, 737-50.
 7. Chen, Yin-Yu (2009) Pheochromocytoma Presenting with Normal Urinary Catecholamines and Metabolites: A Case Report." *Formos J Endocrin Metab* 1: 33-37.
 8. Zelinka T, Musil Z, Duskova J, Burton D, Merino MJ, et al. (2011) Metastatic pheochromocytoma: does the size and age matter? *Eur J Clin Invest* 41: 1121-1128.
 9. Garg MK, Kharb S, Brar KS, Gundgurthi A, Mittal R (2011) Medical management of pheochromocytoma: Role of the endocrinologist. *Indian J Endocrinol Metab* 15 Suppl 4: S329-336.