

Lung Cancer is Diagnosed: An Image Article

OPEN ACCESS Freely available online

Aakriti Khandelwal*

Department of Cancer, Yangtze University, Jingzhou, Hubei, Shilong

Image Article

IMAGE ARTICLE

After an irregular spot is found on a chest X-ray taken to evaluate a cough or chest pain, lung cancer is also suspected [1]. But since this test can ignore early cancers, further testing is needed to validate (or rule out) the diagnosis of lung cancer [2]. This will involve a computed tomography (CT) scan of the chest and a biopsy whether a nodule or mass is detected. Knowing all of some of the treatments that might be prescribed to figure out if an abnormality is benign (noncancerous) or malignant is useful (cancerous). If the latter, more tests are conducted to see if the cancer has spread to other parts of the body (metastasized) and to assess the stage of the disease [3,4].

PHYSICAL EXAMINATION

A surgeon will conduct a detailed history and physical examination while lung cancer is suspected. It is performed to assess lung cancer symptoms and risk factors, and to check at any clinical signs that indicate the condition. These can include:

- Abnormal lung sounds
- Enlarged lymph nodes
- Unintentional weight loss
- Clubbing of the fingernails (chubby fingernails)

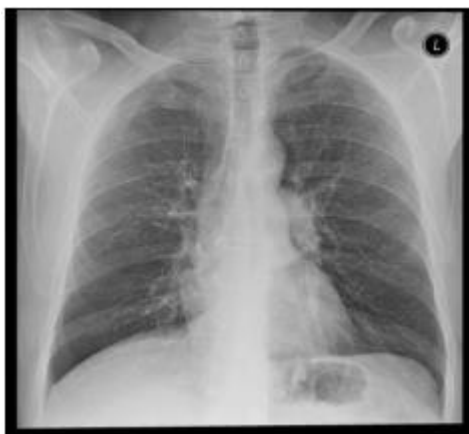

Figure 1: Lung Cancer X-Ray.

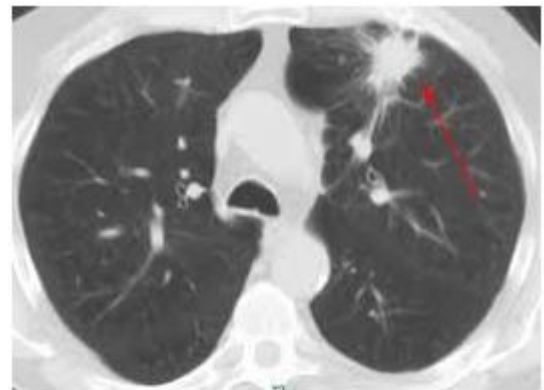


Figure 2: Cyst of a cancer found.

REFERENCES

1. Fattorini D, Regoli F. Role of the chronic air pollution levels in the Covid-19 outbreak risk in Italy. *Environ Pollut.* 2020;264:114732.
2. Updated Containment Plan for Large Outbreaks of COVID-19. Guidelines; Ministry of Health and Family Welfare, Government of India.
3. COVID-19 Testing Strategy for India. Guidelines; Ministry of Health and Family Welfare, Government of India.
4. Infection Control practices for Covid-19. Guidelines; Ministry of Health and Family Welfare, Government of India.

Correspondence to: Rabiul Ahasan, Department of Medicine Universiti Sultan Zainal Abidin, Malaysia, E-mail: alaminkuet01@gmail.com

Received: January 12, 2021; Accepted: January 18, 2021; Published: January 25, 2021

Citation: Ahasan R (2021) Carcinoma of the Adrenocortical System. *J Med Diagn Meth.* 10:315. doi: 10.35248/2168-9784.2021.10.315

Copyright: © 2021 Ahasan R. This is an open-access article distributed under the terms of the Creative Commons Attribution License, which permits unrestricted use, distribution, and reproduction in any medium, provided the original author and source are credited.