

Ludwig's Angina: Paediatric Case Report and Literature Review

Brotherton H^{1*}, Templeton K², Rowney DA³ and Montague ML⁴

¹Department of Medical Paediatrics, The Royal Hospital for Sick Children, Edinburgh, Scotland, UK

²Department of Medical Virology, Royal Infirmary of Edinburgh, Edinburgh, Scotland, UK

³Department of Anaesthesia and Critical Care, The Royal Hospital for Sick Children, Edinburgh, Scotland, UK

⁴Department of ENT Surgery, The Royal Hospital for Sick Children, Edinburgh, Scotland, UK

*Corresponding author: Dr Helen Brotherton, Paediatric Speciality Registrar, Royal Hospital for Sick Children, 9 Sciennes Road, Edinburgh, UK, Tel: 0131-5360000; E-mail: helenbrothert9@hotmail.com

Received date: August 11, 2014, Accepted date: October 09, 2014, Published date: October 16, 2014

Copyright: © 2014 Brotherton H, et al. This is an open-access article distributed under the terms of the Creative Commons Attribution License, which permits unrestricted use, distribution, and reproduction in any medium, provided the original author and source are credited.

Abstract

Ludwig's Angina (LA) is an uncommon but potentially fatal cellulitis of the submandibular space, complicated by contiguous spread of infection within the respiratory tract and acute airway obstruction. A 13 month-old female developed LA following upper respiratory tract infection with Parainfluenza-3 virus. There was rapid deterioration due to acute airway obstruction and emergency endotracheal intubation was necessary. A literature review identified thirty-five paediatric cases of LA with a 14% mortality rate. It occurs predominantly in immunocompetent children with an odontogenic source of infection in a third and unknown source of infection in a third of cases. This is the first reported case of a child with preceding respiratory viral infection who developed LA and it is proposed that respiratory viruses may play a previously unrecognized role in the aetiology of Ludwig's angina in children.

Keywords: Children; Cellulitis; Ludwig's angina; Submandibular space

Introduction

Ludwig's Angina (LA) is a rapidly progressive soft tissue cellulitis of the sub-mandibular space, first described by Hippocrates in the 4th century BC as producing a tongue which "... from a soft consistency it grows hard, instead of being flexible, it becomes inflexible, so that the patient would soon be suffocated unless speedily relieved" [1]. In 1836 German surgeon Wilhelm Frederick von Ludwig described the necropsy features [2] and a century later Grodinsky and Holyoke outlined specific clinical criteria for diagnosis (Table 1) [3].

S.no	Criteria
1	Bilateral cellulitis involving the sublingual and submaxillary spaces
2	Produces gangrene with serosanguinous, putrid infiltrate but very little or no frank pus
3	Involves connective tissue, fascia and muscles but not the glandular structures
4	Spread by continuity not by lymphatics

Table 1: Grodinsky and Holyoke's criteria for the diagnosis of Ludwig's angina

Over the past sixty years LA has been less frequently reported due to improvements in dental hygiene and widespread antibiotic use. It is more prevalent in adults but up-to a third of cases are reported in children [2,4]. An understanding of the anatomy of the sub-mandibular space is essential to appreciate the clinical features and potential severity of this infection. The sub-mandibular space is located under the floor of the mouth and is composed of two

interconnected spaces, sub-lingual and sub-maxillary, which are separated by the mylohyoid muscle. The sub-lingual space is above the mylohyoid and is bound superiorly by the floor of the mouth. The sub-maxillary space is inferior to the mylohyoid with the digastric muscle as its inferior border. The infection begins in the sub-maxillary space and ascends via the free posterior edge of the mylohyoid into the sublingual space. This explains the clinical features of a painful, diffuse, brawny swelling of the neck followed by elevation and posterior displacement of the tongue and floor of the mouth with acute airway compromise.

A case of Ludwig's angina in a thirteen month-old girl is presented with a literature review of paediatric cases.

Case Report

A thirteen month-old female was presented with fever, diffuse symmetrical swelling of the neck (Figure 1) and an elevated tongue. This was preceded by five days of coryza and maculo-papular rash. She was previously well and fully immunized according to the UK schedule. Twelve hours following admission to the local hospital and initial treatment with intravenous benzyl penicillin and flucloxacillin her clinical condition deteriorated with increasing respiratory distress, stridor and cyanosis. The neck swelling also increased in size. Emergency oropharyngeal intubation was performed, intravenous hydrocortisone was given and she was transferred to the Paediatric Intensive Care Unit (PICU) by the specialist retrieval team.

On admission to PICU, her temperature was 38.2°C, heart rate 140 beats per minute, respiratory rate 30 breaths per minute, and oxygen saturations 99% in 40% oxygen. The neck swelling was diffuse and indurated bilaterally with widespread erythema and her tongue was elevated. The rest of systemic examination was normal.

A neck ultrasound showed gross subcutaneous oedema with no abscess. White cell count was 6.1x10⁹ with left shift and CRP 189.

Blood culture was sterile. A nasopharyngeal aspirate was positive for parainfluenza-3 virus on PCR analysis and endotracheal aspirates were positive for *Haemophilus influenzae* (HI) and *Moraxella catarrhalis* on culture. Both samples were taken within twenty-four hours of admission to PICU and the HI was a non-beta-lactamase producing strain sensitive to amoxicillin. Chest X-ray on admission was normal but over the initial twenty-four hours the oxygen and ventilator pressure requirements increased. Repeat chest X-ray showed right upper and middle zone opacification consistent with pneumonia. The neck swelling improved over 48 hours but she was intubated and ventilated for five days due to pneumonia. IV cefotaxime and flucloxacillin were given for one week and IV dexamethasone for five days. No surgical intervention was required. She was transferred from PICU after six days and discharged from hospital after a further six days.

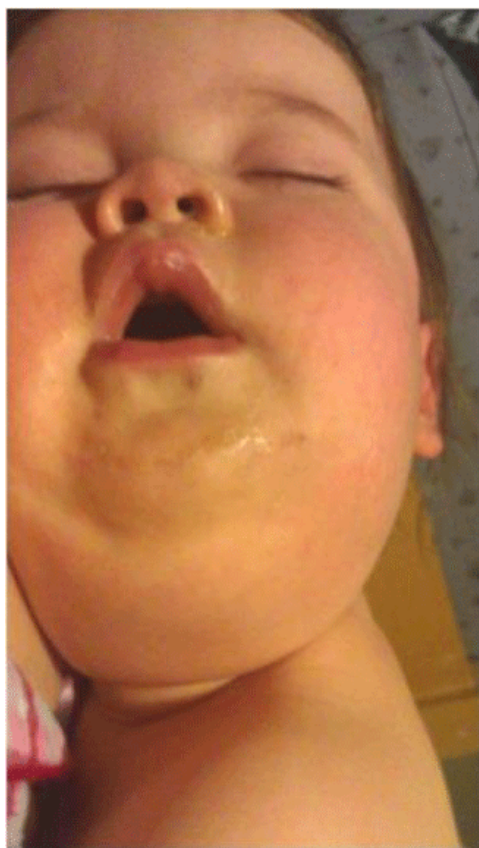


Figure 1: Diffuse bilateral “bull neck” swelling typical of Ludwig's angina in a thirteen month-old child just prior to emergency intubation for acute airway.

Methods

An English language literature search using MEDLINE was carried out using the MeSH term "Ludwig's Angina"[Majr], last searched September 2014. All abstracts and, where available full text articles, were reviewed and case reports and case series including patients aged sixteen years or less were selected. All related citations were viewed to identify relevant cases.

Results

Thirty-four cases of Ludwig's angina in patients aged sixteen years or younger were identified. Including our case this is a total of thirty-five paediatric cases in the past 60 years (Appendix 1). There were also 10 paediatric patients in a case series in India [4] and 29 paediatric cases in a large series from Iran [5] but with insufficient clinical details for analysis. A child with Hyper-IgE syndrome and sub-mandibular abscess was also identified who did not meet the diagnostic criteria for LA as defined by Grodinsky [6].

Demographics

Age ranged from twelve days to fifteen years with a mean of six years nine months and a median of six years. Gender was reported in thirty cases with 70% (21/30) male and 30% (9/30) female. Cases were reported from a wide range of countries and all continents except South America.

Aetiology/Risk factors

An identified dental source of infection was present in 31.4% (11/35) of cases and of these, eight were due to an infected tooth and three occurred post tooth extraction. The first molar tooth was most commonly involved (7/11 cases). Mouth trauma was implicated in 17.1% (6/35) of cases, including a fourteen year-old child in South Africa with a mandibular fracture [1] and a thirteen year-old girl who developed LA as a complication of frenuloplasty [7]. Three cases were in children who sustained lacerations to the floor of the mouth through local trauma. A two month-old infant developed LA two days following endotracheal intubation [8], although the exact source of infection was not established and may have been secondary to overwhelming streptococcal septicaemia. A six year-old girl with a previously undiagnosed lymphangioma of the tongue developed LA secondary to local infection [9] and one child had preceding nasal trauma [10].

Including our patient, four children had a suspected or confirmed viral infection immediately prior to developing LA although in all three other cases the virus was Herpes Simplex Virus (HSV). A fourteen year-old boy who was on immunosuppressive therapy for ulcerative colitis developed LA following pharyngitis and development of vesicles on the buccal mucosa. HSV-1 was identified on viral culture and serology and the child made a dramatic clinical recovery shortly after commencing acyclovir [11]. The second case was a fifteen month-old boy with herpetic gingivostomatitis who developed LA shortly after the HSV infection. No details were given about the laboratory diagnosis of HSV [12]. The third case was a twelve year-old boy with recurrent herpes labialis and no other predisposing risk factor for LA. At the time of presentation with LA he had a crusted lesion on the lip but virological confirmation of HSV was not actively sought [13].

There was no identified source or risk factor for infection in 34.3% (12/35) of cases.

The majority of cases (30/35, 85.7%) were in previously well children with no predisposing condition. Four (11.4%) children had a background of immunocompromise including immunosuppressive therapy for inflammatory bowel disease [11], primary immunodeficiency, aplastic anaemia and previous bone marrow transplants and one child with neutropaenia and chronic malnutrition

[14]. One child had undiagnosed poorly controlled diabetes mellitus [15].

Clinical features

Presenting clinical features were available in only nineteen cases and in all there was typical bilateral neck swelling with elevation and oedema of the tongue. Signs and symptoms of upper airway obstruction were present in 28.6% (10/35) of cases.

Microbiology

A microbiological isolate was present in 42.9% (15/35) of cases and was bacterial in fourteen (40%) with one case of *Candida albicans* isolated from a mouth swab and urine culture in an immunocompromised patient [14]. There was mixed growth of bacteria in four cases (28.6%). Streptococcal species were isolated in 50% (7/14) of cases in which a bacterial cause was identified, with *Streptococcus pyogenes* in three, alpha-haemolytic streptococcus in two and unspecified or "mixed streptococcus" in two cases.

Six patients had a gram-negative bacterial infection caused by a combination of *Haemophilus influenzae*, *Pseudomonas aeruginosa* and *Moraxella catarrhalis*. Both cases of *Pseudomonas aeruginosa* were in immunocompromised patients [14].

In addition to the case described here, three other cases of paediatric LA caused by *Haemophilus influenzae* were identified, including a previously healthy five year-old child who presented in respiratory failure due to a severe upper respiratory tract infection and *Haemophilus influenzae B* (HiB) bacteraemia [16]. Similarly, a four year-old previously well boy had positive blood cultures for HiB [14] and a fourteen year-old girl with poorly controlled diabetes had a mixed bacterial isolate including *Haemophilus influenzae* from a deep wound swab [15].

Three children had staphylococcal species isolated, two cases of *Staphylococcus aureus* [1,9] and one of coagulase-negative staphylococcus identified on a nasal swab culture as part of a mixed bacterial and HSV infection [11]. Anaerobic organisms were isolated in only two cases, both as mixed growth in association with streptococcal species from deep wound swabs [1,15].

Blood cultures were taken in 34.3% (12/35) of cases, were positive in 41.6% (5/12) and were the most common method of determining microbiological aetiology.

Management

An artificial airway was used in 31.4% (11/35) of cases and was predominantly tracheal intubation (83.3%, 10/12) with two children requiring emergency tracheostomies. The route of intubation was mostly via the oral route except one child who underwent fiber-optic naso-tracheal intubation [7].

A wide range of antibiotics were used (Appendix 1) in thirty-two patients with 62.5% (20/32) treated with more than one antibiotic. One child died before antibiotics could be administered [1] and in two cases the type of antibiotic was not specified. [12,17] The majority of patients (28/32, 87.5%) were treated with penicillin or a penicillin derivative and anaerobic cover with metronidazole was provided in four cases. Steroids were administered in seven cases (20%) and surgical incision and drainage in thirteen children (37.1%).

Outcome

Complications occurred in seven patients (20%) and were predominantly septicaemia, pneumonia and empyema. Five children died, giving a mortality rate of 14% in this population. Two children died due to acute airway obstruction and three due to infective complications of septicaemia, pneumonia and empyema. Three of the children who died were immunocompromised [14].

Discussion

The predominance of male patients described here is similar to previous case-series that reported LA as two to three times more common in boys as girls [15]. In adults LA is caused by an odontogenic infection in 90 % of cases [18], however this case series found a dental risk factor in only one-third of children. There is often no precipitating factor, especially in younger children, and in this review one-third of children had no identifiable source or risk factor for infection. Ten children were aged less than 3 years and in all there was an unknown source of infection, an oral or upper respiratory tract viral infection or trauma to the mouth or nose. Thus, dental infections are not an important factor in children younger than three years.

This is the first reported case of Ludwig's angina occurring in a child with a confirmed respiratory virus and secondary bacterial infection. The virological finding is supported by clinical features of a viral-like illness prior to the development of LA. A possible pathogenesis is that primary viral infection caused inflammation of the oropharyngeal mucosa, enabling colonizing organisms to translocate into the sub-mandibular space resulting in secondary bacterial infection. It is proposed that viral respiratory infection may be a previously unrecognized factor in the development of this condition, especially in young children for whom odontogenic aetiology is less common.

As reported here and previously, streptococcus species are the most common bacteria isolated in paediatric LA [19]. According to this series, *Haemophilus influenzae* is the second most common agent. It was not possible to type the *Haemophilus influenzae* but the patient received four doses of HiB vaccine thus it is more likely to be nontypeable strain. Since the introduction of HiB vaccine in 1987, the incidence of HiB related infections in children has markedly decreased but nontypeable HI continues to cause significant upper respiratory tract disease and most strains of HI which colonise the upper respiratory tract in children are nontypeable [20].

Optimum airway management is controversial and includes tracheal intubation, emergency tracheostomy, and surgical decompression. In 1942 Taffel and Harvey advocated aggressive management of early LA with wide surgical decompression of the submandibular and sublingual spaces under local anaesthetic, resulting in a mortality rate of less than 2% [21]. An artificial airway in all patients with LA was standard practice 30 years ago [22] but there has been a recent shift towards observation in a safe environment with airway intervention by tracheal intubation only if signs of impending airway obstruction develop [23]. Paediatric patients with LA are reported to require active airway intervention less frequently than in adults and it has been suggested that the presence of dental caries, which is more common in adults, is related to a more severe progression and increased need for airway intervention [4]. This is supported by the finding that only one-third of paediatric cases reviewed here required an airway intervention and two-thirds were managed conservatively.

The mortality rate of 14 % in this series is less than previously reported (17%) [1]. Although in this review paediatric was defined as 16 years or less, compared to 18 years or less in previous reviews [1]. Also, eleven cases were reported in the last ten years, all of whom survived and the most recently reported death of a child with LA was in South Africa in 1990 [1].

Conclusion

Ludwig's Angina is an uncommon but potentially fatal submandibular cellulitis which predominantly affects immunocompetent children. It has been reported in thirty-five children over the past sixty years and is mostly complicated by septicaemia, pneumonia and acute airway obstruction. In children a third of cases have an odontogenic source, a third due to preceding viral infection or mouth trauma and a third of unknown aetiology. This case suggests that respiratory virus infection may be a previously unrecognised factor in the development of paediatric Ludwig's angina. An artificial airway is required in a third of children and there is an overall mortality rate of 14% due to either acute airway obstruction or overwhelming systemic infection.

Ethical Declaration

The parents of the patient gave written informed consent for the use of the photograph and patient details in the article.

Authors Contribution

Brotherton H selected the patient, performed the literature search and designed the article. All authors contributed to drafting the final article, revised important intellectual content and gave approval to the final version.

References

1. Britt JC, Josephson GD, Gross CW (2000) Ludwig's angina in the pediatric population: report of a case and review of the literature. See comment in PubMed Commons below *Int J Pediatr Otorhinolaryngol* 52: 79-87.
2. Lin HW, O'Neill A, Cunningham MJ (2009) Ludwig's angina in the pediatric population. See comment in PubMed Commons below *Clin Pediatr (Phila)* 48: 583-587.
3. Megran DW, Scheifele DW, Chow AW (1984) Odontogenic infections. See comment in PubMed Commons below *Pediatr Infect Dis* 3: 257-265.
4. Kurien M, Mathew J, Job A, Zachariah N (1997) Ludwig's angina. See comment in PubMed Commons below *Clin Otolaryngol Allied Sci* 22: 263-265.
5. Pourdanesh F, Dehghani N, Azarsina M, Malekhosein Z4 (2013) Pattern of odontogenic infections at a tertiary hospital in tehran, iran: a 10-year retrospective study of 310 patients. See comment in PubMed Commons below *J Dent (Tehran)* 10: 319-328.
6. Vigilante CE, Costello BJ, Quinn PD (2001) Life-threatening cervicofacial infection in a child with hyperimmunoglobulin-E syndrome. See comment in PubMed Commons below *J Oral Maxillofac Surg* 59: 561-565.
7. Lin HW, O'Neill A, Rahbar R, Skinner ML (2009) Ludwig's angina following frenuloplasty in an adolescent. See comment in PubMed Commons below *Int J Pediatr Otorhinolaryngol* 73: 1313-1315.
8. Patamasucon P, Siegel JD, McCracken GH Jr (1981) Streptococcal submandibular cellulitis in young infants. See comment in PubMed Commons below *Pediatrics* 67: 378-380.
9. Tasca RA, Myatt HM, Beckenham EJ (1999) Lymphangioma of the tongue presenting as Ludwig's angina. See comment in PubMed Commons below *Int J Pediatr Otorhinolaryngol* 51: 201-205.
10. Hartmann RW Jr (1999) Ludwig's angina in children. See comment in PubMed Commons below *Am Fam Physician* 60: 109-112.
11. Sýkora J, Varvarovská J, Stozický F, Vondráková R, Svecová M, et al. (2004) Adolescent herpes simplex viral infection related Ludwig's angina in ulcerative colitis. See comment in PubMed Commons below *J Pediatr Gastroenterol Nutr* 38: 221-223.
12. Chen CJ, Huang YC, Lin TY (2004) Ludwig's angina following herpetic gingivostomatitis in a toddler with tetralogy of Fallot. See comment in PubMed Commons below *J Formos Med Assoc* 103: 311-313.
13. Bengtsson Y, Moullem R (2005) A swollen neck. See comment in PubMed Commons below *Clin Pediatr (Phila)* 44: 271-274.
14. Barkin RM, Bonis SL, Elghammer RM, Todd JK (1975) Ludwig angina in children. See comment in PubMed Commons below *J Pediatr* 87: 563-565.
15. Patterson HC, Kelly JH, Strome M (1982) Ludwig's angina: an update. See comment in PubMed Commons below *Laryngoscope* 92: 370-378.
16. Shaw KN, Marshall GS, Tom LW, Kovacs SJ (1988) Ludwig's angina caused by *Haemophilus influenzae* type b. See comment in PubMed Commons below *Pediatr Infect Dis J* 7: 203-205.
17. Wang LF, Kuo WR, Tsai SM, Huang KJ (2003) Characterizations of life-threatening deep cervical space infections: a review of one hundred ninety-six cases. See comment in PubMed Commons below *Am J Otolaryngol* 24: 111-117.
18. Moreland LW, Corey J, McKenzie R (1988) Ludwig's angina. Report of a case and review of the literature. See comment in PubMed Commons below *Arch Intern Med* 148: 461-466.
19. Gross SJ, Nieburg PI (1977) Ludwig angina in childhood. See comment in PubMed Commons below *Am J Dis Child* 131: 291-292.
20. Klein JO (1997) Role of nontypeable *Haemophilus influenzae* in pediatric respiratory tract infections. *Pediatric Infectious disease Journal* 16: S5-8.
21. Marple BF (1999) Ludwig angina: a review of current airway management. See comment in PubMed Commons below *Arch Otolaryngol Head Neck Surg* 125: 596-599.
22. Iwu CO (1990) Ludwig's angina: report of seven cases and review of current concepts in management. See comment in PubMed Commons below *Br J Oral Maxillofac Surg* 28: 189-193.
23. Wolfe MM, Davis JW, Parks SN (2011) Is surgical airway necessary for airway management in deep neck infections and Ludwig angina? See comment in PubMed Commons below *J Crit Care* 26: 11-14.