

Left Valsalva Sinus Aneurysm on Infection Tuberculous

Ibrahima Sory 2 Sylla^{*}, Simon Antoine Sarr, Fatou Aw, Malick Bodian, Youssou Diouf, Aliou Alassane Ngaidé, Momar Dioum, Serigne Mor Beye, Cheikh Tidiane Ndao, Mouhamadou Bamba Ndiaye, Adama Kane, Maboury Dia, Abdoul Kane and Serigne Abdou Ba

Aristede Le Dantec Teaching Hospital, Dakar, Senegal

^{*}Corresponding authors: Ibrahima Sory 2 Sylla, Aristede Le Dantec Teaching Hospital, Dakar, Senegal, Tel: +221771657966; E-mail: ibsosyl@yahoo.fr

Received date: May 26, 2017; Accepted date: June 30, 2017; Published date: July 05, 2017

Copyright: © 2017 Sylla IS2, et al. This is an open-access article distributed under the terms of the Creative Commons Attribution License, which permits unrestricted use, distribution, and reproduction in any medium, provided the original author and source are credited.

Keywords: Sinus of valsalva aneurysm; Tuberculous; Infection

Introduction

Sinus of Valsalva Aneurysm (SVA) is a localized dilatation of the aortic wall, forming a sacral ectasia, located just above the aortic cusps between the valve and the sino-tubular junction [1-3]. It is a rare condition that is congenital or acquired and whose frequency is less than 1% according to the literature [1]. The aneurysm most often involves the right coronary sinus (65-85% of cases), more rarely the posterior sinus (10-30%) and exceptionally the left coronary sinus (<5%) [4]. We report a case of an unruptured left SVA in an 18-year-old patient in a context of disseminated tuberculosis associated with rheumatic valvulopathy.

Case Report

Mr I.C., aged 18, was referred to our department for the management of a biventricular cardiac failure. He had a history of multiple abscesses on the neck, left ear and cheek treated with non-specific antibiotic therapy (Figure 1). He had a 45-day history of dyspnea on exertion of progressive aggravation leading to dyspnea at the slightest effort and orthopnea, associated with palpitations and edema of the lower limbs. There was no syncope or chest pain, or history of tuberculosis or chest trauma. On examination, he had a satisfactory general condition, a blood pressure (BP) of 140/80 mmHg, a heart rate (HR) of 110 beats/min, a respiratory rate (RR) of 28 cycles/min, a temperature of 36.8°C, a weight of 59 kg for a height of 1.60 m, and a BMI=23.04 kg/m². There were signs of biventricular heart failure, right-sided pleural effusion, mitral and aortic regurgitation. Elsewhere, we noted the presence of pityriasis in the cervical and thoracic region, small, painless, mobile bilateral axillary lymphadenopathies predominant on the right.

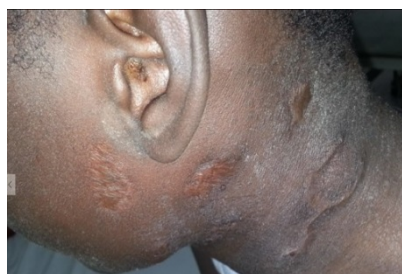

Figure 1: Abscess scar.

Laboratory examination showed microcytic hypochromic anemia at 10.2 g/l. Renal and liver function tests, Addis count and

antistreptolysin O titers were all normal. Syphilis and retroviral serologic tests as well as cytobacteriology of pleural fluid were negative. Analysis of the ascites fluid revealed an exudate; examination of fine needle aspirates from lymph nodes was compatible with tuberculosis.

The electrocardiogram inscribed a regular sinus tachycardia at 107 cycles/min, right and left atrial enlargement, bi-ventricular hypertrophy, incomplete right bundle branch block with secondary repolarization abnormality.

The AP chest x-ray showed a cardiomegaly with a cardiothoracic index of 0.66, dilatation of the pulmonary artery and a right pleural fluid effusion.

Transthoracic echocardiography concluded with an anterior and lateral positional structure with respect to the left ventricle, forming a part of it, measuring 48 mm × 29 mm. There was moderate aortic and mitral insufficiency associated with a rheumatic valvular involvement with good function of both ventricles (Figure 2).

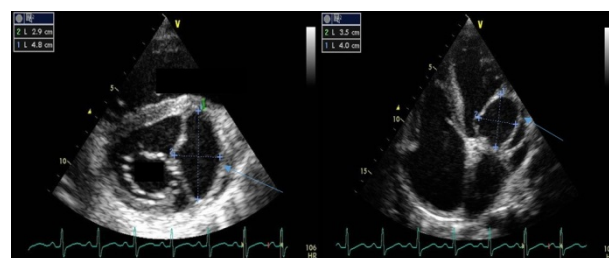


Figure 2: Images of 2D transthoracic echocardiography showing the aneurysm.

Thoracic CT with and without injection of contrast revealed saccular dilatation of the thoracic aorta at its origin above the left coronary cusp (Figure 3). It measured 45 × 36 mm on the axial plane with a collar of 13.7 mm. There was no anomaly of the coronary arteries. This cavity caused a moderate compression of the left ventricular outflow tract (LVOT). It was associated with dilatation of the right atrium, pulmonary artery trunk, hepatic veins and the right medial and hilar adenopathies.

Mr I. C was given treatment for heart as well as for tuberculosis and a good clinical improvement was observed. The evolution was marked by his sudden death whilst waiting for surgical treatment.

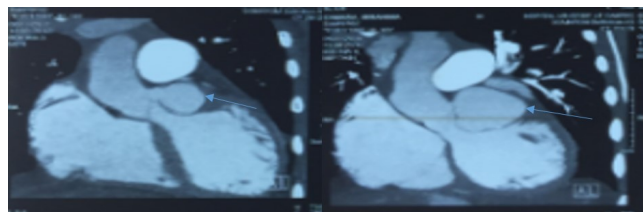


Figure 3: Thoracic scan showing the aneurysm and its collar.

Discussion

SVA is a rare condition that was first reported by Thurnam in 1840 [1,5]. Besides the congenital forms, there are those acquired in relation to atherosclerosis, media-necrosis, syphilis, endocarditis, trauma but also tuberculosis [6]. The latter is the hypothesis made in our patient given the context of multifocal tuberculosis. Structural weakness at the intersection of the media and the fibrous ring appears to contribute to the formation of the aneurysm. The anatomical forms are divided into four groups according to the origin of the aneurysm: in type I, the aneurysm originates in the anterior third of the right coronary sinus, in type II, in its middle third and in type III, in its posterior third. Type IV involves the anterior third of the posterior sinus (25%) [7]. The left coronary sinus is very rarely involved. The published series show predominance in the right anterior sinus [1,3,5]. The unruptured aneurysm is asymptomatic in the absence of aortic regurgitation. Left sinus aneurysms with rupture are rarely observed, and when this is the case, rupture occurs into the left atrium or ventricle or in the pericardial space. This is why they do not cause any left-right shunt [8]. Echocardiography significantly helps in its diagnosis. Several papers emphasize the use of other imaging modalities for the diagnosis of this condition; echocardiography would contribute in 90% of cases [9]. In this case, the chest CT scan allowed visualization of the collar, its position in relation to the coronary arteries and the existence of other associated abnormalities. The absence of dilatation of the other sinuses and of the aorta as a whole would rule out the possibility of a connective tissue disease.

In addition to echocardiography and CT scan, magnetic resonance imaging contributes to the diagnosis by providing clarification of the state of the aortic valve.

Surgery is the mainstay of its management. It consists of resection and closure of the sinus, and using a patch if necessary. In some cases, a bilateral approach is indicated [8]. Surgical repair should be performed as soon as the diagnosis is made to prevent complications such as sudden death by rupture. The results are usually good and recurrence very rare.

Conclusion

Sinus of Valsalva Aneurysm may be of tuberculous origin. Doppler echocardiography and computed tomography are essential diagnostic inputs. Urgent surgical intervention is required given the risk of sudden death due to rupture.

References

1. Antonio Lijoi A, Parodi E, Passerone GC (2002) Unruptured Aneurysm of the Left Sinus of Valsalva Causing Coronary Insufficiency. *Tex Heart Inst J* 29: 40-44.
2. Ott DA (2006) Aneurysm of the Sinus of Valsalva. *Semin Thorac Cardiovasc Surg Pediatr Card Surg Annu* 9: 165-176.
3. Ring WS (2000) Congenital heart surgery nomenclature and database project: aortic aneurysm, sinus of Valsalva aneurysm, and aortic dissection. *Ann Thorac Surg* 69: 147-163.
4. Aboukhouir F, Rekik S, Hirsch J L (2014) Important anévrysme du sinus gauche de Valsalva chez un patient de 54 ans traité chirurgicalement. *Ann Cardiol Angéiol* 63: 376-380.
5. Vural KM, Sener E, Tasdemir O (2001) Approach to sinus of Valsalva aneurysms: a review of 53 cases. *Eur J Cardiothorac Surg* 20: 71-76.
6. Moustafa S, Mookadam F, Cooper L (2007) Sinus of Valsalva aneurysms 47 years of a single center experience and systematic overview of published reports. *Am J Cardiol* 99: 1159-1164.
7. Noureddine M, Raquim S, Elhattaoui M (2001) Anévrysme du sinus de Valsalva postérieur rompu dans l'oreillette droite. *Ann Cardiol Angéiol* 50: 211-216.
8. Weijerse A, van der Schoot MJ, Maat LP (2008) Cardiac tamponade due to ruptured aneurysm of the sinus of Valsalva. *J Card Surg* 23: 256-258.
9. Terdjman M, Bourdarias JP, Farcot JC (1984) Aneurysms of sinus of Valsalva: two-dimensional echocardiographic diagnosis and recognition of rupture into the right heart cavities. *J Am Coll Cardiol* 3: 1227-1235.