

Large Cavernous Hemangioma of the Kidney Mimicking a Renal Cancer: A Diagnostic Challenge

Chafiki J*, Hajji F, Janane A, Ghadouane M, Ameer A and Abbar M

Department of Urology and Transplantation, University Military Hospital, Rabat, Morocco

*Corresponding author: Chafiki Jaouad, Urology and Transplantation, University Military Hospital, Hay Ryad Street, Po Box 1018, Rabat, Morocco, Tel: 00212661329022; E-mail: drjaouad@yahoo.fr

Rec date: Jul 04, 2014; Acc date: Oct 30, 2014; Pub date: Nov 01, 2014

Copyright: © 2014 Chafiki J, et al. This is an open-access article distributed under the terms of the Creative Commons Attribution License, which permits unrestricted use, distribution, and reproduction in any medium, provided the original author and source are credited.

Abstract

Cavernous hemangioma of the kidney is an uncommon benign vascular tumor that is rarely diagnosed preoperatively. We report a case of a large renal cavernous hemangioma presenting as a renal cancer.

Keywords: Cavernous hemangioma; Kidney; Vascular tumor

Introduction

Cavernous hemangioma of the kidney is an uncommon benign vascular tumor that is rarely diagnosed preoperatively. About 200 cases have been reported in the literature since Virchow first described it in 1867 [1]. We report a case of a large renal cavernous hemangioma presenting as a renal cancer and the diagnostic challenge he presented.

Case Report

A 69-year-old man presented with a 9-months intermittent macroscopic painless hematuria. He had a previous left kidney surgery for renal lithiasis 24 years ago. There were no particular physical findings, such as flank pain.

Routine laboratory tests including hematology, biochemistry, urine analysis and coagulation tests showed no abnormalities. Urine cytology studies and cultures were negative.

Renal ultrasound depicted an enlarged left kidney with heterogeneous solid mass. An enhanced computed tomography (CT) revealed a 10 × 9 × 8, 5 cm, low-density, large heterogeneous renal mass. The lesion was slightly enhanced after contrast injection and caused pelvicalyceal system deformities; suspicious of renal cell carcinoma cT2N0M0 (Figure 1).

According to the medical history, a possibility of pseudo tumoral xanthogranulomatous pyelonephritis was considered. A left open radical nephrectomy was performed.

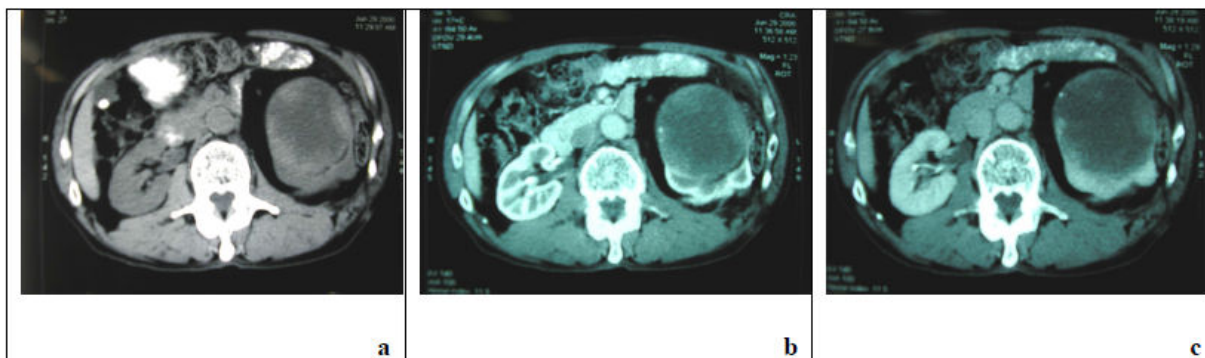


Figure 1a-c: Computed tomography (CT) of the present patient. (a) A heterogeneous low density masse in the left kidney. (b) In the arterial phase, the wall of the masse and peripheral solid component were slightly enhanced. (c) In the late phase, the contrast medium in the wall and peripheral component of the mass was not washed out.

Gross pathologic examination revealed a 9,5× 8,3×11 cm mass that had replaced most of the middle and lower poles, with involvement of the renal hilum but no abnormalities on renal vessels. Histopathological findings revealed a large cavernous haemangioma of the left kidney with extensive intratumoral haemorrhage and necrotic part (Figure 2).

Patient follow-up was favorable since August 2010. Radiological control by abdominal and thoracic computed tomography every 06 months has not objectified evidence of local or distant recurrences.

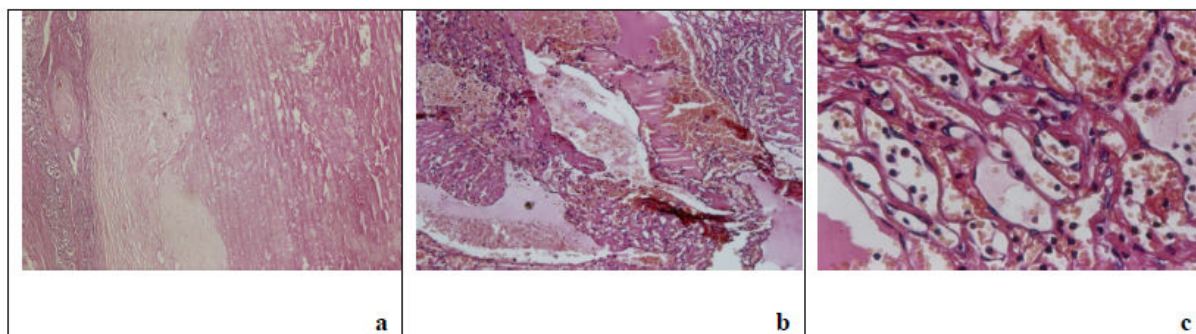


Figure 2a-c: Hematoxylen-Eosine staining. (a) Vascular proliferation (right) lined by a fibrous capsule in renal parenchyma (left) (x 40). (b) Cavernous structures filled with erythrocytes (x100). (c) Central vascular networks lined by endothelial cells without cellular atypia or mitosis (x400).

Discussion

Hemangiomas are benign vascular tumors that probably arise from embryonic rest of unipotent angioblastic cells [2]. A distinction is usually made between the capillary and cavernous forms. Hemangiomas of the urinary tract are generally considered to be an isolated disease, but may be associated with tuberous sclerosis, Sturge-Weber syndrome, and Klippel-Trenaunay-Weber syndrome. The kidney is the most commonly affected organ of the urinary tract. Although a renal hemangioma may be found in any part of the kidney, the most frequent location is the tip of the papilla. The submucosal region, papilla, and medulla account for 90% of all anatomical locations, and the renal parenchyma and capsule account for the rest [3]. Most renal hemangiomas are unilateral and have no sex or laterality predilection [3] and tend to be small (1 and 2 cm in diameter). In our case, an extremely large renal cavernous hemangioma replaced the most of the kidney was identified.

The clinical symptoms of this disease range from none to gross hematuria and sometimes colic due to the passage of blood clots [2]. On physical examination, a flank mass can be palpable and may even be occasionally associated with flank tenderness.

The radiological features of this tumor are not well described. The sonographic findings are non-specific. They have been reported as hyperechoic tumor [4] or hypoechoic tumor with normal renal vascular pattern rather than a pattern specific to hemangioma in Power doppler sonography [5]. This findings may mimic more common tumors of the kidney, including renal cell carcinoma and transitional cell carcinoma. There are few descriptions of the CT findings of renal hemangioma. The tumor may enhance on injection of intravenous contrast material, but are not usually encapsulated [4].

In our case, however, the lesion was not significantly enhanced. The reason for this is not clear, but it might be due to extensive intratumoral hemorrhaging and necrotic part of the mass. Magnetic resonance imaging results were reported for a small number of cavernous hemangioma cases.

Descriptions of renal cavernous hemangiomas on Selective renal angiography, recommended by many investigators as the best diagnostic method to detect renal hemangioma, have included a normal appearance [6], a hypervascular mass producing varying

degrees of caliceal deformity, and a hypervascular mass with rapid arteriovenous shunting [7].

On pathologic examination, the gross specimen is typically described as dark brown and friable with clotted blood in the vasculature. Histologically, the tumors have a dense network of thick-walled vessels lined with typical endothelial cells, and sometimes the tumors have hemorrhages [2,8,10].

Renal cavernous hemangioma is seldom diagnosed preoperatively, and it is therefore impossible to recommend a specific treatment. Therapeutic measures for renal cavernous hemangioma range from no therapy to total nephrectomy. Management includes observation, total nephrectomy, partial nephrectomy, papillectomy, selective renal embolization, ureterorenoscopic coagulation and sometime radiation therapy [2,9].

In our patient, because the nature of the tumor could not be well established and owing to the size of the tumor mass, left nephrectomy surgical exploration was performed. CT and urine tests have indicated that no recurrence have developed during the follow-up.

Conclusion

The definitive preoperative diagnosis of cavernous hemangioma remains difficult because this tumor produce no particular clinical symptoms, blood or urine findings, or images on radiological studies, including sonography, CT, and MRI. We recommend that all suspicious renal masses should be treated as suspected malignancies and should be excised with either partial or total nephrectomy, with the extent of surgery being determined by the size and location of the kidney mass.

References

1. Daneshmand S, Huffman JL (2002) Endoscopic management of renal hemangioma. *J Urol* 167: 488-489.
2. Jahn H, Nissen HM (1991) Haemangioma of the urinary tract: review of the literature. *Br J Urol* 68: 113-117.
3. Lee HS, Koh BH, Kim JW, Kim YS, Rhim HC, et al. (2000) Radiologic findings of renal hemangioma: report of three cases. *Korean J Radiol* 1: 60-63.
4. Numan F, Berkmen T, Korman U, Ogüt G, Cokyüksel O (1993) Cavernous hemangioma of the kidney. Case report. *Clin Imaging* 17: 106-108.

-
5. Geenen RW, Den Bakker MA, Bangma CH, Hussain SM, Krestin GP (2004) Sonography, CT, and MRI of giant cavernous hemangioma of the kidney: correlation with pathologic findings. *AJR Am J Roentgenol* 182: 411-414.
 6. Zhao X, Zhang J, Zhong Z, Koh CJ, Xie HW, et al. (2009) Large renal cavernous hemangioma with renal vein thrombosis: case report and review of literature. *Urology* 73: 443.
 7. Brown JG, Folpe AL, Rao P, Lazar AJ, Paner GP, et al. (2010) Primary vascular tumors and tumor-like lesions of the kidney: a clinicopathologic analysis of 25 cases. *Am J Surg Pathol* 34: 942-949.
 8. Chen T, Jin P, Wang Y, Zhao X, Yang L (2011) Renal cavernous hemangioma in a child: case report and review of the literature. *Urology* 78: 1185-1186.
 9. Gutierrez-Banos J, Portillo J, Campos F, Rodrigo E, Ruiz J, et al. (2012) Giant cavernous hemangioma in renal graft: a case report. *Transplant Proc* 44: 1453-1456.
 10. Montgomery E, Epstein JI (2009) Anastomosing hemangioma of the genitourinary tract: a lesion mimicking angiosarcoma. *Am J Surg Pathol* 33: 1364-1369.